IV. *The Brain of* Ornithorhynchus Anatinus.

By Marion Hines, *Ph.D.* (*Department of Anatomy, Johns Hopkins University, Baltimore*).

(Communicated by J. T. Wilson, F.R.S.—Received August 25, 1927.—Read February 2, 1928.)

(Plates 41—83.)

CONTENTS.

Page
Introduction—Material 155
Description—
  Medulla oblongata 157
  Cerebellum 166
  Midbrain 171
  Thalamus 182
  Corpus Striatum 196
  Telencephalon 205
Discussion—
  Medulla 215
  Cerebellum 225
  Midbrain 230
  Thalamus 236
  Corpus Striatum 245
  Telencephalon 251
Bibliography 260
Abbreviations in figures 271
Description of figures 280

In the study of a few specimens of the brains of Monotremes and Marsupials, it was discovered that in spite of the published work upon the brain of Ornithorhynchus by such *savants* as Koelliker (1901), Ziehen (1908), and Elliot Smith (1898–1900), knowledge of the brain stem of this interesting mammal was incomplete, as judged by present-day standards. It was felt that with the introduction of more recent viewpoints, a new study of this subject might chance to give the old facts new relationships. This monograph, as one of the rapidly increasing number of analyses of the brains of vertebrates, may help to clarify in part the inter-relationships between the brains of lower forms and those of mammals.

[Published January 5, 1929.

This research, begun at the suggestion of Prof. ELLIOT SMITH, in London, was continued at the University of Chicago, upon material which he most generously loaned the author, and was brought to a conclusion in Cambridge with the use of three series of brains in the collection of Prof. J. T. WILSON.*

It is a pleasure to thank both Prof. WILSON and Prof. ELLIOT SMITH, not only for the use of this unique material, but also for their kindly criticism and suggestion throughout. In Chicago, Prof. HERRICK's interest and encouragement has been a great stimulus to the further progress of the investigation. I wish to thank Mr. PITTOCK, of University College, and Mr. TALBERT, of Johns Hopkins Medical School, for the beautiful photographs, and Mr. TODA, of Chicago, for the two wash-drawings of the model.

The material used in this research may be tabulated as follows :—

TABLE I.

Brain.	Collection.	Plane of Section.	Stain.	Thickness.
S. T.	ELLIOT SMITH	Transverse	Weigert	100 μ
S. S.	SIR VICTOR HORSLEY*	Sagittal	,,	about 100 μ
S. H.	ELLIOT SMITH	Horizontal	,,	100 μ
S. T. N.	,, ,,	Transverse	Nissl	10 μ
W. T.	J. T. WILSON*	,,	Weigert	about 200 μ
W. S.	,, *	Sagittal	,,	,, ,,
W. T. B.	,,	Transverse	Bielschowsky	16 μ
W. Z.	D. M. S. WATSON	—	—	—
W. Z. T.	,, ,,	Transverse part of medulla only	Bielschowsky	12 μ

* This series came into the possession of Prof. WILLIAM WRIGHT, Dean of the London Hospital Medical College, and he generously presented it to Prof. ELLIOT SMITH.

The first brain in this series (S. T.) was modelled in wax at a magnification of ten diameters. At its anterior end, a few sections were missing. In that region it cannot be accurate. However, such a loss in no way disturbs the general morphology of inter-relationships between the thalamus and corpus striatum, for example. The modelled brain stem, including only the cephalic portion of the medulla oblongata, the midbrain and thalamus, was dissected in one piece ; the corpus striatum, as another. The line of division between septum† and head of the caudate nucleus attempted to

---

* The Pal-Weigert series of sections had been generously placed at the disposal of Prof. WILSON by the New South Wales Government Lunacy Department Laboratory, in the Medical School of the University of Sydney.

† In employing throughout this paper the term "septum" as a designation for the telencephalic medial wall, rostral to the bed of the anterior commissure and ventral to the hippocampal formation, the writer is following the now prevalent usage, at least of the American school of comparative neurologists.

In its use as a substitute for ELLIOT SMITH's prior designation of "corpus paraterminale" the term include the nucleus accumbens, and may therefore be rather arbitrary. These dissections left the pallium and the septum as an outer crust. In this way the external morphology of the thalamus and striatum was determined.

DESCRIPTION.

I. *The Medulla oblongata.*

(Plates 41 to 54 ; figs. 2 to 10, 12 to 19, 33, *a* to *c* ; 44, 71 to 74 ; and 78.)

The medulla oblongata of *Ornithorhynchus anatinus* is much flattened in its dorso-ventral diameter (figs. 12 to 19, and 44), a phenomenon which only the adult shows, because it is concomitant with the over-development of the reticular systems. The two large medial ridges lying in the floor of the fourth ventricle do not cover the somatic motor column, as is the case in many other vertebrates and in the fœtus of this beast itself, but rather the large central tegmental systems. Lateral to these ridges the nuclei of the hypoglossal nerve lie (*nuc.xii*, figs. 12 and 78). Immediately lateral to this ridge and extending a few millimetres cephalward another elevation appears, the dorsal motor nucleus of the vagus (*nuc.d.x*, figs. 12 and 78). Lateral to this nucleus lies the area acustica (figs. 13 to 16 and 78) as a triangle, the apex of which is partly hidden by the cerebellar peduncles. No stria medullaris acustica passes over it, for that structure is buried in the brain substance far beneath the superficial nuclei. The nuclei gracilis and cuneatus (*nuc.gr.* and *nuc.cun.*, figs. 12 to 14 and 78) make no great bulging on the dorsal surface, as in man and other mammals, but rather lie dorsal to the great nucleus sensibilis of the fifth (*nuc.s.v*, figs. 12 to 21, 46B and 78), forming a small ridge visible upon the lateral surface of medulla. This is another illustration of the developmental flattening of that part of the brain stem. Upon the ventro-lateral surface the huge elongated elevation is made by the enormous sensory nucleus of the trigeminus. Midway between these nuclei, at the level of the tenth and twelfth nerves, are two minute ridges, the inferior olives (*o.i.*, figs. 12 to 15). More cephalward, in the region of the motor trigeminal nucleus, the pons (*p.*, figs. 19 to 21 and 46B) encircles the greatest elevation of the trigeminal sensory nucleus, turns into the midline and decussates. Below this decussation, the nuclei pontis lie (*nuc.p.*, figs. 19 and 21).

Of the three peduncles connecting the medulla with the cerebellum, the corpus restiforme (*c.r.*, figs. 13 to 15) is by far the largest, and therefore most important in

septum is not now to be taken as involving any direct reference to the structure known as the septum pellucidum in the human brain.

The structure in question was originally named (or included in) the " area præcommissuralis " by ELLIOT SMITH in 1896, and was later (1897) specifically named by him " corpus præcommissurale." In 1899 he modified this designation to " corpus paracommissurale," and, finally (1903), substituted for it the term " corpus paraterminale," which may therefore be taken as carrying the weight of his authority. To the same region JOHNSTON subsequently applied the term " parolfactory area."

connecting the cerebellum with lower centres of medulla and spinal cord. It lies relatively more caudal than the others. The brachium conjunctivum, or superior peduncle (*br.c.*, figs. 18 and 19) is of about the same calibre as the brachium pontis and lies deep in the substance of the midbrain, except when it abruptly rises to the lateral surface in the level of the anterior medullary velum, so that it enters the cerebellum medial and rostral to the middle peduncle, and very far rostral to the inferior.

There is no colliculus facialis nor eminentia medialis in the floor of the fourth ventricle. The two medial eminences are continued into the anterior part of the medulla, where they cease to cover a tegmental system and lie over a hypertrophied central gray matter.

The Functional Systems of the Medulla Oblongata.

The trigeminus.—The sensory nucleus of the nervus trigeminus (*nuc.s.v.*, figs. 5 and 6, 12 to 16, and 72 to 74 and 78) lies as a half-moon, medial to the arc formed on the latero-ventral surface of the medulla by the spinal fifth tract. In the caudal region of this nucleus no differentiation is visible. However, beginning at the level of the seventh and eighth nerve roots (fig. 16), a difference between the lateral and the medial regions appears ; the cells of the medial division are larger (fig. 74) than those of the lateral. In the next figure (fig. 17) the medial division is greater than the lateral in its dorso-ventral and medio-lateral measurements, and remains so throughout its extent (figs. 18 to 21 and 78). The axones of these nuclei which form the lemnicus system (*lem.t.*, fig. 7) appear to remain in small fascicles medial to, and yet more or less dispersed among, the cells of the nucleus itself. The main body of the decussation of this system (*dec.l.t.*, figs. 18 and 19) is found at the level of the motor fifth nucleus, although a few scattered fibres may be identified, crossing the raphé caudal to this region (*i.e.*, of the motor seventh). The route of their departure from the nucleus and their partial passage rostrally may be seen most clearly in fig. 5 (*lem.t.*). The lemniscus lies as a bundle of fibres antero-ventral to the motor nucleus of the fifth in the next level figured (*n.m.v.*, fig. 6). It lies among the fibres of the basis pedunculi and may be followed anteriorly, dorsal to them. In the more caudal region of the thalamus they swing in a curve lateralward and ventralward, ending in what appears to be the ventro-posterior division of the nucleus medialis thalami.

The Vestibular Division of the Nervus acusticus (figs. 6 and 7, 13 to 16, 78 and 79).—In Ornithorhynchus, as elsewhere among mammals, four nuclei can be identified into which the vestibular branch of the eighth nerve discharges. The criterion for their identification is based upon their relationships to each other and to the tract system made by root fibres of the nerve itself. The axones of the ganglion vestibulare enter and appear to split into ascending and descending branches. The descending branches lie among the cells of the spinal nucleus (*nuc.v.sp.*, figs. 13 and 14, also fig. 8). Dorsal to it lies the broad shallow medial nucleus (*nuc.v.m.*, also fig. 7) bounded laterally by the corpus restiforme and medially by either the nucleus dorsalis of the vagus (*nuc.d.x.*, fig. 13) or by the fasciculus longitudinalis medialis (see *f.l.m.*, fig. 14). Beginning in this level the great lateral nucleus of DEITERS (*nuc.v.l.*, fig. 15) may be seen, although its large motor-like cells are better distinguished in fig. 16. The nucleus vestibularis superior is not so easily identified. Caudally, this nucleus is contiguous and dorsal to the lateral nucleus (*nuc.v.d.*, figs. 15 and 9). In the sagittal series the antero-posterior length of these various nuclei may be partially distinguished. The medial nucleus is a long band of cells on the dorsal surface of the medulla (*nuc.v.m.*, fig. 7). The spinal nucleus (*nuc.v.sp.*) is seen in fig. 8 lying caudal and ventral to the nucleus vestibularis lateralis. Dorsal to the spinal nucleus, fibres entering the cerebellum without synapse are visible—the tractus vestibulo-cerebellaris (*tr.v.c.*, fig. 8). In fig. 9 dorso-cephalward to DEITERS' nucleus is the superior nucleus of the nerve (*nuc.v.d.*). From the former nucleus fibres can be traced into the nucleus medialis of the cerebellum.

The *Cochlear Division of the auditory Nerve* (figs. 2, 3, 7 ; 15 to 21 and 32, *a* to *c*).—At the level of the entrance of the root of the eighth nerve (*r.viii*, fig. 15) a small group of cells are seen to lie ventro-lateral to DEITERS' nucleus, the nucleus cochlearis dorsalis (*nuc.c.d.*). In fig. 16 both this nucleus and a smaller one lying in the path of the auditory radix are clearly visible, the nucleus cochlearis ventralis (*nuc.c.v.*). At this same level, dorso-medial to the nucleus sensibilis trigemini, is an obscure group of two or more nuclei, which the author has identified as portions of the superior olive (*s.o.*, also figs. 5 and 32, *a* to *c*). In fig. 17 fibres are seen swinging ventro-medially, as it were, from the dorso-lateral border of the sensory nucleus of the fifth. They are in all probability a part of the fascicles which cross the midline as the corpus trapezoideum (*c.tr.*), and send collaterals to end in or pass by the superior olive, thus forming a part of the lateral lemniscus. Between figs. 16 and 17, it is possible by studying the fibre paths with the utmost care to trace a tract which seems to originate in the cochlear nuclei, to pass dorso-medially with the fibres of the root of the seventh motor nucleus (*r.vii*, fig. 16) ; then, medial to the dorsal nucleus of the facial nerve, this tract plunges abruptly ventralward to the underlying superior olive, lying both medial and lateral to nucleus ventralis of the seventh (figs. 32, *a* to *c*).

In fig. 32 *a* the smallest cells of what is probably the superior olive lie embedded in a fine matrix. Fibres run into it from above. The size of its cells holds the same relation to those of the motor seventh nucleus in Platypus as in other mammals. The large slantingly placed nucleus, which the writer has marked the superior olive of KOELLIKER (*s.o.K.*), probably belongs to the superior olive group, although there is but little indication that the fibres of the stria medullaris acustica enter it. Probably only those which form a part of the decussation of the lateral lemniscus, the corpus trapezoideum, pass through it. Certainly the ventral part of the lateral lemniscus system is closely connected with the ventral nucleus of the seventh. This is well demonstrated in Prof. WILSON's transverse Weigert series. Although some of these fibres appear to fray out within that nucleus, others of these undoubtedly pass through. This apparent division of the superior olive into two parts, each having apparently different connections with the lateral lemniscus, would be, if proven true, a very suggestive fact for the phylogenetic development of that body.

The lateral lemniscus (*lem.l.*, fig. 17) passes dorsal to or through the nucleus ventralis, or the seventh motor nucleus, as well as through the superior olive. It then turns dorso-laterally in a curve convex to the brain wall, and swings dorsalward to the mid-brain. It lies immediately beneath the outer limiting membrane of the lateral surface of the medulla, ventral to the posterior projection of the inferior colliculus, and therefore lateral to the brachium conjunctivum (*br.c.*, fig. 17). It may be seen more easily in the next figure, where it sends fibres into the colliculus inferior (*c.i.*, figs. 18 and 19). Following a few of the more lateroventral fibres of this bundle they are seen to turn lateralward at a sharp angle, ventral to the pes pedunculi, and in the medial geniculate body (*m.g.b.*, figs. 20 and 21). To determine whether or not all of these fibres have their origin or their termination in the colliculus inferior needs other techniques than those available. The lateral lemniscus itself is partially interrupted in its pathway by a large nucleus—the nucleus of the lateral lemniscus (*nuc.l.l.*, fig. 19). This system does not vary in any of the important details from those of closely related mammals.

The nuclei of the funiculi gracilis and cuneatus together with the medial lemniscus (figs. 12 to 19, 21 and 78).—The nucleus gracilis (*nuc.gr.*, figs. 12 and 78) is a small nucleus lying dorsal to the nucleus cuneatus (*nuc.cun.*, figs. 12 to 14, and 78), medial to the external arcuate fibres (*e.a.f.*, fig. 12) and lateral to the nucleus of the fasciculus solitarius (*nuc.,f.s.*, fig. 12). As implied from the foregoing, the nucleus cuneatus is ventral and lateral to the nucleus gracilus and, as is found in other mammals, it extends further anteriorly than does the gracilis (see *nuc.cun.*, figs. 12 to 15). These nuclei give rise to the lemniscus medialis (*lem.m.*, figs. 13 to 15), the fibres of which run with the internal arcuate bundles (*i.a.f.*, figs. 13 and 14) cross beneath the inferior olive (*o.i.*, fig. 13) to be known as the decussation of the medial lemniscus (*d.l.m.*, fig. 13). This crossing passes ventro-lateral to the olive (*lem.m.*, figs. 14 and 15) to take up a position in the ventral part of the medulla, lateral to the raphé (figs. 16 and 17) and dorsal to the pyramidal system (*tr.c.sp.*, figs. 15, 16 and 17, and *tr.c.b.*, fig. 17). This bundle maintains this relative position as far cephalward as the level of the fifth motor nucleus (fig. 19). The fibres of the bundle turn at right angles dorsal to the basis pedunculi: they appear in Weigert material as an elliptical brilliant blue mass. As the bundle ascends more dorso-laterally, the ellipse gives place to the circle, from which the fibres spread out in the extreme caudal extremity of the ventro-lateral part of the pars dorsalis thalami, the nucleus ventro-lateralis thalami (fig. 22).

The nucleus and fasciculus solitarius.—The fasciculus solitarius (*f.s.*, figs. 12 to 14; 72 and 78) lies as a great bundle of medullated fibres in the midst of its nucleus (*nuc.f.s.*, figs. 12 to 14). It extends rostrally from a region commensurate with the caudal limit of the nucleus of the hypoglossal nerve to the level immediately posterior to the roots of the nervus acusticus. These limits are comparable to those found in man.

At its more caudal levels, *i.e.*, in the region of the middle of the hypoglossal nucleus (fig. 12), the major portion of the nucleus of the tractus solitarius lies as a half-moon dorsal, lateral and ventral to the tractus. The cells which make up this part of the nucleus are of two sizes, one slightly smaller than those of the nucleus intercalatus, the other very small. Those which are found lateral to the tractus are similar to the small size of the medial group. Further rostralward, in the same level with the anterior limit of the twelfth nucleus and the larger, expanded vagal nucleus, the cells are more concentrated and larger medial to the fasciculus. In the same level with the caudal part of the corpus restiforme, the major portion of the nucleus lies ventro-lateral to the fasciculus and dorso-lateral to the root of the tenth. The cells are rather smallish, similar in size to that division of the nucleus which in the more caudal levels is found lateral to the fasciculus.

Arbitrary division then of this nucleus might be made by the fasciculus, a dorso-medial, where the cells are both large and small, and a ventro-medial, in which they are small. The former is more accentuated posteriorly and the latter anteriorly. The writer was unable to identify any cells belonging to either of these divisions which might be called the nucleus of the commissure of Cajal.

The vagus complex.—Dorsal to the nucleus of the fasciculus solitarius and lateral to a group of cells, the nucleus intercalatus (*nuc. i.*, figs. 12, 13 ; *nuc.int.*, fig. 72), lies the complex nuclear mass of the vagus (*nuc.d.x.*, figs. 12, 13, 72, 73 and 78), which grows smaller slightly anterior to the ventral end of the nucleus of the twelfth nerve. Its ventro-caudal limit approximates that of the nucleus cuneatus. In its ventro-lateral part there is a differentiation into a separate nucleus, coextensive with the limits of the nucleus fasciculi solitari, which has been labelled the nucleus of the ninth nerve (*n.ix.*, figs. 13, 14, 72, 73 and 78). This particular group of cells KOELLIKER (1901) has called the motor nucleus of the nervous glossopharyngeus (*n.ix.*, figs. 1 and 2, pp. 6 and 8). He says that it not only sends fibres out via the root of the ninth but also by way of the tenth. This finding the writer has thought to have corroborated by a dissection of Platypus kindly lent by Prof. WATSON. In studying the medulla of an Echidna, belonging to Dr. ARIËNS KAPPERS, the same differentiation was found within the vagal complex. It was not so well separated from the small celled portion by a capsule of heavily medullated fibres as in Platypus. This group of cells may be the same as the large celled nucleus of the vagus, described by WINKLER.

The cells which form the small celled division of the vagus show so little differentiation in size, chromidial staining or arrangement that it is impossible to group them with any degree of assurance. Nevertheless, many cells are found dorso-lateral to the so-called nucleus of the ninth which lie in the relative position of the dorsal sensory nucleus of the tenth ; this sensory nucleus is central to the fovea inferior and lateral and a little dorsal to the dorsal motor nucleus of the tenth.

At the anterior part of the tenth nucleus a slender, thin band of small cells passes dorsal to the nucleus hypoglossi and medio-dorsal to the lateral division of the dorsal tegmental bundle of SCHÜTZ. These cells are probably similar to those of WINKLER's nucleus teres.

Ventral to the nucleus teres, lateral to the nucleus hypoglossi and medial of the dorsal motor nucleus of the vagus, there is a wedge-shaped nucleus of small cells, the nucleus intercalatus Staderini (*nuc.i.*, figs. 12, 13; *nuc.int.*, fig. 72). The dorsal tegmental bundle forms its lateral border. It is found anterior to the ventral limit of the hypoglossus nucleus. In the Nissl or the Bielschowsky series its lateral limits are a little difficult to place, for its cells resemble those of the small celled part of the vagus. However, in the Weigert series they are found to lie among the finely medullated network just lateral to the heavier one of the hypoglossal nucleus (fig. 12).

The nucleus ambiguus (*nuc.a.*, figs. 72 and 73) cannot be identified with certainty in any level except those in the extreme caudal limit of the nucleus vagus. Here it appears as a small group of four or five motor-like cells, difficult to distinguish from the giants of the reticular apparatus, lateral to the radices of the nucleus hypoglossus, dorso-medial to the nucleus sensibilis of the trigeminus and dorsal to the most lateral wing of the inferior olive. If this nucleus be followed rostrally, it appears to disappear as the dorsal motor nucleus of the vagus becomes more prominent. If this observation be true, then the nucleus ambiguus of Platypus is but an insignificant structure compared with those of other mammals. Its caudal limit is reached before that of the hypoglossal nucleus, and its rostral at about the rostral limit of the nucleus intercalatus Staderini.

The nucleus hypoglossus (*nuc.xii*, figs. 12, 72, 73 and 78) lies as a circular group of very large cells lateral to the dorso-medial tegmental bundles. In size its cells are eclipsed by no cell in the medulla except those of the formatio reticularis, and yet they are small compared with the cells of the hypoglossal nucleus of man. The total extent of the nucleus in Platypus measures about 2·5 mm. Among the large cells of the nucleus there are a few small ones, but these small elements are so scattered throughout the whole of the nucleus that they do not form a nuclear unity in any sense of the term. In the middle part of the rostro-caudal extent of the nucleus, at its middle ventral border, is a group of five or six smallish cells. This cell-group is not circumscribed by small medullated fibres as ROLLER's nucleus is in man, nor is its relative position similar. And yet it is the only group of small cells in or near the hypoglossal nucleus which in any way resembles ROLLER's nucleus.

Many of the fibres from the tegmental bundles, as well as the fasciculus longitudinal medialis, penetrate the twelfth nucleus. Running near the dorsal surface of these tegmental bundles is a commissure which appears to connect the two nuclei.

The nucleus of the sixth cranial nerve (*nuc.vi*, figs. 16 and *n.vi*, 46 *b*) is found in the lower levels of the transverse cut through the motor nucleus of the facial and its genu. Its root fibres emerge posterior to the pons as in other mammals.

The motor nucleus of the trigeminal nerve (*n.m.v*, figs. 18 and 19) is found in those sections which, when the brain is cut transversely, pass through the inferior colliculus and the posterior part of the superior. The nucleus is a large spherical cell-mass lying dorsal to the decussation of the trigeminal lemniscus and medial to the ascending fascicles of the lemniscus lateralis.

The cells of the seventh motor nucleus (*nuc.d.vii and nuc.v.vii*, figs, 16, 17 and 32, *a* to *c*) are found in two elongated masses in the mid-lateral part of the medullary substance, medial to the cochlear nuclei—the dorsal motor nucleus of the nervus facialis, and an elongated spherical group, the nucleus ventralis. The extent of these two main cell-aggregations may be easily seen by a glance at fig. 78, where the ventral nucleus is projected upon the floor of the medulla, medial to the dorsal. In fig. 33, *b*, the ventral nucleus may be seen as a roundish ball of cells lying dorsal to a forked area of cells, comprising what might be called the medial and lateral division of the superior olive. In such levels, the lateral lemniscus passes into it and through it. The peculiar fraying of the medullated fibres of the lemniscus is highly suggestive of synaptic relations between it and the ventral nucleus of the seventh.

Its genu (*g.vii*, fig. 16) turns ventralward beneath the sixth nucleus, rather than dorsal, and proceeds to the three divisions of the seventh nucleus by scattered fibres.

Anterior to the level of the nucleus of the hypoglossal nerve and lateral to the ridge formed in the midline by the tegmental bundles and the fasciculus longitudinalis medialis, is a thin sheet of poorly circumscribed and undifferentiated grey matter (figs. 13 and 14). In the transverse level of the sixth motor nucleus (fig. 15) this sheet lies dorsal to the tegmental bundles and medial to the abducens. Anterior to this level it clearly shows itself to be undifferentiated grey (fig. 17) and to be continuous rostrally with the central grey of the midbrain (fig. 18). In all probability, this is the region out of which morphologically discrete nuclei, such as the nucleus prepositus or the nucleus funiculus teres, become differentiated in higher mammals.

There are two rather obscure fibre systems which relate certain of the dorsal nuclei with, and others through, the central grey matter of the medulla. They are the dorsal tegmental tract of SCHÜTZ and the tractus Fuse.

Lying ventral to the fovea inferior, medial to the dorsal nucleus of the tenth (fig. 12), the nucleus vestibularis medialis (figs. 13 and 14) and the nucleus vestibularis lateralis (fig. 15), lateral to the nucleus intercalatus (figs. 12 to 14) and the central band of grey matter (fig. 15) is a finely-medullated fibre tract, the tractus dorsalis tegmenti of SCHÜTZ (*d.t.S.*, figs. 12 to 15). In all probability it is continuous with the system, easily identified in sagittal sections, which is described in the section on the midbrain as the fasciculus longitudinalis superior. WINKLER depicts this system as a complicated system of fibres which receive axones from small cells of the nucleus of the fasciculus solitarius, discharging impulses into the motor nuclei of the tenth and twelfth nerves. Further, he thinks that some of its fibres are processes directly from the sensory branch of the peripheral seventh. They may be traced as far rostrally as the ganglion of GUDDEN. WINKLER says that the nucleus prepositus contributes a few fibres to its more caudal levels. In transverse Weigert series, the tract is easily followed just posterior to the level of the sixth nerve, or about to that region which the sagittal Weigert series gives as the caudal limit of the superior longitudinal fasciculus.

Besides this finely medullated system, another may be seen, the tractus Fuse (*tr.F.*, figs. 13 and 14) or the tractus reuniens. Its fibres are found more or less in scattered groups, and pass from the region of the nucleus vestibularis medialis, ventral to the tractus dorsalis tegmenti and the small celled nucleus of the dorsal vagus, and dorsal to the large-celled nucleus, called here after KOELLIKER the nucleus glossopharyngeus (*nuc.ix,* figs. 13 and 14).

FUSE (1913) has described it as connecting the nucleus triangularis with the nucleus intercalatus and the nucleus propositus of the same side, and perhaps of the opposite side. In these particular specimens of Platypus, only the connection between the region thought to be that of the nucleus vestibularis medialis and the nucleus intercalatus is suggested; although some of the fibres from the more dorsal and lateral part of the small-celled vagus appear to be related by the tractus Fuse to this same nucleus. There is no definite commissure to the opposite side, although it is possible that the commissure described for the hypoglossal nuclei may contain some of these fibres.

The inferior olive and the arcuate fibres.—The inferior olive (*o.i.*, figs. 12 to 15 and 70, *a* to *d*) lies on either side of the raphé near the midline, immediately dorsal to the medial lemniscus and dorso-medial to the pyramidal system (see KOELLIKER, 1901). The olive extends from the region of the nucleus of the twelfth and the nucleus of the fasciculus solitarius to that between the seventh motor and fifth motor nuclei, *i.e.*, about 4 mm. in length.

Its components may be divided into three divisions (KOOY, 1916), a dorso-lateral, a medial and a ventro-lateral. The medial olive is by far the largest, judged both by its anterior-posterior extent and its medio-lateral diameter.

At the dorsal boundary of this nucleus, about 0·8 mm. from its rostral limit, the slanting ridge of the dorso-lateral component joins the medial nucleus. This connection is maintained for the distance of 1 mm. In this transverse level the free ventro-lateral part of the dorso-lateral component is fused with the ventro-lateral subdivision. KOOY (p. 267, in section 32) has pictured a relationship similar to this in the more caudal part of the inferior olive of Echidna. A few sections caudal to this point, the dorso-lateral cell mass is linked to a dorso-medial group of cells, the medial nucleus. Together for the distance of a millimetre, these two components form an arch dorsal to the ventro-lateral component. In its more rostral reaches this arch comes in contact with a slender nucleus of the raphé, one of the many reticular nuclei so characteristic of this general region. At the extreme caudal pole of the inferior olive, the medial and the lateral components are separate and distinct cell masses. These two nuclei are known in man as the medial and dorsal accessory olives.

The ventro-lateral component of mammals is the ventral nucleus of birds, and the principal or main body of the olive in man. Rostrally, it is noticed first as a circular cell group, which a few sections more caudally appears as a ventro-lateral, bulbous outgrowth from the medial nucleus. In passing caudally it maintains that connection, until that region is reached, where the dorso-lateral and medial nuclei form an arch above the ventro-lateral cell grouping. The total length of the principal olive in Platypus forms about four-fifths of the total extent of the whole inferior olive.

The principal olive is made up of large triangular cells with a few smaller ones scattered through it. Particularly are these smaller elements found in a ventral projection about midway between its upper and lower limit (see *p.o.*, figs. 13, 14, 70, *b* and *c*). These stain quite deeply with the toluidine blue of the Nissl technique. The cells composing the medial nucleus of the olive (*m.n.o.*, figs. 13, 14, 15, 70, *a* to *d*) are slightly smaller than the larger ones in the principal or Hauptolive, although the smaller ones are about the same. Those of the dorso-lateral nucleus (*d.l.n.*) are similar to those of the medial cell mass. Besides these cells the dorso-lateral nucleus contains another kind of cell—smaller and showing less chromidial substance in its cytoplasm.

Anterior to the most cephalic limit of the medial nucleus of the inferior olive, appears that of the raphé (*n.r.r.*, figs. 16, 70, *b*, *c* and *d*), one of the many groups of cells, forming a part of the reticular system. There is another, quite similar to the lateral reticular nucleus of the cat, lying between the lateral boundary of the inferior olive, and the medial limit of the nucleus sensibilis trigemini, immediately beneath the ventral limiting membrane. There is, also, another small nucleus which lies ventro-lateral to the principal or Hauptolive, and joined to it for a short distance in the anterior third of that body. The last two nuclei described may be a part of the arcuate (*nuc.a.*, fig. 70, *b*, *c*.) group, for certainly the internal arcuate fibres, which pass into the cerebellum from the frontal end of the olive, travel through the first one described, and enter or leave the second. Besides these nuclei there is yet another which lies in the triangle formed by the nucleus sensibilis of the fifth and the area acoustica, the nucleus reticularis triangularis (*n.t.r.*, figs. 12 to 16).

In fig. 12, fibres may be seen swinging ventralward and dorsalward from the region of the nucleus gracilis to the inferior olive. In fig. 14 those leaving the nucleus cuneatus may be seen. Some of them seem to disappear in the olive of the same side, others to cross in a ventral decussation or commissure to the other. The part that the external arcuate fibres play in this decussation is easily seen in fig. 13. The majority of them are lost in the main body of the olive ; a few, however, pass lateralward to the dorso-lateral part of the olive. Rostrally, in the transverse level of the medial and spinal nuclei of the vestibular group the internal arcuate system (*i.a.f.*, figs. 14 and 15) appears to go to the medial nucleus of the olive and decussates in the raphé between the more dorsal portions. A very few fibres can be traced from the ventral portion of this nucleus passing not only into this system but also into the external arcuate (*e.a.f.*, fig. 14), which runs ventral to the sensory fifth nucleus and thence into the corpus restiforme. The major portion of the fibres at this transverse level of the olive run into the dorso-lateral and principal nuclei.

Whether or not this slight differentiation of fibres into two groups, an anterior, which passes chiefly into the medial olive, and a posterior, which connects the principal or Hauptolive, is reflected in a definite relation of these two divisions of the olive to the cerebellum, cannot be known. In man, the lateral and principal olive (ventro-lateral in Platypus) is more or less dependent upon the lateral hemispheres (HOLMES and STEWART, 1908) and the medial and dorso-lateral nuclei, upon the midline. These authors described within the old and new parts, a differentiation of fibre distribution, such that those fibres from the rostral region of the palæo-olive enter the anterior midline of the cerebellum, and those from the ventral part of the neo-olive or principal olive enter the anterior half of the lateral hemispheres. The caudal regions of the palæo-olive were connected with posterior midline while that of the neo-olive were connected with posterior half of the lateral hemispheres. If the homologies of KOOY are of any value in this instance, the differentiation of arcuate fibres into a posterior and an anterior group may mark at least the anterior posterior line of termination of these fibres in the cerebellum.

The Cerebellum.

Its macroscopic anatomy (figs. 47, *a* to *g*).—The decision in favour of any particular nomenclature for the cerebellum is no small matter, although much smaller than the initial digestion of its numerous synonyms. The author will follow for the most part the nomenclature of ELLIOT SMITH, because it corresponds more closely to the anatomical sub-divisions into which this part of the brain of Platypus naturally falls. Nevertheless, the nomenclature of BOLK will be listed also, in such a manner that anyone reading his splendid monograph will have no difficulty in placing this brain alongside of those in his description.

The medial section (fig. 47, *b*) of this cerebellum shows it to be divided into three lobes, the anterior, the middle and the posterior, by the fissura prima (*f.p.*) and the fissura secunda (*f.s.*). The anterior lobe is composed of three distinct folia, namely, the lingula (*lin.*), the lobulus centralis (*l.c.*), and the culmen (*cul.*). The intermediate lobe shows the typical subdivisions—enumerating from the anterior end, the lobulus simplex (*l.s.*), the declive (*dec.*), the folium (*f.*), the tuber (*t.*) and pyramis (*pyr.*). Separating the pyramis from the tuber, fissura supra-pyramidalis (*f.s.p.*) is not as deep as those which separate the tuber from the folium, or the declive from the lobulus simplex. The posterior lobe is divided into the uvula (*u.*) and the nodulus (*n.*) by the sulcus uvulo-nodularis (*s.u.n.*). Here, however, the uvula has two distinct folia and the nodulus five, which makes the posterior lobe of Ornithorhynchus proportionally larger than that of the majority of higher mammals thus far studied.

This division into three lobes is seen easily by looking at figs. 47, *a* and *g*. In 47, *a*, the fissura prima (*f.p.*) is a shallow fissure dividing the culmen (*cul.*) from the lobulus simplex (*l.s.*), and the fissura secunda (*f.s.*) may be seen separating the uvula from the pyramis (*pyr.*). There is nothing on the dorsal or ventral surface of this cerebellum to identify these fissures, so that their location can be determined only by a study of the medial section. No real division into medial lobe and lateral hemispheres is discerned. Indeed the whole of the cerebellum, apart from the flocculus and paraflocculus, appears to have no more division in its entirety than that generally seen in the anterior lobe of other mammals. In the latter lobe nothing peculiar appears in the culmen and lobus centralis, but the lingula consists of three small folia and contains more tissue in comparison with the bulk of the other two portions of the lobe in question than is ordinarily the case.

The middle lobe lying behind the fissura prima (*f.p.*, *a*, *b*, *c*, *d*, and *g* of fig. 47) contains the lobulus simplex (*l.s.*) and those other midline structures which are generally found in the vermis, namely, declive (*dec.*), folium (*f.*), tuber (*t.*), and pyramis (*pyr.*). The lobulus simplex has two small folia which extend laterally and ventrally until they end medially to the paraflocculus (*p.fl.*) being separated from it by a part of the fissura paraflocculàris (*f.p.fl.*, fig. 47, *f*). The fissura which forms the posterior boundary of this lobulus and separates it from the declive or the whole of the remainder of the middle lobe (the lobus complicatus of BOLK) is the fissura postlunata, or sulcus superior posterior: this sulcus separates, therefore, the relatively simple and little modified region from the one which shows great variation.

It is impossible in this brain to separate the two lateral hemispheres or the lobi ansiformes from the midline structures. Consequently, it is further not possible to divide such a lobe or its lateral part, the hemispheres, into crus I and crus II, unless of course the dividing fissure be that, which medially separates the tuber from the pyramis, and which if continued laterally would become the fissura intercruralis. However, it is noticeable that the lateral extension of these medial folia is greater than that found not only in the lobus simplex, but also in any other part of this cerebellum, except perhaps of the rather large lateral growth of the first two folia of the nodulus (compare the extent of the uvula (*u.*) and nodulus (*n.*) with that of the lobus medianus, posterior to the fissura postlunata, *f.p.l.*, in *c* and *d* of fig. 47).

The posterior lobe, which is caudal to the fissura secunda, lies entirely ventral to the other two lobes and, as is usual, approximates to the cephalic extension of the lobus anterior, the lingula (fig. 47, *e*). The flocculus and paraflocculus are attached only to this lobe, being confluent with what might be called the wings of the uvula and the first three folia of the nodulus, especially the first two (*see* the left side in fig. 47, *a* and *g*). The peculiarity of this lobe in this beast is first, its large size, five folia in the nodulus and two in the uvula, and second, the large bulbous-like processes which the lateral extensions of the uvula and the three cephalic folia of the nodulus show. The most peculiar of these processes is olive-shaped, and lies anterior to the region of the cerebellar peduncles (fig. 47, *e*); it also can be recognised protruding ventrally from beneath the main portion of the nodulus in the lateral and posterior aspects of the cerebellum (fig. 47, *g*). This olive-shaped process (*o.s.p.*, fig. 47, *e*) is well separated from the lobulus anteriorly, and also from the overlying tissue medial to it. The two posterior folia are simple, lying in the midline between the cerebral peduncles (47, *e*).

The flocculus (*fl.* 47, *f*, *g*) and paraflocculus (*p.fl.*), described by BOLK as the formatio vermicularis, are separated from the uvula and nodulus by the fissura parafloccularis (*f.p.fl.*) and from each other by the sulcus paraflocculo-flocculus (*s.p.fl.*). In the simplest formation of the paraflocculus delineated here, there are four main divisions (see drawing *f* of fig. 47). These same divisions are also found in that of the more complicated example of this structure in drawing *g*. There the flocculus which appears relatively simple in the formatio vermicularis of the young Platypus (*f.*) occurs as a more complicated structure in the brain of the adult. Whether or not this difference be due entirely to age cannot be determined here. Nevertheless, there is a general pattern or outline which can be applied to both. Furthermore, it will be noted that the left flocculus is more complicated than the right. This observation may, of course, have no value for the finding may be purely accidental. In other words, the flocculus may have two small folia, as seen in drawing 47, *f*, or it may be a much lobulated affair with five or six beadlike rain drops hanging from it ventrally (47, *g*). It is clear then that of the cerebellum the flocculus is the most variable part.

In fig. 47*e*, the cerebellar peduncles may be seen to hold a relation to each other similar to that described for higher mammals. The superior peduncle (*br.c.*) has been drawn uncut, and lies as a flat sheet lateral to the posterior third of the nodulus. Lateral and anterior to it is the inferior (*c.r.*). The middle peduncle (*p.*) lies in the angle formed by these two, yet lateral to them. All three are not as large nor as massive as those of higher mammals.

The nuclei.—There are four nuclei in the cerebellum, two lying immediately dorsal and medial, similar to the nuclei tecti, but called here by a purely descriptive name, the nuclei cerebelli medii (*n.c.m.*, figs. 2, 4 to 6, 13 to 14, and 79) and two lateral nuclei, which may be similar to the nucleus dentatus of higher mammals, the nuclei cerebelli lateralis (*n.c.l.*, fig. 3, 6 to 9, 13 to 16, and 79). The medial nucleus is a solid ellipsoid, and extends further posterior than the lateral. The lateral, although of approximately the same length as the medial, is divided into an anterior and a posterior portion by a notch, placed slightly frontalwards of its centre. Its anterior limit lies ventral to the fibres entering the cerebellum via the brachium conjunctivum. The two medial nuclei are connected by a commissure. No trace of one was observed for the lateral nuclei. These nuclei are embedded in a mass of fibre systems, whose origins and terminations cannot be determined in this material.

The peduncles.—It is of interest to note that in Platypus, the lowest of mammal forms, the three cerebellar peduncles are present; but their relative size is quite different when compared to those of the Eutheria. The largest and apparently the most important is the inferior or corpus restiforms (*c.r.*, fig. 10, 13 and 14); this contains in all probability the usual systems, connecting the cerebellum with the lower centres of the cord and medulla. The next in size is the middle peduncle, the pontine (*p.*, figs.

19 to 21), which runs from one side of the cerebellum ventrally, then turning medially it lies ventral to the large sensory fifth nucleus, sinks into the gulf between these two eminences, and gives off collaterals or ends in the pontine nuclei located there (*n.p.*, figs. 19 to 21). This peduncle then emerges and pursues a like curve over the opposite sensory nucleus of the trigeminus to the other half of the cerebellum. As the superior peduncle or the brachium conjunctivum (*tr.c.r.*, fig. 6, and *br.c.*, figs. 7, 14, 17 to 19), the smallest of the three in diameter, passes cephalward from the region of the lateral nucleus of the cerebellum, it turns medially and ventrally, forming an arc of a circle. It decussates immediately dorsal and posterior to the nucleus ruber, in which a major portion of its fascicles end.

The Structure of the Cerebellar Cortex.

The silver preparations of the cerebellum were not successful. They demonstrated only that the Purkinje cells cut the cortex into the traditional layers, the molecularis and granularis, that there were climbing fibres on the Purkinje cells; that axones of basket cells occurred around the cell bodies of those cells, and that many fibres ended about the ghosts of cells in the granular layer. In no place were collaterals from Purkinje cells seen, due to failure in technique. Nevertheless, Ornithorhynchus appears to have a typical mammalian cerebellar cortex, although the preparations at hand do not afford any understanding of the intrinsic relations of the incoming and outgoing fibres. It would have been interesting to know how many reversing axones the Purkinje cells possessed.

Fibre connections with the cerebellum.—The fibres which compose the corpus restiforme in Platypus fall into the same grouping as those found in higher mammals; namely, those which connect the vestibular apparatus with the cerebellum, the internal and external arcuate fibres which arise variously in the nuclei of the gracilis and cuneatus in the inferior olive, and possibly in the arcuate nuclei and in the sensory nuclei of the medulla, such as the vestibular division of the nervus acusticus and the nucleus sensibilis of the fifth. Besides these, there appear to be fibres which arise from the lateral funiculus of the cord and pass *via* this peduncle into the cerebellum.

Some of the fibres which form a part of the root of the eighth nerve (*r.viii*, fig. 15) pass into the medullary substance laterally; others of them continue dorso-medially and end in the large celled lateral nucleus of the vestibular system (*nuc.v.l.*). In the next figure, similar fibres may be traced into the superior vestibular nucleus (*nuc.v.d.*) which lies above the floor of the ventricle and thereby forms a portion of the medial surface of its lateral wall. The neurone of the second order (*tr.v.c.*) arises from both these nuclei, runs medially into the main medullary mass of the cerebellum, thus forming together with the uninterrupted tract the tractus vestibulo-cerebellaris (*tr.v.c.*, fig. 15).

From the dorso-lateral division of the sensory nucleus of the trigeminus, fibres join the inferior peduncle on its medial side. In this tract they form a considerable bundle.

Furthermore, this connection seems to be more or less confined to the region of the corpus restiforme and therefore throws no light upon the intrinsic divisions of the fifth nucleus itself.

In fig. 12 fibres may be seen leaving the nucleus of the fasciculus gracilis (*nuc.gr.*) passing lateralward and ventralward toward the raphé in the region of the inferior olive. Here there is great difficulty in distinguishing them from those which take their origin from the medial surface of the olive and form either the olivo-cerebellar system or the intrinsic commissure of that body. However, in fig. 13, these various groups are distinguished with more ease, for here, arising from the nucleus cuneatus (*nuc. cun.*) fibres may be traced to the raphé, passing through it in the region of the dorsal part of the olive, swinging upward and lateralward, dorsal to the sensory nucleus of the trigeminus and the nucleus cuneatus of the opposite side, and joining the corpus restiforme medially. Others of this group pass ventralward to the midline either near the centre of the olivary body or ventral to it. These fibres may be seen to turn cephalward, lateral to the olive, as the medial lemniscus ; or to end in a few nuclei ventro-lateral to the olive, probably the nuclei arcuati : or to pass beyond them either dorsal or ventral to the nucleus sensibilis quinti and thence to join the inner or outer parts of the corpus restiforme as the internal (*i.a.f.*, fig. 12) or the external (*e.a.f.*, fig. 12) arcuate fibre systems. Adding to the bulk of these two systems are those cell axones which arise in the olive itself and pass by either one of these routes into the inferior peduncle.

There appears to be no contribution to the middle peduncle except that of the pontine nuclei themselves. It is impossible of course to ascertain what relation these fibres hold to the cortex of the cerebellum.

The superior peduncle (*br.c.*, figs. 7 and 14) itself appears to contain three separate systems of pathways, a medial, a lateral and an antero-medial. The first, the tractus cerebello-ruber (*tr.c.r.*, fig. 6) passes out of the posterior central part of the nucleus cerebellaris lateralis (*n.c.l.*, figs. 6 and 7) cephalward in the lateral wall of the anterior division of the fourth ventricle, turning then ventro-medially to the region of the motor centres of the midbrain. In the level of the inferior colliculus this tract lies as a crescent-shaped bundle of fibres medial to the lateral lemniscus (*lem.l.*, fig. 18) and dorso-lateral to the tractus thalamo-olivaris (*tr.th.o.*, fig. 18). In the section passing through the colliculus superior, the cerebello-rubric tract (*br.c.*, fig. 19) bears the same relation to these two systems. When it lies in the vicinity of the main body of the third nucleus, immediately dorso-posterior to the nucleus ruber it turns quickly ventro-medially, decussates ventral to that of the tractus tecto-spinalis and ends in the latero-dorso-posterior portion of that nucleus (*d.br.c.*, fig. 20). This is the medial division of the anterior peduncle, the cerebello-rubric tract. The antero-medial part belongs to this same system, which instead of ending in the nucleus ruber, passes dorsalward and cephalward to it, becoming lost in the ventral thalamus, the tractus cerebello-thalamicus. The lateral division, composed of those fibres which form the lateral part of the superior crescent of the brachium in figs. 18 and 19, cannot be traced forward into the decussation, but appears to turn caudalward into the tegmentum of the medulla.

What separate fibre systems this component of the brachium conjunctivum contains cannot be determined at the present writing. If there be such a system as the ventral spino-cerebellar tract in Platypus (the author is unable to identify any fibres among the medial group) it seems probable then that it is mingled with the more lateral; for here, contrary to what has been demonstrated in higher mammals, the anterior medullary velum is the passage-way for tecto-cerebellar tracts.

The connections which the tectum makes with the cerebellum pass into that body *via* the velum and are of three varieties. The fibres of the first group gather themselves together into a closely compact bundle just cephalward to their point of entrance into the anterior medullary velum. They arise in thin strands from the whole posterior portion of the stratum opticum (layer four of KOELLIKER, 1896), or stratum mediale superficiale, and pass caudo-dorsal to the commissure of the tectum. The second is like unto the first in origin; arising, however, from the whole of the stratum opticum, it passes immediately ventralward interdigitating with the strands of the tectal commissure (or the 'Lage der cerebralen Sehfasern,' KOELLIKER, 1896, ii, s. 414, or the stratum mediale profundum) and thence turning caudalward, lying ventral to this commissure, it enters the anterior medullary velum, ventral and medial to the first. The third part of the tecto-cerebellar system appears in the layer which is characterized by the large cells of the mesencephalic division of the trigeminus, the ependymal or central grey layer (the sixth of KOELLIKER or the fifteenth of CAJAL).

This system enters the cerebellum in the midline. It is impossible to determine the termination of any of these tracts, although in the sagittal series all three may be traced into the anterior medullary substance of the cerebellum. These tracts are the most interesting of all the cerebellar connections, found thus far in the study of Platypus, because they are difficult to demonstrate in animals above the reptiles. This then might be called a reptilian character, nor is it the last one to be described.

The Midbrain.

In external conformation the midbrain of Ornithorhynchus resembles that of higher mammals. The optic portion of the tectum (*c.s.*, fig. 7) is much larger than the small eyes and optic commissure system of the animal would appear to warrant for the adjustment of its simple reflexes, and hints at the outset of the importance of other reflex patterns found there. This portion of the tectum is not separated into two distinct bodies as is the inferior colliculus (*c.i.*, fig. 7). It resembles, rather, a large flat plateau which merges imperceptibly with the dorsal part of the thalamus laterally and which gradually slopes anteriorly to the small projection, dorsal to the nucleus pretectalis, and posteriorly into the two sphere-like auditory centres (inferior colliculi).

On the ventral surface of the midbrain there is a prominent nuclear group, the ganglion interpedunculare (*g.i.*, figs. 2 to 6). This lies between the minute basis pedunculi (*b.p.*, fig. 21) laterally, posterior to the corpus mamillare and anterior to the tuberculum of the sensory fifth nucleus.

Here as in other vertebrates the midbrain may be divided horizontally into three regions; the most dorsal lying above the aqueduct of Sylvius and constituting the tectum (see figs. 20 and 21), the other two lying below, and constituting the tegmentum, which is very thick in Platypus, and the basis pedunculi.

The arrangement of cells and fibres in the tectum has received the attention of eminent neurologists with various results. The present author in reviewing this work upon the midbrain has thought it best to follow the classifications of KOELLIKER (1896) and WINKLER (1918) because they are by far the simplest, and furthermore constitute classifications which lend themselves more or less to a grouping of layers by their typical connection.

The outermost layer of the tectum in birds has been called that of the optic fibres by KOELLIKER (1896, Bd. ii, s. 413), and has been described as sending collaterals or ramifying in the cellular layer below, the second or first grey layer. However, there is no direct evidence in Platypus that layer one, or stratum fibrarum zonalium (*s.f.z.*, fig. 20), receives any fibres from the nervus opticus. The cells of the second layer (in WINKLER's term, stratum griseum superficiale (*s.g.s.*, fig. 61)) are small and multipolar. Ventral to the second is the third (fig. 20), broad and filled with small and many large cells, into which the fibres of the optic system of other mammals penetrate, stratum medullare superficiale (*s.m.s.*). This layer is also the origin of two of the tecto-cerebellar tracts; one, tractus tecto-cerebellaris dorsalis (*tr.t.c.d.*, fig. 20) which originates from the caudal half of the tectum and the other, tractus tecto-cerebellaris ventralis (*tr.t.c.v.*, fig. 20) which, lying in the midline beneath layer four (fig. 20), interdigitates with the transverse fibres of that layer, and thence passes into the cerebellum *via* the anterior medullary velum. Layer four, stratum griseum mediale (*s.g.m.*), is by far the thickest and contains the largest nerve cells (with the exception of the mesencephalic fifth group) in the midbrain, as well as heavily myelinated fibres, forming a layer apparently for midbrain correlation.

The fifth layer, stratum medullare mediale (*s.m.m.*), is rather thin in Platypus. It contains but few fibres as compared to layer four. It is the one in which the tecto-thalamic and probably the tecto-cortical fibres originate. These fibres run antero-posteriorly in the layer. However, there are other fibres which are medio-lateral in their course, the tecto-bulbar tract (*tr.t.b.*, fig. 20). The sixth layer is composed of the radix of the mesencephalic division of the trigeminus (*r.m.v.*, fig. 20) and is formed medially and laterally of large cells, the stratum griseum profundum (*s.g.p.*, fig. 61). In the seventh, the stratum medullare profundum (*s.m.p.*), the circular fibres of the tractus tecto-spinalis (*tr.t.sp.*, fig. 20) swing out lateralward from the midline, then turning to form the half of a circle on either side of the central grey matter, decussate ventral to the third nucleus. In the next and last layer, the stratum griseum periependymale (*s.g.per.*, figs. 20 and 61), arises the third tecto-cerebellar system, tractus mesencephalicus quinto-cerebellaris (*tr.m.q.c.*, fig. 20), whose fibres not only spread out into the small celled part of the sixth layer but also ramify among the cells of the mesencephalic nucleus in the midline. In the seventh layer there is a fibre system which comes into contact with both small and large cells of the sixth layer. It passes out into the region which lies posterior to the nucleus medialis thalami and anterior to the posterior commissure, the nucleus pretectalis (*nuc.p.*, fig. 6). Also from the central grey matter or stratum griseum periependymale, but seen to better advantage in planes lateral to the mid-sagittal section, there are two groups of fibres which pass anteriorly to end in the thalamus. The more medial, the tractus tecto-thalamicus medialis (*tr.t.th.m.*, figs. 35 to 39) to the nucleus medialis, and the lateral, the tractus tecto-subthalamicus (*tr.t.s.*, fig. 9), proceed to ramify in a nucleus which may be the central grey of the thalamus, ventral to the nucleus medialis.

In Platypus the nucleus mesencephalicus of the trigeminus lies in the form of circular arcs medial to its radix. The cells are unusually large and spherical, and either form an uninterrupted vaulting above the aqueduct or are joined on either side by a separate nucleus in the midline. In this material there is practically no difference between the midline division and the lateral except that the cells of the midline are slightly larger and more numerous. Throughout they are accompanied by longitudinal fibres which clearly belong to the radix of the mesencephalic fifth, and, therefore, appear anatomically to be but a dorsal division of the mesencephalic nucleus of the trigeminus (*nuc.m.v*, fig. 2).

The principal nuclear groups in the tegmentum are the nuclei oculomotorius and trochlearis, the nucleus ruber, the substantia nigra, the ganglion interpedunculare and nuclei of the reticulum. The *oculomotor nucleus* (*nuc.iii*, figs. 2 to 3, 20 and 69), is made up of four different components, two lateral ones, anterior and posterior, and two medial, dorsal and ventral. The posterio-lateral component lies below the anterior at its anterior limit. It is known as the ventro-lateral nucleus (*nuc.v.l.*, fig. 69, *a*). From its large triangular motor cells, whose axones cross in the midline medial to the group, fibres run anteriorly and ventralward to mingle with the other root fibres of the third. The main body of the other component of the lateral group, the nucleus dorsolateralis, lies anterior and dorsal to this nucleus (*nuc.d.l.*, figs. 69, *a* to *c*), forming an elongated group of large cells whose axones cross the midline in a manner similar to the postero-lateral group, except that the decussation is more ventrally placed in this case. These axones join the main trunk anterior to the previous ones. Lying as a cap, cephalic to this nucleus, is a group of smaller cells, the nucleus dorsomedialis (*nuc.d.m.*, figs. 69, *a* to *b*), so near the midline on either side that the two nuclei appear to coalesce. They contribute axones to the radix of this nerve without decussation. This appears to be the nucleus of Edinger-Westphal, nucleus dorsomedialis. Below, lying in the centre of the midline, is a longish nucleus, made up of small cells, the nucleus centralis (*nuc.c.*, figs. **69**, *a* to *b*). It extends forward between the fibre systems of the formatio reticularis on either side, like a slender tongue. The cells of this central nucleus also may contribute axones to the root of the third nerve in a region which lies immediately ventral to the dorso-medial nucleus.

Connecting the nucleus centralis with the nucleus ruber is a bridge of large motor-like cells, which lie so closely upon either side of the raphé as to appear as a single group. This cell-aggregation may be seen most easily in sketches *a* and *b* of fig. 69—that is, in the more anterior part of the level of the third nucleus, although it persists anterior to the main body of that nucleus (fig. 69, *c*). The characteristic cells of this nucleus are continuous cephalward with large motor-like cells which lie lateral to the aqueduct of Sylvius, ventral to the circular central grey matter which caps it (figs. 59 and 33, *c*).

The cells which form the nucleus trochlearis (*nuc.iv*, figs. 2, 3, 18 and 19) lie on either side of the midline, ventral to the aqueduct of Sylvius, beneath the corpora quadrigemina posteriora. Each nucleus is made up of two groups of cells, one of them more lateral, anterior and ventral than the other. The former is spherical in shape, and composed of large triangular cells. The latter is also spherical, but smaller, and made up of smaller cells. Both of these parts of this nucleus send out their axones to form the radix of the nucleus of the trochlear nerve. They swing dorsalward in the form of a half-circle, decussate dorsal to the aqueduct in the anterior medullary velum and emerge slightly lateral and caudal to the inferior colliculus.

The nucleus ruber (*n.r.*, figs. 4 to 7, 21, 53, 69, *a* to *c*, and 68) is irregular in shape (figs. 68 and 69); and more or less circular in cross-section in its caudal part (figs. 53 and 69, *a*); it veers upon the triangular further frontalward (fig. 69, *c*); and more rostralward (fig. 68), it appears as an ellipsoid whose long axis has been tilted medially. It is found ventral to the oculomotor nucleus (figs. 53 and 69, *a*) and dorso-medial to the substantia nigra (*s.n.*, figs. 5 to 7, 21, 22 and 68). The majority of the cells in the nucleus are very large, and contain a great deal of chromidial substance. At the present it is impossible to outline their distribution or relationships to the smaller cells found among them, except that more rostrally the smaller ones occur among the larger. However, it is possible to determine with which part of the nucleus the main fibre systems are connected. Posterior to its caudal extremity, the brachium conjunctivum decussates (*d.br.c.*, figs. 20 and 53) and turns dorsally to enter the medial boundary of the posterior part of this nucleus. From the anterior portion, but also ventro-medial in reference to the nucleus ruber, the axones of the tractus rubro-spinalis leave the nucleus. These axones cross to the opposite side, remaining in the vicinity of the midline, and ventral to the lateral boundary of the main body of the nucleus. The fibres which come from the corpus striatum, tractus striato-mesencephalicus, enter the dorsal part of the nucleus from the rostral side. Yet laterally along its entire anterior border there terminate fibre systems which appear to have their origin further rostralward, constituting a possible tractus cortico-rubricus.

The substantia nigra (*s.n.*, figs. 5 to 7, 21, 22 and 68) lies as two slanting slits of grey matter ventro-lateral to the nucleus ruber and dorsal to the fibres of the basis pedunculi. The two portions of the substantia appear to be composed of large triangular cells smaller than those of the nucleus ruber, and to receive the same kind of fibres from the corpus striatum as does the nucleus ruber. Further, fibres which swing out of the ventro-lateral part of the cerebral cortex dorsally, pass through the main body of the corpus striatum, turn ventrally and slightly medially to enter the dorsal aspect of the substantia nigra.

The ganglion interpedunculare (*g.i.*, figs. 2 to 4, 20 and 21) lies medial to the basis pedunculi. The ganglion is a large spherical group of cells, which both in size and shape resemble those of the ganglion habenulare. On its latero-dorsal aspect it receives fibres from the ganglion dorsale tegmenti and in its ventro-anterior, from the habenula ; the ganglion discharges impulses over axones which emerge caudally to pass into the tegmentum of the mid-brain and medulla.

The ganglion tegmenti dorsale (*g.d.*, figs. 35 and 36) has been identified by the writer as a large prominent group of cells, which lies midway between the nucleus of the sixth and that of the fourth nerves. It is this nucleus which in medial sagittal section shows such a prominent connection with the ganglion interpedunculare. Also, fibres emerge from it and pass caudalward into the tegmentum of the medulla, the "dorsalis Längsbündel" of SCHÜTZ, or the fasciculus longitudinalis superior. Ventral to the ganglion tegmenti dorsale, on either side of the midline in formatio reticularis, the ganglion tegmenti profundum Guddenii may be identified.

Midbrain nuclei in the vicinity of the fasciculus longitudinalis medialis may be listed as follows :—The nucleus of the fasciculus longitudinalis medialis, the nucleus interstitialis, the nucleus of the commissura posterior and the nucleus ellipticus.

The nucleus of the fasciculus longitudinalis medialis (*n.f.l.m.*, figs. 21 and 33, *b*), a poorly circumscribed group of cells, lies dorso-lateral of the nucleus oculomotorius and yet ventral and lateral of the aqueduct of Sylvius. This nuclear mass merges almost insensibly into the central grey matter surrounding the third ventricle. It is not therefore as distinct a nucleus in Platypus as TSAI (1925, *a*) has pictured for the opossum (fig. 13, *nuc.f.l.m.*), nor does it lie in the same relative position as the dorsal nucleus of the fasciculus longitudinalis medialis in *Phoca vitulina* (fig. 1, *kern d. Fasc. long. dors.*, Riese, 1924).

The nucleus of the posterior commissure or that of DARKSCHEWITSCH (*n.c.p.*, figs. 21, 22 and 59) may be seen as a more or less spherical group of cells lying at the caudal level of the posterior commissure and dorso-medial to the nucleus pretectalis. The fibres of the dorsal commissure enter it and fibres leave it, circling medio-ventrally to enter the medial longitudinal fasciculus. Its general position in the rostral transverse level is more lateral than in other brains where the nucleus has been described, for example, in the work of MUSKENS (1922) on the cat. In the more rostral part of the commissura posterior, where its angle of ventro-lateral passage is sharpest, there is no evidence of a discrete nucleus in close relation to the commissure fibres, although the cells of the generalised region are not as large as those of the nucleus pretectalis. The commissural fibres are lost, however, in a more generalised region, which may belong to the nucleus just described.

The nucleus interstitialis (*n.i.*, figs. 21, 59 and 61) in Platypus might be described as that area which lies lateral to the nucleus of the third nerve and the nucleus of the fasciculus longitudinalis medialis, dorsal to the lateral extension of the nucleus ruber, amongst part of the fibres which form the dorsal tegmental decussation. Further, it lies medial to the nucleus pretectalis, and the fibres which connect that nucleus with the central grey matter ventral to the aqueduct pass through it. It appears to deliver some fibres to the fasciculus longitudinalis medialis and to the region of the capsule of the nucleus ruber, as well as to receive some fibres from the posterior commissure.

Generally speaking, the central grey matter within the midbrain of Ornithorhynchus is highly differentiated. The cells which lie beneath the commissure of the anterior colliculus within the place of the origin or termination of some of the tecto-thalamic connections, and yet ventral or medial to the mesencephalic nucleus of the trigeminus, are medium-sized polymorphous and pyramidal cells. In Platypus they stand out quite prominently, as different from the smaller and more scattered cells which are found within the immediate area about the aqueduct. Further, they are not confused with either the various nuclei of the oculomotor group or the nucleus of the fasciculus longitudinalis medialis (figs. 33, *b* and *c*). These cells in question have never received a circumscribed designation other than that which recognises them as the eighth layer of the anterior tectum, the stratum griseum periependymale.

Anterior to this particular differentiation and the level of the third nucleus, in the region of the main body of commissura posterior, the medium-size cells give way to large polymorphous cells, so that the grey matter about the slit-like aqueduct may be said to form one large nucleus. It is somewhat similar to the corpus ellipticum of HATSCHEK and SCHLESINGER (1902) which they described for a nucleus lying in the central grey matter, dorsal to oculomotor nucleus in the Delphinus, and which was regarded by them and RIESE (1924) as peculiar to aquatic mammals. The writer was unable to demonstrate any connections for this nucleus except fibres which spread laterally to end in the nucleus pretectalis and the nucleus interstitialis and a few which may mingle with the striatal and longitudinalis fasciculus group. The nucleus certainly lies anterior to the origin of the dorsal limb of the fasciculus longitudinal medialis. In all probability it is homologous with that nucleus in *Delphinus delphis*. The writer therefore will call this group of cells the *corpus ellipticum* (see *c.ell.*, figs. 33, *c*, *d*, and 59). Just posterior to the actual crossing of the commissure this differentiation within the central grey is more or less elliptical in form.

The Fibre Tracts of the Mid Brain.

The description of the fibre tracts of the midbrain falls naturally into place with the systematic description of the systems characteristic of its three levels, the tectum, the tegmentum and the basis pedunculi.

Within the optic tectum there are five layers of fibres :—The outermost, the stratum zonale superficiale, which is spread out thinly immediately ventral to the dorsal limiting membrane. From this superficial layer of fibres arises a tract, which the writer has called the tractus thalamicus lateralis superficialis (*tr.t.l.s.*, fig. 21) ; this tract appears to connect the tectum with what has been called the dorsal part of the lateral geniculate body (*l.g.b.d.*). From the second layer, originate rostrally the systems which connect this region with the habenula (*tr.t.h.*, fig. 40) and thalamus. And together with the third layer the second sends out systems laterally to the dorsal part of the lateral geniculate body of the thalamus and the nucleus pretectalis. Caudally the more dorsal and lateral of the tecto-cerebellar systems leave this second layer. The third layer is made up of fibres connecting with the nucleus pretectalis (*tr.t.p.*, fig. 21). This layer is the origin of some of the fibres of the tractus tecto-cerebellaris ventralis (*tr.t.c.v.*, fig. 36), but also of the fibres of the tectal component of the posterior commissure. The fourth layer is connected caudally with the cerebellum (*tr.m.q.c.*, figs. 20 and 35) and ventrally with the bulb. Rostrally it is connected with the nucleus pretectalis. The anterior and medial nuclei of the thalamus have fibre connections with the central grey matter, above the aqueduct.

The fibre layers of the posterior colliculus of the tectum which correspond to those of the anterior colliculus are the fourth and fifth. Besides these on the lateral surface, the fibres which belong to the lateral lemniscus series pass by the inferior colliculus ending in the medial geniculate body of the thalamus. The more medial fibres of this lemniscus pass into the centre of the colliculus. The medial fibre layer appears to belong to the tecto-bulbar connections or perhaps to the tecto-spinal. These systems are more characteristic of the superior colliculus, however.

The afferent systems of the tectum.—The lateral lemniscus (*lem.l.*, figs. 18 and 10) turns dorsalward at an angle approaching 90° in the region of the motor nucleus of the trigeminus, to end in the inferior colliculus or to pass by this colliculus laterally and to terminate in the medial geniculate body.

The tractus opticus (*tr.o.*, fig. 7, *tr.op.*, fig. 23) after decussating and travelling caudad and dorsalward along the lateral margin of the hypothalamus penetrates the thalamus, swings dorso-lateralward and then medially to the ventral lateral geniculate body and is lost to sight of the writer.

The tractus bulbo-tectalis et spino-tectalis may exist mingled with fibres going in the opposite direction. Indeed that is true of all the systems described, and consequently the direction of a fasciculus given is that one which is characteristic of it in other vertebrates. The material does not lend itself to the possibility of tracing any secondary connections of the tectum with the visceral systems of the medulla.

The efferent systems of the tectum.—The tecto-cerebellar system consists of three separate tracts ; the most dorsal and lateral of the three, the *tractus tecto-cerebellaris dorsalis* (*tr.t.c.d.*, figs. 36 and 39) originates in the third tectal layer and passes caudalward through the velum medullare anterior into the central white matter of the cerebellum beyond which point the author can trace it no further. The immediate system, the *tractus tecto-cerebellaris ventralis* (*tr.t.c.v.*, figs. 36, 39 and 40) arises partly in the third layer and partly below it, passes ventralward, interdigitating with the transverse fibres of layer five and those of the commissura mesencephali, turns quickly ventral to them and passes caudad ventral and medial to the dorsal tract. The ventral system arises partly in the central grey matter itself and partly from the large ganglion-like cells lying in the midline, which appear to be the medial nucleus of the mesencephalic division of the trigeminus. This tract is known as the *tractus mesencephalicus quinto-cerebellaris* (*tr.m.q.c.*, fig. 35). It lies ventral to the intermediate tract and makes its way into the rostral part of the central white matter of the cerebellum *via* the most medial part of the anterior medullary velum. Structures which appear to be dendrites of this system may be seen surrounding the mesencephalic cells in a manner similar to that in which the Purkinje cell is surrounded by the axones of the basket cell. It is possible that the tractus mesencephalicus quinto-cerebellaris is an afferent system, or that it is both afferent and efferent : this question cannot be determined here. However, that this connection, whatever its nature, should exist is interesting.

The tecto-spinal system (*tr.t.sp.*, fig. 42), and perhaps here associated with its reciprocal, arises in the sixth layer of the tectum, swings ventrally around the central grey matter forming the two halves of a circle, and decussates ventral to the nucleus of the oculomotor nerve and dorsal to the cross of the brachium conjunctivum. It lies medial to that other tectal system, the tecto-bulbaris (*tr.t.b.*, fig. 43), which originates in the layer of cells lying between the third and fourth fibre sheets. This system circles far out lateralward beyond the first fibre group, and appears not to decussate at the point where its two halves meet, in the peduncle medial to the two halves of the medial lemniscus.

Originating in the stratum medullare superficiale in layer four, the one medial and the other lateral, are the *tractus tecto-habenularis et pretectalis* (*tr.t.h.*, and *tr.t.p.*, fig. 40) and the *tractus tecto-subthalamicus.* The former gathers together fibres from the rostral end of the superior colliculus into a strand which passes anteriorly dorsal to the dorsal commissure along the outer surface of the nucleus pretectalis, giving off collaterals or partially ending within that body, and finally ending in the dorsal surface of the caudal end of the habenula. Lateral to this and from the same region, fibres pass ventralward lateral to the great midline systems like the fasciculus longitudinalis medialis and the thalamic descending systems to the two more lateral and dorsal nuclei of the subthalamus (*tr.t.s.*, figs. med. 39 and 81). Some of these fibres appear to join at the postero-lateral boundary those which enter the post-optic commissure. Whether they turn back to the subthalamus of the opposite side or what their further fate is, cannot be determined here. Other fibres, which do not end in the subthalamus nor yet pass into the commissura post-optica, become lost in that enormous nuclear mass, which lies on either side of the third ventricle, ventral to the medial nucleus of the thalamus, anterior to the subthalamus, dorsal to the tuber cinereum and posterior to the commissura anterior—a part certainly, but here a major part, of the hypothalamus. These fibres form the *tractus tecto-hypothalamicus* (*tr.t.h.th.*, fig. 36).

From the central grey mass lying dorsal to the aqueduct of Sylvius and immediately lateral to the midline, there are many diffuse fibre systems which pass cephalward through the nucleus pretectalis, and turn ventralward along the ventro-posterior boundary of the medial nucleus. These fibre systems constitute the *tractus tecto-thalamicus medialis* (*tr.t.th.m.*, figs. 35, 36, 37 and 39). Some of these fibres continue anteriorly below the medial thalamic nucleus and end in the ventral part of the anterior nucleus, forming the *tractus tecto-thalamicus anterior* (*tr.t.th.a.*, fig. 37).

The Fibre Systems of the Tegmentum.

The fasciculus longitudinalis medialis.—The fibres of which this system (*f.l.m.*, figs. 2, 3, 12 to 21 and 35 to 38) is composed lie in the midbrain of Platypus, as two deeply staining bundles on either side of the raphé, ventral to the nuclei of the third and fourth nerves in their usual mammalian relationships. In sagittal section it is not difficult to trace the fibres of the fasciculus longitudinalis medialis (*f.l.m.*, figs. 2, 3, and 35 to 38) rostralward into its nucleus (*n.f.l.m.*, fig. 21) which lies anterior to the oculomotor group, nor to follow it ventralward and anteriorly as it crosses into the more dorsal and more lateral of four nuclei which form the subthalamus (*n.l.s.*, figs. 22 to 24). It is an unusually large bundle of fibres for so small a brain as that of Ornithorhynchus; it can be easily followed caudally into the region of the nucleus hypoglossus as a part of the dorsal tegmental bundle. In transverse section it is possible to see the fibres which connect it with the nuclei of the oculomotor, the trochlear and the abducens nerves. In the level of the vestibular division of the eighth nerve fibres may be followed from its lateral nucleus and possibly from its medial into the midline dorsal bundles. None could be followed from the superior, probably because that nucleus is so far away from the raphé and because fibres which did enter this bundle from it would pass through the lateral nucleus. Nor was it possible to discover any connection with the motor nuclei of the trigeminus and the facial or with the nucleus ambiguus. However, numerous fibres pour into the nucleus hypoglossus from this midline tegmental system, and a few can be followed into the dorsal motor nucleus of the vagus, into the nucleus of the fasciculus solitarius, into the ventral division of the dorsal motor tenth, and into the nucleus intercalatus Staderini.

The fasciculus longitudinalis superior.—A small system of fibres may be seen ventral to the aqueduct of Sylvius in the central grey mass—the fasciculus longitudinalis superior (*f.l.s.*, fig. 39, p. 163 of this paper). It connects the nucleus of the third nerve with the fourth and sixth by passing dorsal to the ganglion dorsale, and in all probability, sends some fibres into the ganglion itself.

The tegmento-thalamic systems.—There are three groups of connections which the tegmentum makes with the thalamus. They are first with the phylogenetically older portion of pars dorsalis, *i.e.*, anterior and medial nuclei of the thalamus ; second, with the pars ventralis, *i.e.*, the subthalamus ; and third, with the hypothalamus.

The tractus tegmento-thalamicus anterior et medialis.—From that portion of the tegmentum which lies ventral to the aqueduct, and the central grey matter, lateral to the midline and dorsal to the main body of the fasciculus longitudinalis medialis, there is gathered together a large fibre system which may be traced antero-ventrally, forming an arc of a circle ; part of the system reverses its direction, as it approaches the ventro-caudal boundary of the medial nucleus, to one anterior-dorsal. It gives off fibres to the nucleus medialis thalami and to the cell-mass which lies anterior and dorsal to it—the nucleus anterior thalami. This is the tractus tegmento-thalamicus anterior and medialis (*tr.te.th.a.* and *m.*, figs. 36 to 38). Also as it passes through the ventral limits of the nucleus pretectalis, some of its fibres are lost.

The tractus tegmento-subthalamicus et hypothalamicus.—That portion of the tegmental bundle which does not change its direction (*i.e.*, the more medial division) proceeds ventralward into the dorsal nucleus of the ventricular grey matter of the hypothalamus, forming the tractus tegmento-subthalamicus et hypothalamicus (*tr.te.s.*, figs. 37 and 38, and *tr.te.h.th.*, fig. 36).

Also dispersed among these fibres and having a similar origin, are those which turn caudalward in the grey matter of the ventral tegmental region and end anterior to the nucleus ruber and substantia nigra—a tegmento-tegmentalis connection.

The cerebello-rubric tract.—This tract (*tr.c.r.*, fig. 42) arises in the nucleus cerebellaris lateralis, passes pontalwards through the lateral wall of the anterior part of the fourth ventricle into the posterior part of the midbrain, from thence it swings ventralward in the form of an arc of a circle dorsal and posterior to the nucleus ruber (*n.r.*, figs. 40 to 42), in which some of its fibres end. The remainder passes into the thalamus.

The rubro-spinal tract.—The tractus rubro-spinalis (*tr.r.sp.*, figs. 40 and 41) leaves the ventro-medial part of the nucleus ruber, decussates in the midline between, and ventral to, the two nuclei dorsal to the ganglion interpedunculare and passes caudally into the medulla, where it can be followed for a short distance lying dorsal to the medial part of the nucleus sensibilis trigeminus.

The commissures.—The commissures of the midbrain might be described as three : two of them, found in the tectum proper, the fibres crossing the inferior and superior colliculi, and the third, that of the commissura posterior.

The fibres of the inferior colliculus which cross in the midbrain are of two varieties : first, those which pass from one spherical nucleus on one side to its fellow on the other, constituting the commissure of the inferior colliculus (*c.i.c.*, fig. 18), and those which form a decussation (*d.i.c.*, fig. 18) in such a manner that the inferior colliculus is connected with the central grey matter about the aqueduct of the opposite side.

In the superior colliculus at least four kinds of fibres cross the midline—those which connect the two halves of the tectum itself, those which pass beyond the tectum and turn into the upper part of the tegmentum, forming what may be a commissure for the dorsal tegmentum in its rostral part, the nucleus of the dorsal tegmentum (*n.d.t.*, fig. 20). Fibres forming a part of the third fibre layer of the tectum pass from that layer on one side to the dorso-lateral part of the central grey matter, connecting that layer which is thought to be concerned with the reception of optic fibres, with the central grey matter from which some of the tecto-thalamic tracts emanate. Peculiarly enough, the mesencephalic root of the trigeminal nerve, in the more caudal portion of the midbrain decussates in the midline, before it reaches the cells which form the medial mesencephalic nucleus of the opposite side.

In transverse section the *commissura posterior* (*c.p.*, figs. 21 and 22) appears immediately caudal to the superior commissure of the habenula. At that level the commissure is a slender sheet of fibres which spread far laterally and disappear into the nucleus of the posterior commissure (*n.c.p.*, fig. 22). There are two groups of fibres which leave the ventral border of this nucleus; of these one, a cylindrical band of heavily medullated fibres from the ventro-medial limit which swings more medially and yet more ventrally to lie in the medio-lateral part of the tegmentum, where it probably turns to lie horizontally in the brain stem. It is possible that the fibres of this bundle form a system similar to that portrayed in MUSKENS' (1922) description for the cat—the tractus interstitio-spinalis or perhaps the fasciculus vestibularis mesencephalicus homolateralis (1914). Certainly the fibres turn into the tegmentum lateral and anterior to the fasciculus longitudinalis medialis. They are labelled here the tractus interstitialis tegmentalis (*tr.i.t.*, fig. 22). They are joined laterally by fibres from the nucleus pretectalis (*nuc.p.*, fig. 22). Slightly anterior to this tract lies the other one, which makes its exit from the nucleus of the commissura posterior ventrally and laterally. It swings laterally and ventrally and is lost to pursuit just dorsal to the substantia nigra. It is possible that this may be the system which connects the nucleus of the posterior commissure with corpus striatum.

This same slender sheet of fibres of the posterior commissure is found still posterior to the nucleus just described, connecting the two nuclei pretectales throughout their rostro-caudal length (see left side of commissure posterior in fig. 22).

Ventral to this slender sheet which connects the two nuclei of the commissure and the two nuclei pretectales, is the thick part of the commissure. Its more lateral wings spread out beneath the slender dorsal sheet into two divisions, a lateral one which connects the two nuclei interstitiales (see *c.p.* and *n.i.*, fig. 21), and a medial which swings out ventral to the lateral, like an arc of a great circle. Its fibres then find a place ventral to the central gray and lateral of the fasciculus longitudinalis medialis. They probably augment those from the nucleus of the commissura posterior in forming a part of the interstitial spinal or vestibular connections. It is possible also that some of the more medial fibres in the commissure pass into the corpus ellipticum of the central gray.

Connections of the corpus ellipticum.—The corpus ellipticum (see p. 176), a nucleus characterised by large polymorphic cells and surrounding the central half of the aqueduct of Sylvius, is connected with nearby regions in an interesting way. Leaving the nucleus from its lateral boundary just medial to the inner fibres of the commissura posterior are some scattered fibres. Spreading out laterally in a fan-like manner, they penetrate the medial border of the nucleus pretectalis, the tractus elliptico-pretectalis and the nucleus interstialis.

Found along the inner border of the aqueduct of Sylvius, are finely-medullated fibres. They may be traced with care as they pass ventrally until they reach the horizontal level of the corpus mamillare, where they circle laterally about the tractus mamillo-thalamicus; then, changing their dorsal direction for a lateral one, forming thereby an S-curve, they disappear in the tegmentum immediately dorsal to the substantia nigra. Since this tract is lost in a wilderness of fibres, the writer has no suggestion as to its homology, unless a part of the pathway between the fasciculus longitudinalis medialis and the globus pallidus, such as described by RIESE (1924) for *Delphinus delphis*, has been chanced upon. It is not altogether certain whether or not the fibres from the corpus ellipticum join this system or whether they are lost in the fasciculus longitudinalis medialis only.

Through systems.—There are many important systems which pass through the mid-brain. The tractus mamillo-peduncularis (*tr.m.p.d.*, fig. 5, and *tr.m.p.v.*, fig. 5) lies ventral and lateral to the fasciculus longitudinalis. The scattered fibres of the tractus pretecto-peduncularis joins the tractus subthalamo-peduncularis (*tr.s.p.*, figs. 37 to 40) in the region of the nucleus of the commissure posterior. It lies lateral and slightly dorsal to the horizontal plane of this fasciculus, turns suddenly ventro-posteriorly at the level of the inferior colliculus, ventral to this same tract. The tractus hypothalamo-peduncularis and subthalamo-peduncularis (*tr.h.th.p.*, and *tr.s.p.*, fig. 39) travel in the same dorso-ventral plane with the mammillo-peduncular system (*tr.m.p.d.*, figs. 37 and 38) and pass ventrally into the enormous formatio reticularis system of the medulla. In this case the hypothalamic part had its origin in the posterior portion of the tuber cinereum and in the ventricular nucleus which lies posterior to the optic commissure. Besides, there is a representative of what may be identified as the thalamo-olivary system, the tractus subthalamo-olivaris (*tr.s.o.*, fig. 38), which originates in the dorsal nucleus of the subthalamus and passes dorsal and lateral to the mammillo-peduncular system.

The Thalamus.

(Figs. 3 to 11; 20 to 26; 35 to 44; 55 to 61 and 82.)

In the drawing of the lateral surface of the thalamus (fig. 44) the enormous projection of the nucleus ventro-lateralis is the most conspicuous feature of the whole. Ventral to it and lying in the shadow of its projection is the thinnish subthalamus, while yet ventral to the subthalamus is the hypothalamus.

The morphology of the thalamus of Platypus can be most easily described by using the division-lines which Herrick (1917) applied to the thalamus of Necturus. Herrick's departure from the usual procedure lies in the classification of the main body of the diencephalon into pars dorsalis and pars ventralis. Then, following the suggestions of Edinger for other parts of the brain, the pars dorsalis may be further divided into the new and old thalamus. Under the old thalamus come also the epithalamus and hypothalamus.

The epithalamus resembles that of all other vertebrates, containing a long slender habenula (*hab.m.*, fig. 4) and large stria medullaris (*str.m.th.*, fig. 4). But the hypothalamus simulates that of amphibians and reptiles in its relative size and content. Besides the corpus mamillare and tuber cinereum, there is a large area lying dorsal and anterior to those bodies, ventral to the subthalamus, posterior to the anterior commissure ; this area has been called by various investigators of reptilian brains ventricular grey matter. In Platypus, however, at least three distinct regions may be described, one, posterior to the anterior commissure ; another, dorsal and posterior to the optic chiasma in which some of the decussating fibres of the post-optic commissure terminate ; and a third, the remainder. It is probably the part of wisdom to call the whole structure simply hypothalamus, with the exception of the second, which after the manner of Herrick (1917) may be specifically named the nucleus postopticus because of its relation to the commissure.

The line of demarcation between the pars dorsalis and the pars ventralis thalami is easy to draw, either in the transverse or sagittal series. The pars dorsalis thalami itself may be divided again into the phylogenetically older part and the newer part. As outlined by Crosby (private communication) for reptiles, the former consists of the nucleus anterior, the nucleus medialis and the nucleus reuniens (*n.a.*, *nuc.m.* and *nuc.reu.*, figs. 24 to 26, and 55, 57, 58 and 82). Besides these there is one nuclear mass, similar to the nucleus lentiformis of reptiles or the nucleus pretectalis of marsupials, lying near the midline, interposed between the anterior part of the tectum and the caudal portion of the pars dorsalis thalami. The connections of this nuclear mass indicate that it resembles the pars intercalaris as described by Herrick for Necturus. The new part of the dorsal receptive area of the thalamus, is undoubtedly the lateral nucleus, the dorsal-caudal region of which is the optic thalamus. The lateral nucleus itself shows a slight differentiation within its mass, in that the various somæsthetic lemniscus systems penetrate its different regions. Quite apart from these, and ventro-medial to the ventro-posterior projection of the nucleus lateralis, well differentiated as a separate entity is the medial geniculate body (*m.g.b.*, figs. 9 and 10).

The pars ventralis thalami or the subthalamus (*subth.*, figs. 2 to 7 and 36) lies ventral to the medial nucleus in sagittal section. It contains at least four distinct nuclei. There may be others but it is impossible to circumscribe them and ascertain any individual connections. Of these nuclei, two are medial and two lateral. The medial nuclei lie dorso-ventral to each other, the nucleus ventralis subthalami (*n.v.s.*, figs. 3 to 5, 23, 24, 39 and 58) and the nucleus dorsalis subthalami (*n.d.s.*, figs 2, 3, 23, 37 to 39 and 58).

The more medial of the two lateral is much larger than the lateral and might be called the nucleus lateralis magno-cellularis subthalami (*n.l.m.s.*, figs. 5 to 7, 23, 40 to 41 and 58), and the other, the nucleus lateralis subthalami (*n.l.s.*, figs. 8 to 10, 22 to 24, and 58).

Were there any harmony in the previous descriptions of this region, the author would not consider increasing the bulk of neurological nomenclature. Therefore it appears to be the part of wisdom to give these nuclei names which are purely descriptive of their relative topography.

The Pars Dorsalis Thalami.

The nucleus anterior (*n.a.*, figs. 4 to 7 ; 23 to 26 ; 37, 38, 55, 57 and 58) is a crescent-shaped body which lies anterior and medial to the nucleus medialis and ventral to the arc described by the stria medullaris of the epithalamus (figs. 4 to 7). It is a shallow nucleus. If its cellular structure (fig. 63*b*) be a criterion, its lateral limits are confined beneath the tent formed by the stria medullaris. Its cells are much smaller and more closely packed than those characteristic of the anterior part of the nucleus medialis.

The nucleus medialis (*nuc.m.*, figs. 2 to 7 ; 23 to 26 ; 35 to 43 and 55 to 58) as seen in its anterior transverse section is almost a sphere, bounded cephalward by the arciform nucleus anterior, and caudalward by an area of large polymorphous cells which might be described as the nucleus posterior thalami. Ventral to it is the subthalamus (figs. 2 to 7). It is interrupted in the midline by the mass intermedia, as well as the nucleus reuniens ; and the commissura thalami courses through its ventral border. In figs. 23 and 24 the stria medullaris and the habenula are dorsal to its medial portion, and laterally. These structures maintain this general topography except in the region which the writer has called the dorsal lateral geniculate body. The anterior rotund part of the nucleus is similar in morphology and fibre connections with the reptilian nucleus rotundus. The cells of this division are large, triangular, with centrally placed nuclei and are packed rather closely together. Just anterior to the level of the habenula lateralis and then lateral to the rostral reaches of that body, the cells of the nucleus medialis, although unvarying in size, lie more thickly in the neuropile, and in the Bielschowsky series take a deeper stain with the silver. This region is distinguished by a few fibres which connect it with the lateral habenula nucleus. Otherwise this region is not distinguished and the writer therefore has not given it a distinct name.

In this same region the lateral diameter of the nucleus medialis has increased (fig. 58) so that its outline now approaches that of an ellipse. In the ventro-lateral part the cells are smaller and more widely spaced ; in the dorsal, they are quite the same. This lateral expansion is peculiar to Platypus. Within so short a distance caudally as 200 μ the differentiation with the lateral reaches has shifted, so that the lateral part of this nuclear mass may be divided in three distinct nuclei, using the dominant cellular types as a criterion (fig. 59). These three divisions will be described as the nuclei dorso-lateralis, medio-lateralis and ventro-lateralis thalami. In all probability the dorso-lateral and medio-lateral nuclei are but slight differentiations within the cellular area which is homologous to the nucleus lateralis thalami. Further, the rostral portion of the nucleus ventro-lateralis may be homologous with the " centre median," because that is the termination of the trigeminal lemniscus, while its caudal region receives the medial lemniscus and may be likened to the nucleus ventralis thalami. Nevertheless, there is no appreciable cellular distinction.

Of the lateral group of nuclei just named, the nucleus *ventro-lateralis* is the largest (*nuc.v.l.th.*, figs. 8 to 11 ; 21 to 24 ; 59 and 82) and most eccentric. In fig. 24, which shows that cell mass in its more cephalic extent, the nucleus is bounded laterally by the putamen, dorsally by the nucleus dorso-lateralis and medially by the nucleus medialis proper and ventrally by the fibres of the thalamic commissure. However, in Platypus, the most distinctive feature of the nucleus ventro-lateralis is its growth caudally, so that the corpus striatum encircles it as a thin concentric shell about its periphery. Sagittal section (fig. 11) through its extreme lateral part discloses a thalamic island completely surrounded by corpus striatum.

The cells of the ventro-lateral nucleus (fig. 63*a*) are much smaller in diameter than those of the nucleus medialis and more varied both in size and shape. In the Weigert series it is distinguished by innumerable small bundles of fibres which run rostrocaudally through it and by the heavy fibres which pierce the lateral medullary lamina on their way to the cortex or perhaps to the corpus striatum.

The nucleus medio-lateralis (*nuc.m.l.th.*, figs. 8, 22, 59 and 82) is bounded dorsally by the nucleus dorso-lateralis, ventrally and caudally by the nucleus ventro-lateralis and laterally by the nucleus pretectalis. Its cells (figs. 63*a*) are larger than those of its ventral neighbour and not as varied in size. Their staining also in the silver of the Bielschowsky is more intense.

The nucleus dorso-lateralis (*nuc.d.l.th.*, figs. 8, 9, 22 to 24, 58, 59 and 82) lies dorsal to the former nucleus, lateral to the corpus geniculatum laterale dorsale, caudal to the medial nucleus. Its cells are very similar to those of the medio-lateral group.

There is a region which lies caudal to the medial nucleus, medial to the nucleus ventrolateralis thalami, ventral to the nucleus pretectalis and other nuclei peculiar to the region of the rostral end of the posterior commissure ; this region the writer is at a loss to define in name, and in homology. Its cells are rather large and polymorphous, but resemble in no way those of the prominent motor centres of either the midbrain or thalamus. It may be no more than a generalised tegmentum. Its medio-lateral diameter is greater, but its antero-posterior must be in the neighbourhood of half a millimetre. It is possible that it is the nucleus posterior thalami.

The medial geniculate body (*m.g.b.*, figs. 9, 10, 20 to 21). The auditory nucleus of the diencephalon is a small olive-shaped body which lies in the ventro-lateral region of the caudal limit of the thalamus. In the level photographed in fig. 20, it lies dorsal to the two nuclei of the amygdaloid complex. In fig. 21 the body of the basis pedunculi (*b.p.*) is medial to it. This relationship is not as evident in fig. 21 as it is in reality, because the fibres of that great system have not been well stained. This nucleus is flush with the surface so that its localization must be made by connections only.

The " optic " thalamus may be said to include not only the two divisions of the lateral geniculate body, but also other centres to which the fibres of the tractus opticus may be traced, such as the nucleus lateralis subthalami, and the nucleus of the tractus opticus accessorius posterior. Besides these centres, described as cells of termination for various parts of the optic tract, the nucleus supraopticus has often been depicted as receiving some of its fibres from the tract as it turned dorso-laterally.

The nucleus which has been identified as the *ventral lateral geniculate body* (*l.g.b.v.*, figs. 9, 10 and 20) by its reception of fibres, which turn about the lateral border of the medial geniculate body and end therein, lies dorso-medial to the medial geniculate body. It is elliptical in transverse section and rather longish. Its cells are smaller in diameter than those of the nearby tegmentum.

The dorsal lateral geniculate body (*l.g.b.d.*, figs. 9, 10, 21, and 59 to 61) cannot be identified with absolute certainty in the brains of Platypus at the writer's disposal, because it was not possible to follow the tractus opticus further than the ventral division of the lateral geniculate. Nevertheless, in the fœtal brains of Ornithorhynchus (that of specimen X, fig. 89, *c*, and specimen Delta, fig. 88, *b*) a slender nucleus lying dorso-lateral to the nucleus medialis must be the lateral geniculate body, for the tractus opticus can be traced to it, without question. If the adult brain be examined for a nucleus which would hold approximately the same relationship with the surrounding cellular groups, one may be identified ; and in the figures, it is so labelled. It lies dorsal to the medial part of the nucleus dorso-lateralis thalami and the nucleus pretectalis. It is in part lateral to the nucleus of the dorsal commissure and to the anterior reaches of superior colliculus ; and, in sagittal sections anterior and ventral to the two nuclei of the stria terminalis (fig. 9).

The nucleus pretectalis (*nuc. p.*, figs. 6, 7, 21, 22, 59 to 61 and 82) in cross-section is an irregular trapezoid. It lies posterior to nucleus medialis and ventro-caudal to the habenula. Its anterior limit coincides more or less with the rostral extent of the commissura posterior. It is ventro-lateral to the superior colliculus and the nucleus of the dorsal commissure. Its cells are rather large and triangular, showing more or less polymorphic characteristics. Its rostro-caudal diameter coincides, as shown in fig. 82, somewhat with that of the nucleus dorso-lateralis.

The identification of the *nucleus of the tractus opticus accessorius* (*n.tr.op.ac.p.*, fig. 33, *a*) is in no way dependent upon the tracing of a spur of the tractus opticus into it. Rather, its cellular structure and topographical position must be relied upon. It lies between the anterior division of the nucleus ruber, and a few cells of the substantia nigra at the level of the corpus mamillare. Its cells are much smaller than those of any of the tegmental group. They slant at about 45° dorso-laterally away from the attachment of the corpus mamillare.

The nucleus supra-opticus (*n.s.op.*, fig. 57) distinguished from the nucleus preopticus lies in the lateral and ventral course of the hypothalamus, just dorsal to the optic tract. Its cells are very large, and resemble those which have been thought to be motor. Other cells quite similar to these may be seen among the fibres of the optic chiasma itself. The writer is inclined to agree with TSAI (1925, *a*) that this nucleus in all probability has nothing whatever to do with tractus opticus and belongs to stria medullaris, because no fibres from the optic tract are seen to enter it, while those of the stria medullaris are gathered up not only from the nucleus preopticus but also more laterally from the region of the nucleus supraopticus. What the similar cells in the optic chiasma may do, cannot be settled, as may be easily seen in fig. 57.

The Pars Ventralis Thalami.

The pars ventralis thalami, or the subthalamus (*subth.*, figs. 2, 5 to 7 and 36) may be divided into four distinct cellular groupings, three of which are definitely marked off by their fibre connections, while the fourth, closely encircled by other areas, appears to have an identity of its own.

The nucleus dorsalis subthalami (*n.d.s.*, figs. 2, 3, 23, 24, 37 to 39 and 58) is a small elliptical nucleus lying near the midline (figs. 23, 31 and 32) slightly ventro-caudal to the commissura mollis or the nucleus reuniens and dorso-caudal to another group of cells within this same general region, the nucleus ventralis subthalami. In transverse section (fig. 23) this nucleus appears as a very small aggregation of cells slightly lateral to the ventricular grey. The shape and size of its cells may be seen in comparison to those of the other subthalamic nuclei in fig. 64, *a*.

The nucleus ventralis subthalami (*n.v.s.*, figs. 3 to 5, 23, 24, 38, 39 and 58) lies more anterior than the dorsal nucleus on the frontier of that expanse of non-differentiated nervous tissue which belongs to the ventricular grey matter of the hypothalamus. It is the most cephalic outpost for the origin of any prominent fibre system connecting this region with the multitudinous highways of the general tegmentum, either of the midbrain or medulla. Its general relation to the other nuclei of the pars ventralis can be seen by reference to fig. 23, where in transverse section the dorsal and ventral cellular masses appear, the one above the other, with the nucleus lateralis magnocellularis subthalami (*n.l.m.s.*, figs. 5 to 7, 23, 24, 40 to 41 and 58) as a broader group of cells with a greater height than those of either the dorsal or the ventral nucleus (*n.v.s.*). The latter nucleus may also be seen in a full-face view in fig. 24. Its profile in sagittal section may be seen in fig. 5. Here it lies dorsal to the undifferentiated portions of the hypothalamus. In the sketch given in fig. 38 it is seen lying posterior to the olfactory fascicle of the stria medullaris and dorsal to the fibres of the postoptic commissure. Its cells are large motor cells, and approach the size of those of the large-celled lateral subthalamic nucleus (see figs. 64, *a*, and 64, *b*).

The nucleus lateralis magnocellularis subthalami (*n.l.m.s.*, figs. 5 to 7, 23, 24, 40 to 41 and 58) lies slightly medial and ventral to the flattened nucleus lateralis subthalami (*n.l.s.*, figs. 23 and 24). In sagittal section (figs. 8 to 10) it is bounded ventrally by the substantia nigra (*s.n.*) and the basis pedunculi (*b.p.*) dorsally and caudally by the nucleus ventro-lateralis thalami (*nuc.v.l.th.*) and anteriorly by the great fibre systems connecting the telencephalon with lower brain stem centres. In transverse section (fig. 58) it is found dorsal and lateral to the ventral subthalamic nucleus and ventro-lateral to the dorsal. Its cells have a greater diameter than those of the lateral and slightly less than those of the ventral (fig. 64, *a*).

The nucleus lateralis subthalami (*n.l.s.*, figs. 8 to 10, 22, 23, 24, 41, 42, 43 and 58) is found lateral to the foregoing nucleus. It is a well-defined group of cells, elliptical in its antero-posterior diameter, flattened medio-laterally, surrounded by vast fibre systems, some of which penetrate it (figs. 23 and 24). It is ventral to the lateral expansion of the pars dorsalis thalami and dorsal to the great descending systems.

The Hypothalamus.

The corpus mamillare (*c.m.*, figs. 2 to 5, 22, 35, 36 and 37) is a single sphere of nervous tissue directed caudalward and attached posteriorly to the diencephalon near the di-mesencephalic border. Besides the customary bilateral symmetry it displays four areas where its various fibre systems make their connections—an anterior, a posterior, a medial and a lateral. The mammillo-peduncular systems leave from the anterior-medial region (figs. 2 to 4); the mammillo-thalamic tract leaves from the dorsal part of the antero-lateral area of the medial nucleus (fig. 6); the fornix enters at the medio-anterior part of the same nucleus; the secondary olfactory connections are made with nucleus lateralis magnocellularis; the short neurones from the surrounding hypothalamus enter the medial nucleus; and those which connect this body with the thalamic centres dorsal to it enter the lateral side of the posterior part (fig. 22).

There are clearly two nuclei here, the medial which is large and contains very large triangular-shaped cells, known as the ganglion mediale by KOELLIKER (1896) or the nucleus medialis by WINKLER (1918). Lateral and ventral to this nucleus there is a thinnish nucleus containing small cells, the older phylogenetic part of the corpus mamillare (KAPPERS, 1921) or the ganglion laterale of KOELLIKER or the nucleus lateralis parvo-cellularis of WINKLER. It is possible to discover in the corner formed by the medial boundary of the basis pedunculi and the lateral boundary of the ganglion laterale a group of cells, very large, known by WINKLER as the nucleus lateralis magno-cellularis.

The tuber cinereum (*t.c.*, figs. 2 to 6, 23 and 35) is an elongated, medio-laterally flattened bit of tissue, which is prolonged caudally to form the nervous part of the hypophysis. Its line of attachment laterally to the side walls of the hypothalamus is accomplished by such narrow strands of thin tissue that the area is usually damaged by the technical manipulation necessary to prepare it for study (see figs. 2, 4 and 23). The author has also called that part of the ventricular grey matter to which this hollow basket is suspended, tuber cinereum (*t.c.*, figs. 3 to 6), as it lies immediately cephalward of the corpus mamillare and receives these fibre systems which one is wont to associate with the tuber cinereum in other mammals.

Besides the corpus mamillare and tuber cinereum so prominent in midsagittal sections (fig. 35), there are vast areas lying dorso-cephalic to them and extending to the anterior commissure and the subthalamus; in these vast areas little nuclear grouping has appeared—the hypothalamus ventralis and medialis (*h.th.vent.*, figs. 58 and 64, *b*, and *h.th.med.*, figs. 57, 58 and 64, *b*). One of these appears in the acute angle made between the diencephalon and the mesencephalon immediately dorsal to the corpus mamillare (*h.th.*, figs. 2 to 4, 23 and 24) and is continuous caudally with the ganglion interpedunculare. It may be regarded as a definite nucleus because it has fibre connections which are distinctly different from that vast area of central grey matter in the hypothalamus.

That vast area, the ventricular cellular accumulations of the hypothalamus surrounded by the subthalamus, the anterior commissure, the postoptic commissure, the tuber cinereum and the corpus mamillare, may be seen in figs. 2 to 6 to form the largest portion of the hypothalamus. It may be divided into two parts—a dorsal, lying on the level with the anterior commissure into which fibres of the postoptic commissure penetrate, and a ventral, that area which surrounds the postoptic commissure and the nucleus of the postoptic commissure. The relative extent of this region will be better understood by examination of figs. 24 and 25. Unfortunately, the fibre tracts which penetrate this region are distributed more or less as a few scattered fibres and therefore do not appear in the photographs.

The Epithalamus.

The habenula.—The only nucleus discovered in this subdivision of the thalamus is the well-known habenula (*hab.*, figs. 3 to 6, 23, 24 and 38). Lateral to midline, the main body of the habenula may be seen lying above the greater extent of the nucleus medialis thalami (*nuc.m.*, fig. 4) and receiving the numerous fibre systems contained in that complex fascicle, the stria medullaris thalami (*str.m.th.*, fig. 4). If the habenula be examined in a sagittal section more lateral to this, it will be seen that only the caudal portion of this nucleus is left (fig. 5). However, when the transverse series is examined (figs. 23 and 24) the habenula exhibits two distinct parts, a lateral (*hab.l.*) and a medial (*hab.m.*). The latter is the long slender arciform portion which curves over the medio-dorsal boundary of the nucleus medialis. The lateral part is confined to the most posterior part of the nucleus and is smaller also in cross section. The commissure appears to originate almost entirely in the lateral nucleus. The cortico-habenular system discharges into the medial nucleus of the habenula (fig. 4) from its dorsal surface. The fasciculus retroflexus or the tractus habenulo-peduncularis leaves *via* the ventral surface from the main portion of the lateral nucleus and perhaps a part from the anterior region of the medial. The tecto-habenular tracts enter the posterior part of the lateral nucleus, while the lateral olfactory systems entering the stria medullaris are distributed with it to the medial nucleus. The medial division of the stria terminalis may be seen to turn dorso-laterally in fig. 25, and to enter the lateral habenular nucleus in fig. 41. In figs. 23 and 24 a few fibres leave the lateral habenula and enter the dorsal part of the lateral expansion of the medial nucleus of the thalamus, constituting what appears to be a habenulo-thalamic system. These two divisions of the habenula so distinct caudally merge into one anteriorly, where the lateral is smaller and seems to be but the lateral part of the habenular nucleus.

The Fibre Systems of the Thalamus.

a. The Epithalamus.

In general the fibre systems of the epithalamus are those which arise in the lower olfactory centres, or in the olfactory cortex to end in the habenula, or those which leave that nucleus to discharge into the motor centres of the tegmentum.

The tractus cortico-habenularis medialis (*tr.c.h.m.*, figs. 4, 24, 38 and 39) leaves the hippocampus, shifting dorso-caudally and partially passing through the dorsal commissure (*c.d.*, fig. 2), turns ventralward, lying dorsal to the anterior commissure, arches over the anterior and lateral nucleus of the thalamus to end in the medial nucleus of the habenula.

The tractus cortico-habenularis lateralis (*tr.c.h.l.*, figs. 3, 26 and 38) may be divided into two divisions, an anterior or direct and a possible posterior or indirect.

(*a*) The anterior or direct tractus cortico-habenularis lateralis arises in the pyriform lobe, the fibres being gathered up from its core, from the nuclei of the lateral olfactory tract and perhaps from the large-celled nucleus of the amygdaloid complex, as thin strands, which turn anteriorly, medially and dorsally until they reach the anterior commissure. Here they swing dorsal to this commissure, join the lateral part of the stria medullaris thalami, and end in the nucleus lateralis of the habenula (*hab.l.*, fig. 23). In this material it is impossible to determine whether or not this direct tract comes from the nucleus of the diagonal band of BROCA.

(*b*) The posterior or indirect division of the tractus cortico-habenularis lateralis contributes fibres to the stria medullaris in two ways. One joins the lateral part of the stria medullaris dorsal to the middle part of the anterior commissure; the other leaves the bed of the stria terminalis at the transverse level of the nucleus reuniens (fig. 23), passes medially and dorsally to the nucleus medialis thalami and ends among the fibres at the ventro-lateral side of the nucleus lateralis of the habenula. It is impossible to know the exact origin of this system because the stria terminalis cannot be unravelled in its centre in such a manner that any distinction can be made in the intrinsic connections of its two ends.

The tractus olfacto-habenularis lateralis (*tr.o.h.l.*, fig. 38) arises from that part of the area subcommissuralis* which lies anterior to the optic chiasma. It turns caudalward

---

* The descriptive term "area subcommissuralis" as introduced by the writer and employed throughout this paper is not to be confused with the "area præcommissuralis" of ELLIOT SMITH to which it does not correspond. Its position is homologous to that of the anterior perforated space in other mammals studied, but otherwise it shows little similarity to the latter (*cf.* pp. 156 and 157, footnote).

and dorsalward around the caudal limit of the commissura anterior to join the lateral part of the stria medullaris thalami, to enter the lateral nucleus of the habenula.

The tractus olfacto-habenularis medialis (*tr.o.h.m.*, fig. 40) arises posterior to the previous tract, anterior to the optic chiasma and ventral to the anterior commissure, near the midline, possibly from the nucleus preopticus, swings caudo-dorsalward to join the medial cortico-habenular tract (fig. 26).

The habenular commissure (*c.h.*, fig. 23) appears to connect only the two nuclei laterales ; it is impossible in this material to find any fibres contributed by the medial division of the habenula.

The tractus tecto-habenularis already described under the midbrain enters the habenula in the extreme caudal portion of its lateral division.

The fasciculus retroflexus (*f.r.*, figs. 5, 21, 38, and 40), or the tractus habenulo-peduncularis, leaves the ventral part of the lateral nucleus of the habenula, plunges into the tegmentum posterior to the nucleus medialis thalami, passes anterior to the nucleus ruber and posterior to the corpus mamillare to end in the anterior part of the ganglion interpedunculare.

Tractus habenulo-thalamicus (*tr.h.th.*, fig. 23) is a diffuse group of fibres which find their exit from the ventral and lateral surfaces of the lateral nucleus of the ganglion habenulare to the dorsal and lateral part of the posterior part of the nucleus medialis thalami.

b. The Hypothalamus.

The fibre connections of the corpus mamillare relate it to the secondary olfactory centres, the habenula, the hippocampus, the nucleus anterior thalami, the nuclei dorsale and ventrale tegmenti and the general tegmentum of the lower brain stem.

The tractus cortico-mamillaris or fornix (*for.*, figs. 2 to 5 ; 25, 26, 38 and 39) appears in sagittal section as a discrete band of fibres lying ventral to the stria medullaris group as this passes dorsal to the anterior commissure. From this point the tractus curves ventro-caudally, medial and ventral to the tractus mamillo-thalamicus, decussates dorsal to the corpus mamillare and enters the antero-lateral part of the corpus mamillare, to end in its ganglion laterale or the nucleus lateralis parvocellularis.

The tractus mamillo-thalamicus (*tr.m.th.*, figs. 6, 22 to 24, 37, and 40) emerges from the caudo-lateral part of the mammillary body, the nucleus medialis (fig. 6) or the ganglion medialis of KOELLIKER, and passes dorsally. Curving dorsalward, the tractus turns cephalward to lie along the ventral limit of the medial nucleus of the thalamus, where it changes its direction to one dorso-lateral and ends in the anterior part of the nucleus anterior thalami.

The tractus olfacto-mamillaris (*tr.o.m.*, figs. 40 and 41) is made up for the most part of scattered fibres originating in the area subcommissuralis or the tuberculum olfactorium. These fibres lie in the ventricular grey matter near the midline and pass caudalward, dorsal to the postoptic commissure and medial to the fornix and the tractus mamillo-thalamicus, and enter the corpus mamillare laterally to a termination in the nucleus lateralis magnocellularis of that body.

The tractus mamillo-peduncularis dorsalis (*tr.m.p.d.*, figs. 3, 36 and 37) may be followed from the more caudal part of the corpus mamillare anteriorly where it emerges from the nucleus medialis of that body ; turning abruptly dorsalward, part, at least, of its fibres cross in the decussation of the corpus mamillare (*d.c.m.*, figs. 2 and 22), changing the direction to one dorso-caudal. These fibres lie ventral to the fasciculus longitudinalis medialis in the midbrain and anterior part of the medulla. The tractus sends some fibres into the nucleus dorsalis tegmenti and loses itself as one of the fibre systems of the formatio reticularis. Fibres from the nucleus subthalami also join this system, constituting the fasciculus dorsalis tegmenti of GUDDEN.

The tractus mamillo-peduncularis ventralis (*tr.m.p.v.*, figs. 5 and 38) is a part of the tractus hypothalamico-peduncularis, for it is joined immediately under the lateral surface of the mammillary body by fibres which have come from the tuber cinereum. The whole bundle of fibres then passes dorso-caudally into the central part of the mesencephalic tegmentum, lateral to the nucleus ruber. The tractus appears to originate in the nucleus lateralis magnocellularis of the corpus mamillare.

The tuber cinereum (*t.c.*, figs. 3 to 6 ; 23, 24 ; 35 to 39 and 58).—The tractus olfacto-mamillaris sends some of its fibres into the tuber cinereum. The tractus mamillo-peduncularis receives contributions from this area. The area subcommissuralis and the nucleus preopticus, as well as the dorsal and ventral subthalamic nuclei, are connected with the tuber cinereum.

The ventricular grey matter.—Three systems discharge into the ventricular grey matter, the tractus olfacto-hypothalamicus (*tr.o.h.th.*, fig. 37), coming from the subcommissural region and ending in the more ventral part ; the second, from the primary olfactory centre, at the base of the bulb, following the outline of the brain ventral to the tuberculum olfactorium or beginning in the tuberculum itself, thus forming a combined tractus tuberculo-olfacto-hypothalamicus (*tr.t.o.h.th.*, fig. 35) ; and lastly, one from the corpus striatum which passes dorsal to the anterior commissure. In all probability all of the subthalamic nuclei connect with it, but only fibres from the nucleus ventralis and the nucleus lateralis magnocellularis could be followed.

The Commissures.

Ganser's or the postoptic commissure (Decussatio subthalamica anterior Ganser) (*c.p.o.*, figs. 2 to 6, and 35 to 39) lies immediately ventral to the third ventricle and slightly caudal to the optic chiasma. Its fibres ascend diagonally dorso-laterally into the medial region of the hypothalamus. Its exact termination is unknown, although some of the fibres reach the area known as the nucleus ventralis subthalami. Other fibres of this commissure cannot be traced further than to the cells which compose the ventricular grey matter. This is perhaps the commissura infundibularis anterior of FOREL's description or the commissura hypothalamica anterior of KOELLIKER, and is homologous, perhaps, with the decussatio hypothalamica posterior described for amphibians by HERRICK and for the alligator by CROSBY.

Meynert's or the supra-optic commissure (*f.c.M.*, figs. 37 and 38) lies between the optic chiasma and that of Ganser. It is compossed of lightly myelinated fibres. They pass dorso-lateralward, medial to the optic tract, and in transverse section at the horizontal level where the tract turns more laterally, the fibres of MEYNERT'S commissure turn medialward, and are lost among the cells of the nucleus lateralis magnocellularis subthalami. However, in longitudinal section, a few fibres appear to penetrate the nucleus lateralis subthalami. MARBURG thinks that this fibre bundle is the tractus striatico-hypothalamicus cruciatus, and that it binds the globus pallidus, of one side with the corpus Luysii of the other. RIESE (1924) found the same longitudinal fibre system in an eight-month human fœtus. In this material, however, there is no available evidence for its decussation-function. Further, for this commissure to be completely homologous with the descriptions of higher mammals studied (such as rabbit, cat and man) the majority of the fibres of this commissure would be expected to proceed to the nucleus lateralis subthalami.

Gudden's commissure lies ventral to the optic tract and optic chiasma, and ascends with the tract—thus becoming so intermingled with its fibres that it may well proceed to the medial geniculate body, as the optic tract itself turns in a semicircle about that nucleus to send fibres into the ventral portion of the lateral geniculate, which lies dorsal and slightly medial to it.

The decussatio columnarum fornicis (*d.c.m.*, fig. 22), forming the bulk of the decussation of the corpus mamillare, lies just dorso-caudal to that body. It is not certain whether or not all the fibres of the fornix decussate. Some fibres of the tractus mamillo-peduncularis dorsalis also cross in it.

The commissure of the thalamus (*c.th.*, fig. 24) lies in what might be called the commissura mollis, immediately ventral to the nucleus reuniens and dorsal to the third ventricle. The commissure of the thalamus continues laterally, dividing the pars dorsalis thalami from the pars ventralis. At the extreme lateral border of the thalamus it may be seen (in the Bielschowsky series) to swing in circular fashion into the ventro-medial extension of the corpus striatum. The commissure may connect the two amygdalæ laterales, the two ventral parts of the putamen and the tails of the caudate nuclei with each other. Part of the fibres seem to turn a little more medially, and to enter an area quite filled with horizontal fibres, the most caudal limb of the globus pallidus.

The Pars Ventralis Thalami or Subthalamus.

The fibre systems of the pars ventralis are so intimately related with the nearby areas of the brain that their specific tracts have been described elsewhere (pp. 178-180), but the following fibre connections of the subthalamic nuclei may be noted.

The nucleus dorsalis subthalami (*n.d.s.*, figs. 3, 37 to 39 and 58) contributes fibres to the fasciculus longitudinalis medialis (particularly to its more caudal part), and is connected with the midbrain *via* the tractus tecto-subthalamicus and the tractus tegmento-subthalamicus. Further, it is closely linked with the cell-mass just anterior and ventral to it, the *nucleus ventralis subthalami* (*n.v.s.*, figs. 3 to 5, 38 and 58). This nucleus sends fibres into the peduncle and has connections with the striatum by the tractus strio-subthalamicus. Fibres connect it with the nuclei amygdalæ medialis and basalis, and perhaps with the pyriform cortex, *via* the direct olfactory projection tract.

The nucleus lateralis magnocellularis subthalami (*n.l.m.s.*, figs. 5 to 7, 23 and 24) appears to receive fibres from the commissure of MEYNERT (*f.c.M.*, fig. 42), and is connected with the midbrain by means of the fasciculus longitudinalis medialis. The nucleus sends fibres into the peduncle *via* the tractus subthalamico-peduncularis (*tr. s.p.*, fig. 41).

The nucleus lateralis subthalami (*n.l.s.*, figs. 8 to 10, 22 to 24, 42 and 43) is connected with the midbrain *via* the tractus tecto-subthalamicus. Fibres of the striato-subthalamic system enter this nucleus coming from the more lateral portion of the head of the striatum; they pass directly caudalward, ventral to the lateral arms of the commissura anterior, become interspersed with the fibres of the optic tract, and then turn laterally and dorsally to this nucleus. This is probably similar to the ansa peduncularis. Also, fibres which appear to originate in the dorso-lateral part of the striatum pass caudally and dorsally to the commissure, anterior to this nucleus. Among the fibres of the direct olfactory projection tract ending in this nucleus, and the larger one medial to it, are fibres which come from the globus pallidus, thus constituting a typical ansa peduncularis system. This nucleus also receives fibres from the tractus opticus anterior.

The Pars Dorsalis Thalami.

The nucleus anterior thalami (*n.a.*, figs. 6, 7, 25, 26 and 57) receives the enormous system, the tractus mamillo-thalamicus (figs. 6 and 23) which was described at length under the fibre systems of the corpus mamillare. The tractus thalamo-striaticus and striato-thalamicus cannot in this material be separated at any point where they may enter or leave either this nucleus or its neighbour, the medial. This system, found in the dorso-medial region of the head of the striatum, lies dorsal to the anterior commissure and is lost in the ventro-anterior part of the nucleus anterior. Another tract which is found in the ventro-medial area of the striatal head, passes ventral to the anterior commissure and gives off collaterals to nucleus ventralis subthalami. From the area subcommissuralis arises a tractus olfacto-thalamicus which ascends with the septo-thalamic system.

The nucleus medialis (*nuc.m.*, figs. 2 to 7, 25, 26, 35, 55 and 57 to 58) is connected with the striatum and the secondary medial olfactory centres by the striato-thalamus system and the tractus olfacto-thalamicus in the same manner as the nucleus anterior; it is related to the midbrain by the tractus tecto-thalamicus and tegmento-thalamicus.

Further, it is linked with nucleus ventralis subthalami and the central grey matter of the hypothalamus.

The nucleus reuniens has yielded to close scrutiny no definable fibre relationships.

The lateral group of thalamic nuclei, previously described as the nucleus dorso-lateralis, the nucleus medio-lateralis and the nucleus ventro-lateralis are distinguished by their particular fibre connections. The last of these receives the lemniscus systems which can be distinguished anatomically. The trigeminal lemniscus (*lem.t.*, fig. 5) is found anterior and medial in the nucleus, approximately in that region where the medial begins to expand laterally, the nucleus spongioides of KAPPERS. The medial lemniscus (*lem.m.*, figs. 10 and 20) enters this nucleus ventrally and turns caudally so that it terminates in its ventro-posterior part, which has been labelled with the same name by ZIEHEN. Undoubtedly there are cortical connections, for certainly fibres pierce its lateral boundary, pass through the putamen and enter the cortex. Their exact origin, termination, and the question of a possible synapse in the putamen cannot be known.

The medio-lateral nucleus as well as its neighbour, the nucleus dorso-lateralis (*nuc.m.l.th.*, figs. 22 and 59) is distinguished by connections with the tectum. In all probability both have fibre relations with nearby nuclei, such as the nucleus pretectalis. It is clear that such scantiness of known fibre relationships makes it impossible to suggest further homologies, except to point out that the portion of the medial or ventro-lateral nucleus which receives the trigeminal lemniscus resembles in part the "centre médian," the ventro-lateral, appears much like the nucleus ventralis, while the dorso-lateral and medilo-lateral nuclei occupy the region where the lateral nucleus is generally discovered.

The medial geniculate body (figs. 9 and 10) has typical fibre connections with the lateral lemniscus and the inferior colliculus. Fibres also arise in the body which swing dorso-laterally toward the cortex, then as they pass through the lateral fibres of the anterior commissure, they curve ventrally and are lost in the cortex, forming the auditory radiations.

The optic tracts.—The optic nerve (*n.op.*, figs. 26 and 36) appears to decussate completely (*c.o.*, fig. 3). The optic tract (*tr.op.*, fig. 41) lies on the ventral surface, directly beneath the anterior commissure. It runs dorso-caudally over the lateral border of the diencephalon; its fibres lie medial to those of the medial division of the stria terminalis at the level of the tuber cinereum. Many small fascicles leave the medial side of the tractus opticus and pierce the bundles of the basis pedunculi. Some of them may end among the cells of the ventral border of the elongated nucleus lateralis subthalami. A small strand continues dorso-laterally, lying medial to the various loose fibres, and becomes identified with the lateral division of the stria terminalis. This strand swings about the lateral boundary of the basis pedunculi; on division it turns medially and courses into the lateral subthalamic nuclei, running in a ventro-medial direction, terminating for the most part in the nucleus lateralis. This is the tractus opticus accessorius anterior, described by BOCHENEK. The lateral division or tractus opticus proper turns at right angles and runs rostrally from this region to that of the medial geniculate body, where it swings into a nucleus dorsal to the medial geniculate body: this dorsal cell-aggregation seems therefore to be the ventral lateral geniculate body.

The writer has not been able to identify the fibres belonging to the commissure of GUDDEN, which would be expected to leave the outer border of the tractus opticus at this level. The writer has also failed completely to identify any other tracts belonging to the optic system. No fibre connections were followed into the dorsal nucleus, which has been labelled the dorsal lateral geniculate body, nor were any fibres seen that might be construed as those of the tractus opticus accessorius posterior, although a nucleus identified by the type of its cells and by its position dorso-lateral to the corpus mamillare and medio-ventral to the substantia nigra was called tentatively that of this tract (p. 186).

The nucleus which has been labelled the dorsal lateral geniculate body, receives fibres from the two more superficial fibre layers of the anterior quadrigeminal body.

The nucleus pretectalis receives what has been called the tractus tecto-pretectalis from the second fibre layer—the stratum medullare superficiale of the superior colliculus. The nucleus appears to receive fibres from the tractus tecto-thalamicus medialis and the tractus tegmento-thalamicus. Short fibre connections exist between this nucleus and the habenula, the nucleus dorsalis of the lateral geniculate body, and the central grey within the region of the posterior commissure, called by RIESE the nucleus ellipticus. It also appears to be connected with the tegmentum ventral to it, with the nucleus interstitialis, and finally with the three nuclei of the lateral groups, particularly the nucleus ventro-lateralis.

The Corpus Striatum.

In the brains of the fœtal Ornithorhynchus, such as of those belonging to Prof. WILSON, the "mammary fœtus" "X" (fig. 89) and that of Delta (fig. 88), the basal nuclei of the telencephalon fall easily into three divisions, the nucleus caudatus (*n.c.*), the nucleus lentiformis (*nuc.l.*) and the nucleus amygdalæ (*n.a.l.*, *n.a.b.*, and *n.a.cort.*, fig. 88, *b*). The nucleus caudatus forms the floor of the lateral ventricle. Its heavily staining embryonic nerve cells are arranged in thick, straight rows, abutting against the ependyma. Ventral to this differentiation lie a few fibres, constituting the internal capsule. The major portion of the basal mass, however, ventral to the internal capsule and medial to the external capsular fibres, with its cells arranged amorphously, forms the nucleus lentiformis.

Within the pallium, differentiation of cellular layers is such that the hippocampal and pyriform formations may be accurately delimited. The layers of the remainder of the cortex are marked by the unusual thickness of the intermediate layer (HINES, 1922). The cessation of the intermediate layers and the sweep of fibres from the external capsule in the ventro-lateral pole of the hemisphere form the lateral limit to the insignificant cortical differentiation of the pyriform. At certain levels this change in cortical lamination is accompanied by a shallow groove in the brain wall; at others it is felt rather than seen—the fissura rhinalis (*f.rh*). In the outer cell-free layer immediately medial to the pyriform cortex, a few fibres of the lateral olfactory tract appear, and mark the medial limit of the palæo-cortex. Between this region, the medial wall of the ventromedial pole of the hemisphere, and the ventral boundary of the nucleus lentiformis, is the amygdala (fig. 88, *b*, and fig. 89, *b*, *c*). This delimited region may be followed in the figures in question, both rostrally and caudally. Rostrally its differentiation gives way to that characteristic of the subcortical lateral olfactory centres; caudally its intrinsic differentiation fades and it comes to lie in the medio-ventral angle of the telencephalic vesicle, bounded by the hippocampal formation dorso-medially and by the pyriform latero-ventrally (fig. 88, *c*).

In the same manner, the head of the caudate nucleus in the fœtal brains may be quite easily separated from the putamen and globus pallidus of the nucleus lentiformis. In the adult, however, these simple morphological relationships are so transformed that the line of division between lentiform and caudate is difficult to draw. The middle portion of the striatum lies in a thin crescent-like shell about the lateral nucleus of the thalamus (figs. 20, 21 and 22). Rostralward it becomes confluent ventro-medially with the nucleus accumbens (*n.a.K.*, figs. 27 and 28) and ventro-laterally with the tuberculum olfactorium. The dorso-medial boundary contains the stria terminalis (see figs. 9, 10, 20, 21 and 22) which, interrupted by the two nuclei of the stria terminalis (*nuc. str.t.*, figs. 9 and 10) lying dorso-caudal to the thalamus, curves ventro-anteriorly to end in the nuclei of the amygdaloid complex.

In the corpus striatum of Eutheria, the internal capsule has been used as the line of division between the nucleus caudatus and nucleus lentiformis. However, if the cells characteristic of these two nuclei constitute a definite criterion for their limits, the nucleus caudatus of Ornithorhynchus is not bounded by the internal capsule. In fig. 56, a small tongue of caudate cells is seen to descend to the region of the external capsule lying between the putamen laterally and the globus pallidus (*g.p.*). Dorso-medial to the globus pallidus the lateral division of the nucleus caudatus meets a medial, the former being characterised by large triangular and pyramidal cells, and the latter by those of a small granular variety, the bed nucleus of the stria terminalis. At this particular level the bed nucleus turns ventro-medially, where it terminates immediately dorsal to a prominent large-celled squarish nucleus, resembling in its cellular content those lying ventral to the anterior commissure in the medial part of the area. The writer has called this cell mass the nucleus adjacens commissuræ anterioris (*n.a.c.a.*, fig. 56).

The nucleus caudatus (*n.c.*, figs. 7, 9, 10, 22 to 27, 34, 42, 45, 49, 56, 57 and 59) characterised by larger pyramidal and triangularly shaped cells (*n.c.*, fig. 63*c*) lies as a thin cap over the half-moon shaped putamen, lateral to the nucleus of stria terminalis. It maintains this same position until the ventral pole is reached. At that point a few cells turn ventralward and then rostralward, forming a thin connecting link with cells which in the more rostral levels of the brain (fig. 58) are found lateral or latero-ventral to the nucleus amygdalæ lateralis. Anterior to the globus pallidus and the anterior commissure the fronto-ventral boundary of the caudate runs into the nucleus accumbens and touches the medial boundary of the putamen. Consequently, the gross morphology of the nucleus caudatus resembles that characteristic of mammals.

The nucleus of the bed of the stria terminalis (*n.b.str.t.*, figs. 45, 55 and 56) can be identified in its most rostral position dorsal to the nucleus of the anterior commissure, associated with the anterior dispersal of the concentrated stria terminalis fibres. No definite continuity can be established between it and the "septal" nuclei (in ELLIOT SMITH'S paraterminal body). Ventro-rostrally the bed nucleus expands into the medial group of the amygdaloid complex. Posteriorly, at that point where the arc formed by these fibres takes a quick change of direction from one dorso-caudally to one ventrally, these fibres are interrupted by two nuclei, which I have called those of the stria terminalis. The cellular make-up of these two discrete groups, as seen in the Bielschowsky preparation, varies in no way from that characteristic of the bed nucleus. Such a finding suggests that the peculiarity of these nuclei may lie not so much in their existence as such, but rather in a concentration of cells of the bed nucleus to form them. The bed nucleus may not merely consist of the cells around the fibres of the stria terminalis but may possibly also represent synaptic stations in its pathway (although not suggested by JOHNSTON, 1923).

In the medial part of the nucleus caudatus, at its extreme dorso-caudal boundary and therefore far posterior to the caudal extent of the bed nucleus of the stria terminalis, two discrete nuclei are found. They have been identified in all the sagittal and transverse Weigert series and also in the Bielschowsky preparations. In the Weigert series they are characterised by fibres which connect them with the nucleus amygdalæ lateralis and dorsally with the nucleus caudatus. In the Bielschowsky series, these discrete nuclei are dark brown islands in a field of yellow, and their cells are pyramidal and triangular shaped. Their fibre connections place them with the stria terminalis division of the nucleus caudatus. They are called the *nuclei of the corpus striatum* (*nuc.c.str.*, figs. 19, 45 and 65).

The nucleus lentiformis (*nuc.l.*, figs. 7 to 9, 10, 18 to 20, 23, 27, 28, 45, 48, 50 and 56) is made up of two parts in this brain, the putamen and the single medial body, the globus pallidus. The putamen forms the arc of striatal tissue which bounds the lateral limit of the thalamus. It touches the globus pallidus ventro-medially in the region of the anterior commissure; but immediately posterior to the commissure its ventro-medial margin comes into contact with the lateral nucleus of the amygdaloid complex, with the nucleus caudatus, and dorsally with a few cells of the globus pallidus. Dorsally, it is always capped by the nucleus caudatus. The cells of the putamen (*put.*, fig. 63, *c*) are smaller than those of the nucleus caudatus. They are triangular, pyramidal and polymorphous in shape.

The globus pallidus (*g.p.*, figs. 10, 23, 24, 34, 43, 56 to 58 and 63, *c*) lies hidden in the medio-ventral division of the dense fibre bundles of the lateral forebrain bundle (*g.p.*, figs. 56, 57). Its greatest bulk is found dorsal to the anterior commissure. It sends laterally and posteriorly a smallish tail of cells, which lies beneath the ventral boundary of the lateral nucleus of the subthalamus and dorsal to the ventro-medial arc of the putamen. Its cells are by far the largest and show the longest processes of all those found in the corpus striatum, and they are more sparsely spaced, separated by thick, heavily myelinated fibres of the strio-fugal system (figs. 56 to 58). These cells are for the most part polymorphous. They may be distinguished from the somewhat similar cells of the pyriform and the hippocampus, by their singularly long processes visible in the Bielschowsky series (fig. 63, *c*). Among them are a few triangular trapezoidal-shaped cells, probably the cell bodies of internuncial neurones.

Following the bed nucleus of the stria terminalis (*n.b.str.t.*) ventro-anteriorly, or the lateral olfactory tract posteriorly, the amygdaloid complex appears. As in many other mammals so far studied, it is divisible into five discrete nuclei, named for their relative positions in the nomenclature of Johnston's 1923 analysis. The complex as a whole may be divided into two groups, a medial and a lateral. The medial group contains the nucleus medialis (*n.a.m.*), the nucleus centralis (*n.a.c.*), and the nucleus corticalis (*n.a.cort.*). The lateral group, the nucleus basalis (*n.a.b.*), and the nucleus lateralis (*n.a.l.*). No true accessory basal nucleus, described for the opossum by both JOHNSTON (1923) and VAN DER SPRENKEL (1926), was identified in Platypus, although upon a basis of a variation in cellular types, the basal nucleus might be sub-divided. It was thought, however, that the result would be but a considerable increase in the confusion caused by nomenclature, because the material did not yield a difference in the fibre connections of the two parts nor a correspondence in any way to the accessory basal nucleus of other descriptions.

The lateral boundary of the complex, separating it from the pyriform cortex, has been set by JOHNSTON as the fissura amygdalæ, whether that separation is marked by a shallow groove in the outer brain wall or by a ripple in the regularity of cellular spacing within. Furthermore, this fissure was described as being continuous caudally with the endorhinal fissure—the appearance of the nucleus amygdalæ medialis and the disappearance of the nucleus of the lateral olfactory tract marking this transformation. In Ornithorhynchus, this continuity is not quite as clear as in the opossum, due in part to the poor differentiation of the olfactory areas, of the nucleus of the diagonal band of BROCA (*n.d.b.B.*, figs. 26 and 54), and of the nucleus of the olfactory tract (*n.t.o.l.*, figs. 25, 51 and 57) and to certain peculiarities of the relation of the fissure endorhinalis to the sulcus hemisphæricus.

In the region of the anterior olfactory nucleus (*n.o.a.*, figs. 29 and 30) no endorhinal fissure separates that area from the medial olfactory centres. Passing caudally, however, the fissure then marks the boundary between the tuberculum olfactorium and pyriform lobe. But in the anterior levels of the anterior commissure (*f.e.rh.*, figs. 25, 26, 54 and 55) the sulcus marks the dividing groove between the area subcommissuralis and the pyriform. In these three regions the fissura endorhinalis (*f.e.rh.*) and the sulcus hemisphæricus are the same. However, in the more posterior part of the area subcommissuralis (figs. 57 and 58) they are not superimposed, for the endorhinal fissure separates the pyriform from the nucleus of the lateral olfactory tract, while the sulcus hemisphæricus (*d.t.gr.*, figs. 57 and 58) delimits that nucleus from the diencephalon. The fissura endorhinalis stops abruptly as a surface groove some millimetres rostral to the appearance of another, the fissura amygdalæ (*f.am.*, fig. 34), which marks the lateral limits of the posterior division of the cortical nucleus of the amygdala (*n.a.cort.*, fig. 34). In the anterior division of that nucleus, the cellular lamination of these areas is separated by an abrupt change in their direction. This peculiar cellular arrangement was found in the medial wall of the pyriform lobe, as it runs beside the area subcommissuralis ; when followed caudally the two regions are instinctively identified antero-posteriorly as continuous. This is the site of the amygdaloid boundary (*b.am.*, figs. 24 and 58) or JOHNSTON'S fissura amygdalæ. A similar change in direction of cortical lamination may be found in the ventro-medial angle of the middle third of the pyriform, marking the boundary between the medial and ventral zones, but this directional alteration has never received any assignment of significance.

The amygdala is then separated from the pyriform rostrally by a band of fibres, the lateral olfactory tract, and by an internal change in direction of the outer cell laminations, labelled the boundary of the amygdalæ, and more caudally by a real sulcus in the wall, the fissura amygdalæ (*f.am.*, figs. 34, 49, 51, 62 and 66). The first separates the nucleus medialis and the anterior part of the cortical nucleus from the pyriform, while it is the second which delimits the more regular lamination of the caudal division of the cortical nucleus of the amygdala from the pyriform lobe.

The medial nucleus of the amygdala (*n.a.m.*, figs. 8, 24, 34, 45, 48, 58, 59 and 66) lies posterior to the nucleus of the lateral olfactory tract at the transverse level of the anterior part of the hypothalamus—the region of the optic chiasma. Passing caudally it takes its position between the nucleus corticalis and the nucleus centralis, or perhaps the medial bundle of the stria terminalis. It is made up for the most part of polymorphous cells and a few triangular ones. It appears to be connected with the lateral olfactory tract, the longitudinal bundle ventrally, and the medial division of the stria terminalis (the band which turns into the lateral part of the stria medullaris), as well as with the hypothalamus and subthalamus by a direct tract.

The central nucleus of the amygdala (*n.a.c.*, figs. 9, 10, 20 to 24, 34, 45, 58 and 65) is found ventral to the basis pedunculi, dorsal and lateral to the medial nucleus, dorsal to the basal, and medial to the lateral and to the posterior part of the globus pallidus. In the midst of its slender branching pyramidal cells and polymorphous cells, one or two islands of large cells appear, similar to those nuclei found ventral to the anterior commissure—the nuclei of the area subcommissuralis (*n.a.s.*, figs. 26, 54 and 57). In the Bielschowsky series the cells themselves are very dark brown, almost black, closely packed together in a neuropile, staining a deep rich brown. These cells appear to be polymorphous for the ratio of the base-apex measurement of the cell to that of its base approaches one, although they do not have the form of typical polymorphous, pyramidal or granular cells. In all probability this nucleus is connected with both medial and lateral divisions of the stria terminalis.

The cortical nucleus of the amygdala (*n.a.cort.*, figs. 9, 20, 22, 34, 48 to 50, 58, 59, 65 and 66) is divided in two definite parts—a rostral and a caudal division—the nucleus amygdalæ corticalis anterior and posterior. The anterior division lies lateral to the amygdaloid boundary (*n.a.cort.*, fig. 58) and the posterior, lateral to the fissura amygdalæ (*n.a.cort.*, fig. 34). The former is characterised by small, irregular cell-laminations, principally pyramids ; the latter, by larger pyramids and some polymorphous cells arranged rather regularly in rows. In the more caudal reaches of this system (fig. 62) where the fissura amygdalæ is not as prominent as when it accompanies the medial division of the lobus pyriformis, the definitions of the laminated pyramids are disturbed. All but the most posterior region of the cortical nucleus is probably reached by the medial part of the stria terminalis and the longitudinal bundle. Just what the connections of the caudal division are, the writer cannot tell.

The lateral amygdaloid nucleus (*n.a.l.*, figs. 9, 10, 19, 21, 23 to 25, 34, 45, 48, 50, 51, 57, 58, 65 and 67) lies in the hooked arm of the external capsule, bounded laterally by the nucleus caudatus and the putamen, and limited dorsally or dorso-medially by the central nucleus or the basis pedunculi. Its cells are deeply stained with the silver in the Bielschowsky series. They are large motor-like cells pyramidal in shape, yet lacking the slenderness of the true pyramidal type. They are not typically polymorphous as judged by the character test of those found in the globus pallidus, but they resemble more closely than anything else those characteristic of the fifth layer of the cortex. This nucleus is connected with the lateral part of the stria terminalis, the indirect olfactory projection tract of RAMON Y CAJAL and the two nuclei of the corpus striatum.

The nucleus amygdalæ basalis (*n.a.b.*, figs. 9, 10, 20 to 23, 34, 43, 45, 48, 50, 57, 58, 65 and 67) is found surrounded on its medial and dorsal boundaries by the nuclei of the medial group (the cortical, the medial, and the central) ; on the lateral limits by the lateral nucleus, the medial stub of the external capsule, and the cut lamination of the lateral zone of the pyriform cortex. The cortices of the amygdala and the pyriform lie between this cell mass and the ventral surface of the hemisphere. Probably a few cells of this nucleus might be found at the level of the anterior reaches of the amygdaloid boundary line, where otherwise the medial nucleus only is found. But in the regions of the cortical nucleus the basal nucleus comes into sight as a cell-aggregation made up in large part of enormous cells, trapezoidal in shape, running more or less parallel to the outer contours of the hemisphere. The more caudal reaches of the pyriform lobe are separated by the fibres of the pyriform neocortical association bundle, and the fibres of the longitudinal bundle.

The nuclei of the stria terminalis (*nuc.str.t.*, figs. 8 to 10, 20, 21 and 82).—These nuclei, so named because they interrupt some of the fibres of the stria terminalis on its way to the various nuclei of the amygdaloid complex, are found near the posterior border of the thalamus lying snugly between the nucleus ventro-lateralis thalami (*nuc.v.l.th.*, fig. 20) and the external boundary of the anterior part of the superior colliculus. In fig. 21, twenty sections cephalward of the previous level, it appears as a very small nucleus wedged in between those two bodies. Its extent is best pictured in figs. 8 to 10, where it lies posterior to the dorsal-lateral geniculate body (*l.g.b.d.*, figs. 9 and 10) and dorsal to the ventro-caudal division of the nucleus ventro-lateralis thalami (*nuc.v.l.th.*).

The Fibre Systems.

A. Non-Olfactory.

The non-olfactory systems are the striato-thalamic connections described in the chapter on the thalamus as the lateral forebrain bundle. There are two types of connections—those with the sub-thalamus, the hypothalamus and the midbrain, and those with the anterior and medial nuclei of the thalamus. If the direction of conduction be similar to that which holds for higher mammals, the former division will contain descending fibres and the latter, ascending.

The tractus striato-subthalamicus et mesencephalicus (*tr.str.s.et m.*, fig. 43) connects the globus pallidus with nucleus lateralis subthalami. The tractus passes caudally in the lateral part of the thalamus, in the region which lies midway between the subthalamus and hypothalamus, lateral to the nucleus ventralis subthalami. In its pathway, large polymorphous cells may be seen, particularly at the level of the optic commissure. It can then be followed into the nucleus lateralis magnocellularis subthalami similar to DEJERINE'S (1901) "faisceau thalamique de Forel." It may be followed further caudally into the tegmentum of the mesencephalon. In sagittal section the tractus appears to contribute fibres to the antero-lateral part of the nucleus ruber and probably also to the substantia nigra, forming DEJERINE'S (1901) ansa peduncularis of GRATIOLET.

In a more caudal region another part of the same system leaves the dorsal part of the most posterior region of the globus pallidus, interdigitating with the main fibre bundles of the lateral part of the basis pedunculi; then turning laterally and ventrally, it spreads out in the nucleus lateralis subthalami. Some of the fibres reach the nucleus lateralis magnocellularis subthalami. This part of the pallido-subthalamic connections in all probability is homologous to the ansa lenticularis.

Besides these fibres, there are others which arrive from the globus pallidus (*g.p.*, figs. 23 and 24) and join the indirect projection tract of CAJAL (*tr.o.p.C.*), to end with it in the nucleus lateralis subthalami, and perhaps in the nucleus lateralis magnocellularis subthalami.

The tractus thalamo-striaticus (*tr.th.str.*, fig. 42) leaves the lateral part of the nuclei medialis et anterior, swings ventralward, and then turning abruptly dorsalward, enters the lateral aspect of the nucleus caudatus. Some of these fibres appear to end in the caudal part of the nucleus caudatus, others pass ventral to these and forward, to end in the rostral part. This is indeed a part of the lateral forebrain bundle.

Besides these fibres, the writer has been puzzled by others which may be seen, in the extreme lateral sagittal section, to pass from the ventro-anterior part of the striatal complex, dorsal to the nucleus accumbens, from what topographically ought to be the anterior limb of putamen. These fibres progress dorsal to the nucleus accumbens and the tuberculum olfactorium, ventral to the external capsule, and just dorsal to the nucleus of the subcommissural area, and swing dorsally just posterior to the external capsule to join the fibres described as the tractus thalamo-striaticus. SACHS' degeneration experiments on cats, and KINNIER WILSON'S on the monkey, throw considerable doubt upon the correctness of this observation, but the older studies of DEJERINE, although they are on man, support it—feeble crutch though they be. The course of these fibres is somewhat similar to the septo-thalamic connections, which are made with the nuclei medialis and anterior, although they are found distinctly more medially. The fibres in question may be seen in transverse section to lie in the substance of the putamen, at its rostral extremity. Further, some of the fibres belonging to the circumscribed tractus thalamo-striatus, may be seen to pass to this same region. It is impossible to know whether or not the region in question is putamen or head of the caudate. The only identification is that made by position. The Bielschowsky series stops short of this region, so that cell-types cannot be used.

It is also within the realm of possibility that fibres leaving the lateral border of the lateral thalamic complex, do not pass through the putamen without synapse. Many of them fray off, as is the wont of fibres when they are approaching a nucleus of termination.

B. The Olfactory fibre systems.

The stria terminalis (*str.t.*, figs. 38, 39 and 40) may be divided into a lateral and a medial division. The fibres of the latter are closely packed; of the former, quite loosely so that some individual fibres may be identified within it.

The medial division (*str.t.m.*, 21, 26, 27, 34 and 42) can be followed from sections at the transverse level of the optic tract, where its fibres fray out laterally into the nucleus medialis of the amygdala or penetrate the outer cellular layers of the cortical nucleus more posteriorly. In fig. 34, this division is found as a concentrated fibre mass dorso-lateral to the nucleus medialis and ventro-medial to the central nucleus, from which as it passes lateralward and dorsalward it receives fibres. As a distinct fibre bundle, it is seen to curve around the boundary line between the thalamus and corpus striatum. It is impossible to know whether or not its fibres synapse in the nucleus of the stria terminalis. They appear to pass by uninterruped. At the anterior level of the nucleus medialis, this tract turns ventro-medially outlining the ventral limit of this nucleus. When it has reached the midline, it becomes the stria medialis division of the stria terminalis, turns dorsally, and enters the lateral part of the stria medullaris.

Ventro-anteriorly, fibres which lie in the outer margin of the nucleus medialis seem to be continued forward to the nucleus of the lateral olfactory tract; some appear to lie in close vicinity to the nucleus of the area subcommissuralis.

The lateral division of the stria terminalis (*str.t.l.*, figs. 22 and 24) is made up of fibres which are collected from the nuclei lateralis, basalis, et centralis.

In the level posterior to the optic commissure, eleven sections rostral to the one pictured in fig. 23, these fibres of the lateral division may be seen proceeding from their place in the striatal bed, swinging in a semicircle between the main body of the corpus striatum and the thalamus, ventrally and slightly medially. The more lateral fibres turn laterally, circling about the nucleus amygdalæ lateralis, dorsal to the fibres of the anterior commissure. Medially they pass through or immediately medial to the commissure, ending in the nucleus amygdalæ basalis and in the lateral part of the pyriform lobe.

Returning again to the bed nucleus of the stria terminalis, these more loosely arranged fibres lie laterally in the floor of the lateral ventricle between the corpus striatum laterally and the medial division of the stria terminalis medially. A larger part of these fibres are interrupted by the two nuclei of the stria terminalis. After the interruption, the whole bundle runs ventro-rostrally, remaining in the floor of the ventricle, lying lateral to the medial. From this point forward three things happen to this bundle : some of the fibres appear to stop in the nucleus of the anterior commissure, others pass dorsal, and still others ventral to the commissure. The two latter ones might be named the supracommissural and infracommissural bundles.

The supracommissural bundle (*supracom.b.*, fig. 36) hugs the dorsal circumference of the anterior commissure, passes over it, sending loose fibres into the septum in the region of the medial nucleus, turns ventralward, contributing fibres to the area sub-commissuralis and probably to its nucleus, and passes on into the hypothalamus.

The infracommissural bundle (*infracom.b.*, figs. 37 and 40) turns ventro-caudal just dorsal to the anterior commissure. Some of the fibres pass into the hypothalamus (*str.t.hypoth.*, figs. 36 and 37) and others into the lateral part of the area subcommissuralis.

The longitudinal bundle (*l.b.*, figs. 23, 24, 42, 51 and 66) appears as a distinct fibre bundle in the caudal limit of the endorhinal fissure. It passes dorso-laterally so that its fibres penetrate the medial, the basal and the cortical amygdaloid nuclei. The writer has been unable to circumscribe definitely its origin. The fact that it appears as a definite bundle at about the transverse level of the nucleus olfactorius lateralis with a few fibres anterior, suggests that it may connect the lateral subcortical olfactory areas with the amygdaloid complex. In all probability fibres from the pyriform lobe enter it and are distributed caudally to amygdaloid nuclei.

Connections between the nuclei of the corpus striatum (*nuc.c.str.*, figs. 19 and 45) and the amygdaloid are made by two distinct fibre bundles, traceable in either longitudinal or transverse series from the two nuclei in question, forming an arc of a great circle about the ventro-lateral part of the corpus striatum and passing into the nuclei amygdalæ basalis and lateralis.

The olfactory projection tracts.—In Ornithorhynchus there appear to be two distinct routes by which impulses from the amygdaloid nuclei may find their way into the subthalamus. Some of these fibres may also penetrate the hypothalamus, but certainly their more prominent connections are subthalamic. The first of these tracts is direct. It leaves the dorso-medial side of the nucleus amygdalæ medialis (see fig. 51) passes dorso-medially between the larger fibre fascicles of the medial forebrain bundle to the nucleus ventralis of the subthalamus (*n.v.s.*, fig. 51) ending as interlacing fibres among its cells. This appears to be similar to the so-called direct olfactory tract (*tr.o.p.v.*, fig. 51).

The indirect olfactory projection system, the tract of CAJAL (*tr.o.p.C.*, figs. 23 and 24) is composed of fibres which leave the nucleus amygdalæ lateralis by large bundles and by single fibres from the dorso-lateral region of the nucleus amygdalæ centralis. They pass dorsally, inter-digitating with the large bundles of descending systems from the cortex. These fibres then turn at an angle of about seventy-five degrees, pass medially, ventral to the main mass of the nucleus medialis thalami and end in the nucleus lateralis of the subthalamus. Some of them may turn ventro-medially to enter the nucleus lateralis magnocellularis subthalami.

Amygdala-Hippocampus connections.—At the most ventral and cephalic tip of the hippocampus anterior to the ventricle, where the pyriform slightly covers that formation, many small fibres may be seen leaving the ventro-lateral side of the nucleus amygdalæ basalis and passing to the hippocampus.

Amygdala-Putamen connections.—Small short fibre connections may be found at the more dorsal region of the nucleus amygdalæ lateralis (*n.a.l.*, fig. 25) which bring it into relation with that part of the corpus striatum which lies lateral to it, probably the putamen.

External capsule.—The fibres which are seen in the lateral side of the lobus pyriformis may be followed to the anterior commissure where they turn laterally; some emerge within a few millimetres and pass into the cortex, others continue as a part of the fibre fascicle.

The commissures.—The anterior commissure receives fibres from all of the nuclei of the amygdaloid complex except the lateral. These fibres enter the ventral part of the commissure and pass medially.

The Telencephalon.

The telencephalon, unusually large for an animal of the size of Ornithorhynchus, may be divided into the customary lobes with some degree of accuracy. The smooth surface of the cortex is almost unbroken by fissures except that of the cruciate (*f.c.*, fig. 46, *a*) which the author has taken to be the homologue of the fissura centralis, because the largest pyramidal cells in the cortical layers are found near it and because the descending pathways from the cortex originate in that vicinity. If these facts form a basis for judgment then the cortex anterior to this fissure is frontal lobe, and posterior to it the parietal lobe.

Upon its lateral surface there is a shallow indication only of the lateral fissure (*f.l.*, fig. 46, *b*) which serves nevertheless as a boundary between the more ventral part of the parietal and the dorso-anterior limit of the temporal. However, because of the poor fixation of the material, it is impossible macroscopically to establish exact boundaries for these lobes and therefore for the occipital, although the occipital pole is distinct enough.

On the ventral surface (fig. 46, *b*) the stalks of the olfactory bulbs are continuous with the nucleus olfactorius which is divided posteriorly into the medial olive-shaped mass, the tuberculum olfactorium (*t.o.*, fig. 46, *b*), and the lateral slender, curving lobus pyriformis (*pyr.l*). This ancient pallium is separated from the neopallium by the deep fissura rhinalis (*f.rh.*, fig. 46, *b* and *c*) laterally, and medially from the tuberculum olfactorium by the fissura endorhinalis, and from the amygdala by the fissura amygdalæ (*f.am.*, fig. 46, *c*).

Elliot Smith's excellent studies upon the hippocampus and fascia dentata of this beast leave nothing new for the author to describe in this part of the brain of Platypus. The hippocampus and fascia dentata, as pointed out by Elliot Smith, are much larger in the region of the septum or paraterminal body (fig. 45, *c*) than at the temporal pole, forming a broad area over the surface of the lateral hemisphere, dorsal to the anterior commissure, and waning to a slender cone caudalward of the tip of the temporal pole. In the region anterior to the anterior commissure, the fascia dentata appears as a separate gyrus immediately beneath the hippocampal formation. As these two structures are joined posteriorly, the fissura hippocampi and its ventrally placed, accompanying sulcus fimbrio-dentatus, which form so prominent a part of the precommissural anatomy of this brain, disappear from view and lie hidden beneath the overhanging neopallium.

On the mesial surface, the most prominent structure is the anterior commissure which passes through the lamina terminalis, ventral to its companion, the smaller hippocampal commissure (figs. 35 and 46, *c*). In the brain wall forming a triangle between the fascia dentata, the lamina terminalis and the tuberculum olfactorium, is the area precommissuralis (paraterminal body of Elliot Smith, the septum of Herrick or the parolfactory area of Johnston (*sept.*, fig. 46, *c*). Between the ventral surface and the anterior commissure, yet anterior to the optic commissure, is the area subcommissuralis (*a.s.*, figs. 35 to 39 and 46, *c*), probably corresponding to the anterior perforated space (*a.p.s.*, fig. 37).

No modification of the stalk of the olfactory bulb in a direction such that the three olfactory tracts may be distinguished from the outside is found. Indeed, the nucleus tractus olfactorii lateralis lies hidden in the brain substance dorsal to the fissura endorhinalis. Also there is, on the ventral surface of the area subcommissuralis, no ridge which can be called the diagonal band of Broca.

The olfactory bulb (*o.b.*, figs. 46, *a*, *b*, *c*). The olfactory glomeruli (*s.gl.*, fig. 31, *b*) appear, in the Weigert stain, as brownish circles between the clear stratum medullare (*s.m.*, fig. 31, *b*) and the entrance of the olfactory fila (*s.f.n.o.*, fig. 31, *b*), confined to the medial and ventral parts of the transverse section of the bulb. Within the semicircle of glomeruli there are three concentric arcs of fibres,—beyond the stratum medullare (*s.m.*, fig. 31, *b*) on the stratum gelatinosum, the first is formed by the fibres about the mitral cells (*l.m.c.*); the second is incomplete, the stratum of fibres about the cells of the stratum granulosum internum (*s.gr.i.*, fig. 31, *b*); and the third more posteriorly in the bulb, is continuous at the lateral lips of the fissura of the bulb with the first, the stratum of fibres of the tractus olfactorius (*s.t.o.*). The last stratum becomes concentrated into a large dorsal group and a large ventral group (see fig. 31, *a*). A few millimetres posterior to this, the whole of the ventral border of the bulb is filled with fibre bundles; the dorsal collection becomes concentrated into a definite fibre group; the dorso-lateral and ventro-lateral become definitely the lateral olfactory tract; while the ventro-medial together, possibly with some of the dorsal, fuse to form the medial olfactory tract (*tr.ol.m.*, figs. 29 and 30).

In the dorso-lateral margin of the bulbus olfactorius there is found a large fissure which extends about half way into its body—the fissura bulbi olfactorii (*f.b.o.*, fig. 31, *b*). It disappears slightly anterior to the attachment of the bulb to the ventral surface of the telencephalon. The lateral ventricle of the telencephalon is not continued as a cavity into the olfactory bulb; in fact at its point of attachment the bulb is solid. In the more rostral levels of the bulb, the fissure of the bulb is plugged by a solid ellipsoidal mass. In all probability this fissure marks the site of the accessory olfactory bulb and the ellipsoidal plug is, in part at least, the vomero-nasal nerve fibre-mass. This nerve coming from JACOBSON'S organ can be traced as far as the olfactory bulb. In the control dissection a portion of that nerve was lost in the medial surface of the bulb. This was observed in a specimen unfit for microscopic study; but the nerve as it penetrates could not be identified in any of the adult series studied. In Prof. WILSON'S three fœtal brains of Platypus (Delta, XXVIII B, and Beta) there is a lateral mass of nerve fibres, which can be clearly followed, with some degree of certainty from the vomero-nasal organ. At the place where this mass attaches itself to the olfactory bulb, the arrangement of bulbar tissue is similar to the stratum glomerulosum of the bulbus olfactorius proper. Following a cupping or infolding at this point (ELLIOT SMITH, 1895) the layer, which shows no medullation in the Weigert transverse series, would be the site of entrance of JACOBSON'S nerve (*b.o.a.*, fig. 31, *b*). Beyond this central core lies a layer of fibres which pass into both the medial and the lateral olfactory tracts.

The cells of the bulbus olfactorius.—Many granule-like cells are found about the glomeruli, forming what has been called the stratum granulosum externum (see position in *s.gr.e.*, fig. 31, *b*). Within this layer, is one of medium-sized triangular-shaped cells—the lamina of mitral cells (*l.m.c.*). Concentric and central to this layer lies another, a thick layer of granule cells, some of which are arranged in groups, constituting the stratum granulosum internum (*s.gr.i.*, fig. 31, *b*). In the preparations of the adult brain at hand (series S.T.N. and S.T.W.) the glomerular layer of the accessory olfactory bulb cannot be identified with absolute certainty; but in the fœtal specimens Delta XXVIII B, and Beta, the layer stands out clearly in contrast to that of differentiating mitral cells, medial to it. In fig. 31, *b*, that layer (*l.m.c.*) lies between the nervus vomeronasalis (*n.v.n.*) and the fibre layer nearest the core of the olfactory bulb.

At the base of the bulb, near its attachment to the telencephalic vesicle dorsal to the centre of the olfactory bulb lies the *nucleus olfactorius anterior* (*n.o.a.*, figs. 30, 35 and 52). This is a large nucleus made up of triangular or polymorphous-like cells. In the Weigert preparations it lies towards the centre of the bulb where the prominent group of fibres appear to originate. They pass in two directions—one into the cortex as the funiculus olfactorius corticalis superior (*fun.o.c.sup.*, fig. 52) while the other forms the tractus olfactorius (*tr.o.*, fig. 38).

The tuberculum olfactorium (*t.o.*, figs. 2 to 6; 27, 28, 35 to 41; and 46, *b* and *c*) lies posterior to the preceding nucleus and anterior to the area subcommissuralis, while medio-laterally it is lateral to the nucleus medialis septi, medial to the nucleus of the lateral olfactory tract, and ventral to the nucleus accumbens. Its cells are arranged in flounced rows, one above the others.

The nucleus of the diagonal band of BROCA (*n.d.b.B.*, figs. 26, 41, 54 and 55) seems to be represented probably by scattered polymorphous pyramidal cells which appear lateral to the fibres of the medial forebrain bundle (*m.f.b.*, fig. 54) and to the nucleus of the subcommissural region (*n.a.s.*, fig. 54) (or ventral to it in fig. 55, in the medial lip of the fissura endorhinalis) and anterior to the optic commissure. Apparently the nucleus of BROCA is continuous posteriorly with the nucleus of the lateral olfactory tract (*n.t.o.l.*, fig. 57).

The nucleus accumbens (*n.a.K.*, figs. 27, 28, 35 and 37 to 39) is unusually large in Ornithorhynchus. It surrounds the angle of the lateral ventricle, anterior to the region of the commissura anterior. It is bounded medio-dorsally by the nucleus lateralis septi, medially by the nucleus medialis septi, and ventrally by the tuberculum olfactorium. In most preparations, the cells are large, triangular or polymorphous.

The septum or paraterminal body contains two nuclei—the nucleus septi medialis and the nucleus septi lateralis. These two nuclei are quite distinct in Platypus. They can be easily delimited and correspond to the two parolfactory nuclei described by CROSBY (1917) in the alligator and by HINES (1923) in Sphenodon. The nucleus septi medialis (*n.s.m.*, figs. 28 and 29) is found in the ventro-medial part of the septum, separated from the nucleus accumbens by a small bundle of fibres and medial to the medial limit of the tuberculum olfactorium. The cells are smaller than those of the nucleus septi lateralis (*n.s.l.*, figs. 28 and 29). This latter nucleus lies in the dorso-lateral region of the septum, ventral to the hippocampus and dorsal to the septal portion of the nucleus accumbens. The cells are larger than those of the medial septal nucleus but not as large as those of the nucleus accumbens. The fact that the lateral nucleus is the origin for a portion of the medial forebrain bundle suggests a plausible reason for its cells being larger than those of the medial nucleus.

The nucleus preopticus (*n.p.o.*, figs. 37 and 38) is made up of several rows of cells surrounding the ventral part of the third ventricle about two millimeters cephalward of the optic chiasma. There is no definite arrangement of the small round and slightly elliptical-shaped cells.

The area subcommissuralis and its nucleus (*a.s.*, and *n.a.s.*, figs. 25 to 26; 35, 38 and 39; 54, 55 and 57) lies immediately ventral to the anterior commissure, lateral to the medial margin of the brain wall, anterior to the preoptic nucleus and posterior to the head of the corpus striatum and tuberculum olfactorium. Its position is homologous to the anterior perforated space in other mammals studied; otherwise it has little similarity. In its anterior part (*i.e.*, near the tuberculum olfactorium) its cells are arranged more or less amorphously. They occupy all the medio-lateral thickness of the brain wall. But caudally (*i.e.*, ventral and posterior to the anterior commissure) there is a nuclear mass which is now confined to the lateral part of the brain wall, the medial lip of the endorhinal fissure. The cells themselves in this nuclear mass are very large and triangular in shape, resembling motor cells. In the Bielschowsky series, they appear embedded in a neuropile which stains densely brown, so that they are easily delimited from other large cells of the area.

The nucleus of lateral olfactory tract (*n.t.o.l.*, figs. 25, 51 and 57) is a poorly defined group of cells lying in the medial lip of the fissura endorhinalis, caudal to the nucleus of the diagonal band of BROCA (compare fig. 55 with fig. 57) and anterior to the amygdaloid complex. The cells themselves are dominantly pyramidal, with a few polymorphic ones among them.

The lobus pyriformis (*pyr.l.*, figs. 8 to 10; 22 to 28; 34, 46 *c*, 54, 55, 57 and 58) is very slender and is situated on the ventral surface of the brain. Its anterior boundary lies posterior to the anterior olfactory nucleus. As it is followed posteriorly, it is separated from the neopallium laterally by the fissura rhinalis (*f.rh.*, figs. 29 and 30) and medially from the tuberculum olfactorium (figs. 29 and 28) and the area subcommissuralis (fig. 26) by the fissura endorhinalis (*f.e.rh.*). In the region just caudal to the posterior limit of the anterior commissure, at the level of the optic commissure, the di-telencephalic groove (*d.t.gr.*, figs. 57 and 58) appears slightly medial to the fissura endorhinalis (*f.e.rh.*, figs. 57 and 58). The level of the main body of the optic commissure marks the caudal end of this fissure and the posterior boundary of the nucleus of the lateral olfactory tract. The fissura endorhinalis does not appear to be continuous with the fissura amygdalæ. The former ends just posterior to the optic commissures and the latter does not begin as a distinct fissure on the brain surface, until the level of the corpus mamillare is reached (compare *f.e.rh.*, figs. 55, 57, 58; *b.am.*, fig. 58, and *f.am.*, fig. 34).

By passing two planes at right angles through the length of the conformation, the pyriform lobe may be divided into three regions, histologically distinct from each other. The most rostral area, the lobus pyriformis anterior, lies rostral to the posterior limit of the anterior commissure (*pyr.l.*, figs. 26 to 28, 54 and 55). The line of separation between the middle or central region, the lobus pyriformis centralis (*pyr.l.*, figs. 34, 57 and 58), and the posterior (*pyr.l.*, figs. 46 *c* and 62) is discovered at the level characterised by the appearance of the hippocampus immediately dorsal to the cortical nucleus of the amygdala.

Also the cortex of the pyriform lobe may be divided longitudinally into three columns of cells. They lie within the three unattached boundaries of the lobe—the medial, the ventral and the lateral. The laminated cortex of these three regions may be considered as divided into three layers (fig. 34)—an outer or relatively cell-free area, characterised by its fibre content; a second or predominantly pyramidal layer; and a third, innermost, irregular layer of double pyramids and smaller cells, which are probably granule cells.

The following table gives the characteristic cell-types of the cortical laminations within the three lobes and the three regions of the lobus pyriformis.

TABLE II.

Division of lobe.		Medial region in lateral lip of the endorhinal fissure.	Ventral region on ventral surface of hemisphere.	Lateral region lying in the medial lip of the rhinal fissure.
Lobus pyriformis anterior.	I.	*tr.o.l.* fibres	*tr.o.l.* fibres	*tr.o.l.* fibres.
	II.	Pyramidal and granule cells.	Few small pyramidal cells and many granule cells.	Pyramidal cells and granule cells. The large pyramidal cells border the medial lip of rhinal fissure.
	III.	Double and single pyramids.	Double pyramids and a few granule cells.	Double pyramids.
Lobus pyriformis medialis.	I.	*tr.o.l.* fibres present	*tr.o.l.* fibres present	No fibres in Weigert.
	II.	Many closely packed pyramids.	Small pyramids with some granule cells.	Closely packed pyramids.
	III.	Pyramidal cells and large triangular-like cells similar to the nucleus of area subcommissuralis.	Double and single pyramidal cells.	Small pyramids and irregular-shaped cells.
Lobus pyriformis posterior.	I.	No fibres in Weigert.	No fibres	No fibres.
	II.	Pyramidal cells	Single and double pyramids.	Pyramidal cells with some polymorphous cells.
	III.	Pyramidal and polymorphous cells.	Pyramidal cells, double and single.	Pyramidal cells and polymorphous cells.

The outline of the cortical lamination of the pyriform thus presented permits of a few generalisations. The first layer contains fibres of the olfactory tracts in all regions in the anterior area, on the ventral and medial aspects in the middle region, while none are discernible in the material studied in the posterior division. Throughout the three transverse regions, the medial area is the most homogeneous, that is, there are fewer cells other than the pyramidal type. On the other hand, the ventral region of the pyriform cortex shows greater variation in cellular types in the pyriformis anterior, and the pyriformis posterior contains in its lateral transverse cortical layers many polymorphous cells.

If these cellular shapes in the Bielschowsky preparations are a reliable criterion of the type of cells, and if the type bespeaks a function, as is generally conceded, then the facts presented might hint that the medial and ventral regions of the anterior and middle pyriform lobes are the areas for the reception of impulses. The lateral region in all three transverse regions may then be interpreted as the cortex of motor discharge. It is possible that the medial area of the posterior pyriform is similar in function, for certainly this material shows no evidence of a direct connection with primary or secondary olfactory centres.

The hippocampus and fascia dentata (*hip.* and *f.d.*, figs. 2 to 7; 18 to 28; 46 *c*, 62, 76 and 77). It has been mentioned in the early part of the description of the telencephalon of Platypus that the hippocampus is the most prominent structure in the medial wall of the hemisphere anterior to the hippocampal commissure. Here the fissura hippocampi (*f.h.*, figs. 26 to 28; 46 *c*, 76 and 77) is both wide and deep. Posterior to the hippocampal commissure (figs. 20 to 25), the fissure grows narrow and almost closed, as the hippocampal formation becomes inrolled on itself, so much so that the fascia dentata is barely visible as a gyrus on the medial surface of the telencephalic brain wall.

The fascia dentata follows the hippocampus, lying ventral to it, as a concentric arc, until it gradually disappears within the enrolling wall caudal to the hippocampal commissure. Here, as the author also noted for the development of the hippocampus and fascia dentata in man (HINES, 1922), the extent of the hippocampus is considerably greater than the fascia dentata at the temporal pole, while its projection beyond it in the precommissural region is but slight.

The alveus (*alv.*, figs. 76 and 77) contains the fibre systems which leave the cortex of the hippocampus from the ventral part (the association system with the neopallium):—the fornix (*for.*) and the tractus cortico-olfactorius (*tr.c.o.*, fig. 76) form the dorsal part. The fibres for the hippocampal commissure leave the hippocampus by two routes: by the alveus and by the medial side of the hippocampus lateral to the fascia dentata. The tractus olfactorio-corticalis (*tr.o.c.*, fig. 76) ends in the medial brain wall, medial to the fascia dentata, forming a fibre cone about its ventral border. Undoubtedly, some of the fibres formed about the medial boundary of the hippocampus belong to the precommissural system (*fais.precom.*, fig. 76), which is so large in this brain.

In the angle of the fissura hippocampi, a large number of vertical fibres are found which continue around the lateral convolution of the fascia dentata and end in the matrix of the hippocampus, constituting the medial bundle of mossy fibres (*m.f.m.b.*, fig. 76) of KOELLIKER.

The alveus sends penetrating fibres into the pyramidal layer throughout its greatest extent. The precommissural group, however, appears to be connected with the cells of that layer at the tip where it turns toward the fascia dentata at a right angle. Between the stratum lacunosum (*s.l.*, fig. 77) and the pyramidal cell layer (*pyr.c.*, fig. 77), there is a diffuse horizontally arranged fibre layer which KOELLIKER has called the deep layer of mossy fibres (*m.f.d.b.*, fig. 76). They are the axones of cells bringing impulses to the pyramidal cell-layer.

The cell layers of the fascia dentata in the NISSL material correspond to the old description of that gyrus. There is an outer stratum zonale (*s.z.*, fig. 77) in which a very few scattered granule cells may be seen among a few fibres. The middle layer, that of the closely-packed granule cells, is (*s.gr.*) characteristic of this structure. The inner layer is that of polymorphic cells (*poly.m.c.*) arranged so that their poles are parallel to the convolution. This layer contains fewer cells than is the case in man.

In the hippocampus, the most prominent layer is that of the giant pyramids (*pyr.c.*, fig. 77), some of which are double. If this layer is followed around the circle to the subiculum, the size of the pyramidal elements decreases until suddenly the layer itself is discontinued. It contains fewer cells than is the case in other mammals. The polymorphic layer (*poly.m.c.*, fig. 77) is even more sparse, growing less so however in the dorsal tip of the hippocampal fissure where the pyramidal layer stops. At this point the polymorphous cells lie irregularly in a deep row ; medial to them are a few scattered pyramids, forming the subiculum. The polymorphic layer is continuous with layer six of the area retrosplenialis, while the pyramidal cells form layer two. Between them a layer of small pyramids appear—that is, layer five. Just dorsal to this region is that of the transition to the gyrus cinguli, marked by the appearance of a few granule cells among the small pyramids of layer three.

A section through the area of transition in the arc formed by the meeting of the cortical layers of the pyriform and hippocampal gyri may be seen in fig. 62. The layer of pyramidal cells of the hippocampus (*pyr.c.*) seems to suffer a sudden transformation into polymorphic cells, characteristic of the inner layer of the fascia dentata. These cells are continued along the margin of the lateral ventricle and accompany the heavily staining granule cells (*gr.c.*) of the fascia dentata. They are found in the ventrolateral angle near by the granule cells. These granule cells lie lateral to the polymorphic cells which form the dorsal limit of the cortical nucleus of the amygdala (*n.a.cort.*). They are continued ventrally and are mingled with polymorphic cells from what might be called the fourth layer of the cortex characteristic of the lobus pyriformis posterior. The outer layer, the stratum zonale, resembles that same layer in the fascia dentata (*s.z.*, fig. 77), containing a few granule cells only. The inner layer, the one which lies immediately beneath the ependyma, is the neopallial association system, the alveus.

The Fibre Systems.

The tractus olfactorius (*tr.o.*, fig. 35) begins as a definite system of fibres posterior to the olfactory crus, and thereafter is continuous at the base of the bulb with the nucleus olfactorius anterior. It may be divided into two large divisions, the medial and lateral tracts, and one smaller, the intermedius. Some of these fibres proceed without synapse to the secondary olfactory centre ; others end in the nucleus olfactorius anterior.

The tractus olfactorius medialis (*tr.ol.m.*, figs. 27 to 31, *a*) runs in the ventro-medial corner of the paraterminal body or septum, and sends fibres into the nucleus of that tract. From there it passes dorsally and caudally along the medial margin of the septum to the ventral limit of the fascia dentata.

The tractus olfactorius lateralis (*tr.o.l.*, figs. 25 to 31, *a* ; 54, 55, 57, and 58) spreads out in the region of the nucleus olfactorius anterior as a thin sheet of fibres over the lateral half of its surface. In the same level with the first indication of the fissura rhinalis, the fibres of this tract are found lying lateral to the fissure and upon the rostral surface of the pyriform. In figs. 26 and 27 these fibres occur on the lateral lip of the endorhinal fissure. From this point posteriorly throughout the anterior division of the pyriform they surround the whole lobe. In the middle region they are confined to the medial and ventral boundaries, while in the posterior they are difficult of discernment in the Weigert sections.

The tractus olfactorius intermedius (*tr.o.i.*, figs. 27 to 30) seems to be formed of two parts—the one which lies midway between the lateral and the medial tracts directly dorsal to the limiting membrane of the ventral telencephalic wall, and the other, which lies dorsal to it. Some of the dorsal fibres curve dorso-anteriorly and pass directly into the non-olfactory cortex, which lies anterior to the hippocampus. The position of these fibres resembles those pictured for the mouse by HALLER (1900) in his fig. 5, Table XXI (*f.o.c.s.*), and called by him the funiculus olfactorius corticalis superior (*fun.o.c.sup.*, fig. 52). Both dorsal and ventral strands penetrate the tuberculum olfactorium from its ventral surface. It is the ventral sheet which passes into the area of the diagonal band of Broca.

The tractus tuberculo-corticalis (*tr.tub.c.*, figs. 36 to 38) arises as a large and important fibre bundle from the rostral end of the tuberculum olfactorium. It passes to the medial surface of the septum between the nucleus septi lateralis and the nucleus septi medialis. The tractus swings medially close to the angulus ventralis of the lateral ventricle, anterior to the nucleus accumbens. It ends in the hippocampus.

The tractus cortico-tubercularis (*tr.c.t.*, fig. 76) lies among the fibres of the more rostral part of the alveus, and crosses the lateral margin of the nucleus septi lateralis. It swings ventralward, sweeping anterior to the anterior limit of that nucleus and then ventral to the ventral angle of the lateral ventricle. Its fibres appear to end in the ventral part of the tuberculum olfactorium and lie medial to the fibre bundle just previously described.

The tractus cortico-septalis (*tr.c.s.*, fig. 28) leaves the hippocampus *via* the alveus, and follows the curve of the medial wall of the lateral ventricle, anterior to the fornix. It ends in the dorso-lateral part of the nucleus septi lateralis.

The tractus septo-corticalis (*tr.s.c.*, figs. 27 and 28) leaves the medial septal nucleus and also the cells in the more dorsal part of the septum. The tract passes beneath the limiting membrane of the medial wall of the telencephalon to enter the stratum zonale of the fascia dentata and the medial side of the pyramidal layer of the hippocampus.

The fornix (*for.*) makes its exit from the hippocampus along its whole length. It lies immediately beneath the ependyma of the dorso-medial wall of the lateral ventricle and plunges ventrally in the region of the hippocampal commissure. It then turns medially, dorsal to the nucleus septi lateralis, and lies dorso-medial to the medial forebrain bundle. As it swings caudally dorsal to the anterior commissure it divides into its two components, the dorsal, or tractus cortico-habenularis and the ventral or tractus cortico-mamillaris. Both of these have been described.

The diagonal band (*d.b.*, fig. 30).—A transverse band of fibres may be traced from the medial septal nucleus over the ventral telencephalic wall, ventral to the most rostral limit of the tuberculum into the region of the lateral olfactory tract. Small fibres appear to be added to the fascicle in its passage. In the region of the nucleus of the diagonal band of Broca (*n.d.b.B.*, figs. 26 and 55) no fibres appear in the surface of the area subcommissuralis. Nor do any of them cross the ventral face of the tuberculum olfactorium.

The tractus cortico-subcommissuralis is that sheet of fibres which connects the hippocampus with the area subcommissuralis. It lies close to the medial surface of the septum, and spreads out in the medial part of the nucleus in question. This system is the same, in the belief of the author, as JOHNSTON'S tractus olfacto-corticalis septi or the faisceau precommissuralis (*fais.precom.*, fig. 76) of RAMON Y CAJAL. It may be homologous with the stria longitudinalis Lancisii, which carries impulses from the nuclei of the thin septum pellucidum in man to the molecular layer of the fascia dentata and the pyramidal layer of the cornu ammonis. If this assumption is correct, then this tract is an ascending system. But the nuclei of this area subcommissuralis resemble those of a nucleus in the path of a motor discharging system.

However, slightly lateral to this medial system, another fibre bundle is found which connects the rostral end of the hippocampus with this area, especially with that part which lies directly ventral to the anterior commissure, by passing between the nucleus olfactorius anterior and the tuberculum olfactorium, then continuing ventral to that nucleus. There is another small fascicle which begins in the nucleus olfactorius anterior and passing dorsal to the tuberculum olfactorium ends in the area subcommissuralis, dorsal and lateral to the foregoing system.

The postero-lateral part of the area subcommissuralis is the origin for many descending fibre groups—one, to the hypothalamus (region of the central grey) ; one, to the subthalamus (ventral nucleus); and a third, into the midbrain peduncle. They are arranged in a ventro-dorsal manner. The tuberculum olfactorium and the neighbouring part of the corpus striatum discharge into it.

The hippocampal (*dorsal*) *commissure* (*d.c.*, figs. 35 to 38).—Besides the fibres which cross from one hippocampus to another, there are the decussating bundles of the fornix system and a few fibres which after crossing end in a small nucleus ventral to the commissure—the nucleus of the hippocampal or dorsal commissure. It is quite probable that a few fibres from the region of the subiculum cross in this commissure, because the alveus fibres penetrate that region. Although the alveus may perhaps carry them as long association fibres into the neopallium, it may also induct them into the hippocampal commissure. The line of division between the two systems in Ornithorhynchus is not clear cut until the transitional region of the cortex is passed. There is no doubt that the commissure fibres enter the bundle of the anterior commissure. Only degeneration experiments can definitely settle this point, and it is not of vital importance, whether or not a few definitely non-hippocampal commissure fibres happen to cross in the hippocampal or dorsal commissure.

The anterior commissure (*a.c.*, figs. 26, 2 to 6).—This is the commissure for the whole telencephalon with the exception of the hippocampus. The two halves of the neopallium send fibres through it. The putamen of the striatum appears to contribute its portion. The total amygdaloid complex sends fibres into it. The commissure connects the two olfactory bulbs *via* the tractus olfactorius intermedius. The pyriform lobe and the nucleus of the lateral olfactory tract send fibres into the ventral division of the commissure and finally the whole of the area subcommissuralis discharge numerous fibres into it, which turn and run through it medially. Their point of exit is unknown.

The medial forebrain bundle (*m.f.b.*, figs. 35 to 38) leaves the medial cortex of the nucleus septi lateralis and lies as a thin profile of fascicles, one above the other, medial to the tractus olfactorius corticalis and rostral to the anterior commissure. This bundle may be followed dorsal to the commissure, where it is ventral and lateral to the fornix. Then curving concavely, it may be seen ventral to the medial nucleus of the thalamus as a circular bundle of fibre fascicles. It is lost in the dorsal part of the tegmentum of the midbrain.

The lateral forebrain bundle (*l.f.b.*, figs. 42 and 43) has been described under the thalamus as constituting those systems which connect the medial and anterior nuclei of the thalamus with the nucleus caudatus and with the putamen of the corpus striatum, and the globus pallidus with the subthalamus and the motor centres of the midbrain.

Discussion.

In this consideration, the structures described in the previous sections of this paper will be discussed as integral parts of various functioning systems. Further, the physiological units will be compared with those of the brains of other animals in so far as they suggest, in their similarity or difference, a reasonable interpretation for the unit under discussion in Platypus.

The peculiar form of the medulla oblongata is largely the result of two spectacular growths, characteristic not only of Ornithorhynchus and Echidna, but also of some Marsupialia such as the Virginian Opossum: first, that of the sensory division of the fifth nerve; and second, that of the enormous peduncular systems found near the median raphé in the midbrain and medulla. Before these two systems have reached their maturity (see Prof. WILSON's fœtus " X," for example), the shape of the medulla and the relative internal position of the various nuclei, both motor and sensory, are strikingly similar to those of the medulla oblongata of other mammalian forms.

The general cutaneous centre of the medulla, the tuberculum quinti of ELLIOT SMITH (1899), is comparable to the tuberculum cinereum of higher mammals and man. Microscopically, this centre, as in man, may be followed into the upper transverse levels of the cervical cord, where it passes gradually into the substantia gelatinosa of the cord. This column of cells cannot be divided definitely into nucleus sensibilis and nucleus of the spinal fifth tract, as is customary in modern mammalian neurology. Cephalward the lateral division of the fifth sensory tubercle is confluent with the spinal portion, while the medial or larger celled region is not. ELLIOT SMITH (1899) has shown in fig. 1, p. 343, that the ophthalmic and maxillary branches of the fifth nerve enter the tuberculum anteriorly and medially, and that the mandibular branch enters with the emergent motor root laterally. KOELLIKER (1901) also believes that the medial nucleus receives the mandibular division. These anatomically discrete nuclei may be, then, but the receptive centres for impulses travelling centralward over these two groups of peripheral fibres of the fifth. VAN VALKENBERG (1911) says that the ophthalmic fibres in birds end in the spinal fifth nucleus, and that the maxillo-mandibular fibres terminate in the frontal sensory division of the centre. Further, there are no data which demonstrate a difference in the secondary pathways originating in this nucleus, as described in the rabbit for nuclei *a* and *b* of the trigeminus by WINKLER (1921). With an anatomical description only it is impossible to subdivide the trigeminal nucleus, as does GERARD (1923) for the cat, into a sensory nucleus for tactile sensibility, and a spinal for pain and temperature. Certainly in Ornithorhynchus, the peculiar endings within the snout appear to be specialised for tactile sensibility (see WILSON and MARTIN, 1894). And the relatively extensive snout area is supplied by a series of massive branches from both the mandibular and maxillary divisions. They may be related to the marked hypertrophy of what the author has pleased to call the nucleus sensibilis.

The decussation of the trigeminal lemniscus is not scattered throughout the whole length of this nucleus, but is confined more or less to the region of the brain stem about the level of the site of the nucleus of the motor fifth. No caudal lemniscus for the nucleus of the spinal fifth tract was identified. This anatomical arrangement is entirely unlike the situation pictured for the rabbit by both WALLENBERG (1905) and WINKLER

(1921), where the fibre systems leaving the nucleus sensibilis divide into a dorsal and a ventral sheaf. WALLENBERG thinks the dorsal system ends in the fifth motor nucleus and in the contralateral third nucleus. On the other hand, the ventral system passes forward through the midbrain to the ventral nucleus of the thalamus, via the lamina medullaris interna, to end in the " centre médian," while some of the fibres terminate in the central grey matter of the third ventricle and some in the medial part of the ventral thalamic nucleus as far anterior as the nucleus anterior. But WINKLER (pt. 2, fig. 218) has attempted to demonstrate in the rabbit that the secondary ventral tract constitutes a part of the lemniscus medialis, and that the dorsal, after crossing ventral to the central grey and lying in the formatio reticularis, medial to the nucleus of the spinal fifth tract, loses itself in the medial portion of the nucleus ventralis of the thalamus. The ventral portion of this nucleus receives the secondary ventral group ; nucleus " *a* " of the nucleus sensibilis for proprioceptive sensibility, and nucleus " *b* " for sensibility of mucous membranes. The nucleus of the spinal fifth tract is for exteroceptive sensation. These interpretations are entirely contrary to the experimental data presented by GERARD (1923) and the more recent paper of STOPFORD (1925). The function of reception of pain and temperature sensation was assigned to the spinal portion of this nucleus by BROUWER in 1915. The hypertrophy of the spinal fifth apparatus in Platypus does not seem consistent with this view of the exclusive pain and temperature function of that apparatus.

The trigeminal lemniscus terminates in the adult Platypus in the ventral and medial region of the hypertrophied part of the thalamus—a mode of termination which the author believes to be homologous with the ending of WINKLER'S " *a* " portion of the lemniscus. KAPPERS (1922), following ZIEHEN (1908), called this area in Platypus the nucleus spongioides, a specialisation of the nucleus medialis and nucleus ventralis. It is true that the medial nucleus in Platypus is much larger than is usually the case and no union of the medial with a typical ventral could be discovered by the writer. Nor is there any indication that the sensibility of the seventh is taken care of by the nucleus sensibilis of the fifth, as suggested by KAPPERS in the same communication. It appears therefore that the various functions known to be served by this nerve cannot be confidently assigned to anatomical divisions of this nucleus in Ornithorhynchus.

The vestibular system as it appears in Platypus does not vary materially from the descriptions given by CAJAL for mammals, or from the traditional nervous relationships described for man. The various nuclei hold the same relative positions. The superior nucleus, that of BECHTEREW, owing to the peculiar shape of the fourth ventricle, lies in the dorsal area of the ventricle rather than in its lateral. No fibres either from or to the fasciculus longitudinalis medialis can be traced into this superior nucleus nor can it be demonstrated that this cell-aggregation is the origin in part of the tractus vestibulo-spinalis. Nevertheless, fibres are traceable from the fifth root into the nucleus and others seem to connect it with the central fibre layer of the cerebellum. There is no evidence here that the superior nucleus is efferent as WINKLER'S degeneration studies in the rabbit suggest (1921, pt. 2, p. 271). The lateral nucleus, or DEITERS' cell group, contains the large motor type of cells, common to all mammals. An unusually large limb of the fasciculus longitudinalis medialis enters it. Its connections with the cerebellum are very clear. Some few fibres may be traced past it, to lie among the descending fascicles of the eighth root; all of these arrangements are typical. However, no mesencephalic connections were traced, as suggested by WINKLER for the rabbit. There is nothing at variance with the typical mammalian description found for either the medial nucleus or the spinal. The direct cerebellar fibres are easily seen, and may be judged to be of some importance by their great number. There was nothing in this study to indicate whether or not the ramus anterior of the nervus cochlearis or the nervus vestibularis contained the ramus for the sacculus or whether it runs with the nervus cochlearis as described for the rabbit by WINKLER (1921) and OORT (1918).

In the *cochlear system* there is some disagreement in the identification of one of its major components. Both the dorsal and ventral cochlear nuclei of the traditional descriptions are present but the writer was unable to definitely identify a division of the latter into a pars dorso-lateralis and a pars ventro-medialis (WINKLER for the rabbit, 1921, p. 203, fig. 276), and there was no division of the ventral cochlear nucleus (the nucleus magnocellularis) into two parts as described for Echidna by SCHEPMAN. In a paper given before the Anatomical Association of Great Britain and Ireland (HINES, February, 1921), the superior olive was identified as the more or less circular nucleus which KOELLIKER had called the ventral nucleus of the motor seventh nerve. KAPPERS (in a private communication, June, 1924) substantiates KOELLIKER in this finding, which is here accepted as a result of re-investigation, with the added advantage of the Bielschowsky series. Besides the nucleus which KAPPERS would appear to regard as the superior olive (" *s.o.* ?," in fig. 32, *b*), *i.e.*, a small ovoid nucleus lateral to the ventral motor nucleus of the seventh, and dorso-lateral to KOELLIKER'S superior olive (*s.o.K.*, figs. 32, *a* to *c*), there is another ventro-lateral to the ventral motor facial nucleus (*s.o.*, figs. 32, *a* to *c*). Of the three nuclei regarded as possible representatives of the superior olive the characters and connections of the last-mentioned appear most clearly to point to this homology. It is connected with the one on the opposite side by fibres which leave from its ventral side, run ventrally and turn laterally, ventral to KOELLIKER'S superior olive. The two more lateral nuclei (*s.o.* ? and *s.o.K.*) may correspond to SCHEPMAN'S (1918) lateral nucleus of the superior olive and the medial one to his small medial for Echidna.

But unlike the findings of both SCHEPMAN (1918) for Echidna and STOKES (1912) for the opossum, the fibres of the corpus trapezoideum of Platypus pass medial and dorsal to the sensory nucleus of the trigeminus rather than lateral and ventral to it. And unlike STOKES' observations on the opossum no definite trapezoid nucleus was identified with certainty (fig. 32, *a*, *n.c.tr.* ?). The dorsal section of the secondary system, the tract of VON MONAKOW, penetrates the substance of the medulla in a manner similar to that described for Echidna, rather than that pictured by WINKLER for the rabbit and cat. If the thinly myelinated fibres passing through KOELLIKER'S superior olive be identified as the trapezoid body and its decussation, there are still two other fibre tracts, one which lies dorsal to the ventral nucleus of the seventh, and another which appears to form synapses with that nucleus and also to pass through it. These may be identified respectively as the decussations of MEYNERT and HELD. The fibres belonging to these decussations ride caudalward as the medial group of the lateral lemniscus as described by WINKLER (1921, p. 232, pt. 2).

In Platypus as in Echidna (SCHEPMAN) the dorsal decussation is the stronger, although, if SCHEPMAN'S illustrations reveal the true state of affairs, the dorsal secondary cochlear fibres form the greater portion (*i.e.*, the decussation of MEYNERT), while in Platypus ventral secondary fibres constitute the greater bulk passing dorsal to the superior olive or through the seventh motor nucleus. These fibres include the majority of the secondary axones, the decussation of HELD. If this interpretation be true, Platypus in this part of the cochlear system occupies an intermediate place between Echidna and Didelphys, where the ventral crossing is the better developed. The disparity between the two in favour of the ventral increases as hearing becomes more important in the animal's somatic adjustments. The writer did not identify any of the cochlear fibres as entering the medial division of DEITERS' nucleus (WINKLER and SCHEPMAN), because the dorsal cochlear nucleus was identified as an interruption in the root, similar to that described for higher mammals. However, this may not be correct. Indeed, no sub-division of the ventral cochlear nucleus (the nucleus magnocellularis of SCHEPMAN for Echidna) was noticed.

The remainder of the cochlear system is typical of that of mammals : thus it shows the interruption of the lateral lemniscus by two nuclei at least, pictured so beautifully by KOELLIKER and seen in all specimens studied by the writer ; the permanent knob-like inferior colliculus and fibres connecting it with the medial geniculate body.

The nucleus of the fasciculus solitarius and its neighbouring structures in Platypus, its length and relationship to its fasciculus are strikingly characteristic of all mammals studied. It would be quite possible to divide it into two parts, the nucleus dorsalis of WINKLER (the part which lies dorso-medial of the fasciculus layer, made up of smaller cells, the nucleus solitarius proper of KAPPERS' description), and the nucleus ventralis of WINKLER, which lies ventro-lateral to the fasciculus, is smaller in diameter but contains larger cells than the dorsal portion. Certainly it is to this region that TUMBELAKA (1916) has given the name of nucleus parasolitarius, an area whose cells ultimately send their axones to the ventral nucleus of the thalamus. WINKLER (1918, p. 375) studying RAMON Y CAJAL'S nuclei from the viewpoint of homologies, concludes that the complete nucleus of the fasciculus solitarius (*i.e.*, both dorsal and ventral) is equivalent to CAJAL'S "ganglion interstitiel," and that the dorsal gray of the triangular field of the tenth nerve is the "ganglion descendens" or nucleus intermedius of CAJAL. It is this nucleus that sends out medial wings in the lower levels of the medulla to form the "ganglion commissuralis." It is impossible in the material at hand to identify this nucleus with any degree of certainty. The general geographical relation of the level is disturbed by the narrow, slit-like ventricle so that it is difficult without degeneration experiments to know whether one is dealing with this portion of the visceral sensory nucleus or another differentiation of the central grey matter of the region, the nucleus funiculi teretis. So it was described in this material. Whether commissural or not in character it almost forms a bridge of cells from one dorsal sensory nucleus of the Xth to the other.

It is rather strange that no distinction between the nucleus parasolitarius and the nucleus of the solitary bundle is made by recent experiments in this region. ALLEN (1923) appears to regard the dorsal sensory nucleus, as described by KAPPERS (1920, pp. 305 to 312, vol. 2, pt. 1), as formed of but one group of cells in mammals, while WINKLER (fig. 171, pt. 1, 1918) regards it as two. It is quite possible that there is a marked variation in the relative development of the nucleus of the fasciculus solitarius and the nucleus parasolitarius in different animals, and that the degree of development accounts for the variation in their description by various observers. Nevertheless, ALLEN and KAPPERS agree that the anterior part of the nucleus is connected with the ventral nucleus of the thalamus by fibres which course alongside of the lemniscus medialis, and that the lower part is mainly concerned with connections with the nuclei of the hypoglossal or vagal nerves. ALLEN interprets the former secondary neurones as visceral, while WINKLER calls them proprioceptive. Further experimental work is necessary to determine whether this nucleus is to be regarded only as a visceral centre or as a mixed visceral proprioceptive area—and what the exact nature of the other nuclei may be.

The nucleus intercalatus lies in the region of the motor column as outlined by the American School, and yet the chromatolysis of the cells of the nucleus when motor roots alone are cut is negligible. WINKLER (pp. 408–410) finds that when the nervus glossopharyngeus is cut and the ganglion petrosum is removed in the cat, the cells of the nucleus intercalatus become smaller and that the very small cells disappear. Further, as a result of such experimental procedures, WINKLER recorded a diminution in size of the cells of the nucleus prepositus of the XIIth, the interstitial part of the nucleus triangularis, as well as a diminution in the tractus dorsalis tegmenti of SCHÜTZ and the annular zone of the nervus hypoglossus. Such changes were not reported by ALLEN (1923, 1) for the guinea pig. In addition, if the nucleus intercalatus be mainly concerned with taste in the tongue as suggested by KAPPERS (1920, vol. 2, pt. 1, p. 312), ALLEN should have found chromatolysis in this nucleus following section of either the sensory root of the VIIth or IXth. It is possible that this chromatolysis was overlooked. Suffice it to say, that in Ornithorhynchus the nucleus together with the tegmental tract of SCHÜTZ appear to be of some importance, but the anatomical findings settle none of these questions.

It appears then that besides the nucleus of the fasciculus solitarius, there are two other nuclei (the dorsal sensory nucleus of the vagus and the nucleus intercalatus) which may be concerned in visceral sensory functions, but what type of sensation they or their immediate or remote connections mediate cannot be determined in this study. No nucleus rotundus vagi of WINKLER was observed.

The motor nuclei of the medulla.—The nucleus hypoglossus presents no feature worthy of comment. It is large and easily identified. Its cells are enormous, eclipsed by none in this region except those of the tegmentum proper. Fibres from the fasciculus longitudinalis medialis may be easily seen entering it—while many fibres from the surrounding formatio reticularis connect with it. No individual divisions of the hypoglossal nucleus were recognisable.

The nucleus abducens is found in its typical relationship to the genu of the nervus facialis and the fasciculus longitudinalis medialis. The dorsal tegmental bundle of SCHÜTZ, which lies dorsal to it in the ventral grey, is enlarged and connects it closely with the nucleus of the third and fourth nerves. In spite of the fact that in Platypus the eyes themselves are exceptionally small, the connections between their motor nuclei are, on the contrary, exceptionally large.

The nucleus ambiguus was identified with some difficulty. It is not as prominent a group of cells as reported in Echidna (KAPPERS, 1920, vol. 2, Abs. 1, fig. 275, p. 527), or as the author has seen in the opossum. No fibre connections were identified. The nucleus is what WINKLER calls the nucleus ventralis of the ninth, tenth and eleventh nerves. Its position and relation to other motor elements appear similar to other mammals described. The ill-defined dorsal motor nucleus of the vagus contains small cells lying dorso-medially within it and large cells ventro-laterally. In its anterior end, the latter cells are separated from the former by connective tissue septa in such a way that the large cells have the appearance of a separate nucleus. This cell-mass resembles the large celled nucleus in the same relationship, described by WINKLER as the dorsal nucleus of the ninth. KOELLIKER labels it the nucleus of the glossopharyngeal, and in the text says that fibres from the tenth also enter it. The same group of cells was seen in the medulla of Echidna, but they are not separated from the tenth nucleus proper. It is possible certainly that not all of the motor cells of the ninth root have migrated ventrally in monotremes; and that this is further evidence of the relation of monotremes to birds. In all other mammals, the innervation of the pharynx and larynx musculature has migrated ventrally. It is quite impossible to think that these large cells could be cells of the nucleus salivatorius inferior, although the cell components of this latter nucleus were unidentified.

In Ornithorhynchus, the seventh motor nucleus is not only separated into a dorsal and a ventral cell-group, but the dorsal is sub-divided again. If, however, these two dorsal nuclei be projected upon the dorsal surface of the medulla as one nucleus, the rostro-caudal extent of the combined dorsal masses and that of the ventral are approximately the same. This is quite unlike the lateral projection of these two nuclei given by KAPPERS (1920, vol. 2, Abs. 1, fig. 264, *a*, p. 514) for Echidna. In KAPPERS' drawing the dorsal nucleus is quite insignificant and placed more cephalward than the ventral.

Also when a photograph of these two nuclei is examined (KAPPERS, 1920, vol. 2, Abs. 1, fig. 276, p. 531) little difference can be seen in the size of cell characteristic of the two groups. Such also is the finding in Platypus.

KAPPERS states that the ventral motor nucleus of the facial nerve generally migrates ventrally to lie nearer either the sensory nucleus of the trigeminus or the superior olive. In this beast (Platypus), it appears that the migration is toward the superior olive. Because of this we would anticipate that movement of the ear in the direction of sound would be of great importance. But there is no external ear; the external auditory meatus has no outer indication of its position. BOAS and PAULLI (1908) think the outer ear cartilage is embedded in what appears to be platysma, although RUGE (1895, fig. 29) pictures two minute muscles as the auricularis posterior and mandibulo-auricularis. Certainly the muscles of the ear cannot explain the position of the nucleus facialis ventralis. Any one would anticipate that it would lie nearer the trigeminal nucleus.*

No differentiation was found within the ventral nucleus in spite of its size, so that the generalised condition of the facial muscles is reflected in the nucleus itself. The musculus sphincter colli is thick and crosses the ventral surface from the pectoral girdle to the base of the mandible. Its fibres are heavy and coarse and uninterrupted in the midventral line. BOAS and PAULLI (1908) described the platysma as extending from the forelimb to the angle of the mouth, the greater part lying below the ear opening. The caudal parts are found to end in the skin ventrally and the cephalic parts are inserted on the maxillary bone. A few strands of muscle, the orbicularis oculi (fig. 22, p. 129) and small buccinator (fig. 30, p. 141) were pictured by RUGE (1895).

It is possible that the two dorsal nuclei are the origin for the secretory nerves to glands of the head other than the parotid; these dorsal nuclei would then consist of the effector neurones of the nervus petrosus superficialis major and the chorda tympani. These nuclei may be similar to the nucleus salivatorius superior, found by YAGITA and HAYAMA (1909), but the cells therein appear to be too large for visceral effector cells and too numerous. Of course, it is altogether possible that many of the cells destined for the facialis musculature lie in the dorsal nucleus. That possibility perhaps would explain both size of cell and differentiation into two dorsal nuclei.

When the *nuclei gracilis* and *cuneatus* of Platypus are compared with those of Marsupials, such as Didelphys marsupialis or Didelphys virginiana, the size of these two nuclear masses is noticeable. The *medial lemniscus* is easily identified by its peculiar brilliant bluish staining in the Weigert sections and is therefore easily followed to the thalamus, where it is lost in the ventro-lateral and posterior part of the nucleus ventro-

---

* In spite of this seemingly negligible differentiation of muscles of the external ear from the generalized platysma, BURRELL (1927, Plate 6, lower photograph) pictures a peculiar fold of the skin in a "female platypus listening intently," adding to that caption "note end of top lid 'cocked' for catching sound." Even this apparent functional adaptation does not adequately explain the position of the ventral nucleus of the facial nerve unless, of course, the positional adjustment within the brain stem is less conservative than the process of differentiation of special muscles from the group mass.

lateralis. The bulk of this system is unusually large for an animal of the bodily size and phylogenetic position of Platypus. Such a peculiarity accounts in part at least for the hypertrophy of the posterior division of the ventro-lateral nucleus of the thalamus. When these nuclei are looked for in those reptiles, which have found their way into the literature, we find that it is only the gracilis which is at all developed.

Indeed in order to find an animal (among those studied) with such a prominent system subserving bodily muscle sense, we are obliged to skip the Metatheria and to discover it among the Eutheria. Further, there is an apparent augmentation of the lemniscus rostral to the region of the nucleus gracilis and cuneatus, for which the writer cannot account either in the structures of the brain stem of Platypus itself or by reference to any known homology elsewhere. The proportional enlargement of this system may be interpreted in a certain sense, as a correlation with the excessive development of the general cutaneous sensibility supply for the head, requiring a finer muscular adjustment as a response to its stimulation. This prominence of bodily muscle sense may be thought of in connection with the only muscle sense nucleus so far definitely identified, the mesencephalic nucleus of the trigeminal nerve. That hypertrophy, in this case, cannot be excused by an unusual development of the motor fifth musculature, nor with that of the body in general. This lack of co-ordination between bulk of musculature and apparent enlargement of the muscle sense systems in this brain argues that these centres increase in relative importance, not hand in hand with greater numbers of muscle fibres and larger muscles, but rather, perhaps, as an indication of a possible finer adjustment for those already developed.

As in other animals, some of the fibres mingled with the decussating medial lemniscus are arcuate fibres which pass with the direct fibres *via* the corpus restiforme to the cerebellum.

Co-ordinating system of the medulla.—One of the many remarkable things of this curious brain is the relative importance of its formatio reticularis system. The tegmental zones of the thalamus, of the midbrain and of the medulla appear to be connected by large, heavily myelinated nerve fibres. Among them, in particular in the medulla, are many large motor-like cells, containing large NISSL bodies—cells larger than the cells of any motor nucleus. For the most part they are dispersed through the formatio, with no definite distribution, resembling therefore the same cells found in lower vertebrates and lower mammals. In three instances, they are accumulated in what we might call nuclei, simulating those found in the cat more than in other mammals so far described. They are first, the nucleus reticularis lateralis, lateral to the main body of the olive ; second, a triangular nucleus, peculiar to Platypus, the nucleus reticularis triangularis, marked X by ZIEHEN (fig. 27, p. 853, 1908) ; and third, the nucleus reticularis raphés, medial or ventral to the inferior olive. The third nucleus mentioned could be divided into two portions, a superior and an inferior in reference to the inferior olive. It is quite possible that the cell masses, labelled nuclei arcuati in fig. 70, *c*, may not belong to the arcuate system. Certainly they are a part of the differentiation of definite nuclei out of the formatio reticularis and appear to link the medulla with the cerebellum rather than to act as an intermediary between divisions of the formatio reticularis of the brain stem.

The inferior olive.—The inferior olive of Ornithorhynchus provides an interesting comparison to that of Echidna, described in beautiful detail by KOOY (1916). Using the comparative data which he presented in that excellent monograph, the various parts of the body in Platypus assume a new significance. KOOY notes that one of the chief morphological differences between the inferior olive of birds and that of mammals above monotremes is the position of the principal nucleus. In birds that nucleus is ventral, and in the majority of mammals it is ventro-lateral. The topographical relation of the palæo-olive (the medial and the dorso-lateral) to the neo-olive (the ventro-lateral) in both Ornithorhynchus and Echidna is similar to that characteristic of birds. Consequently, although neither nucleus of the palæo-olive shows any extraordinary characteristics, the principal olive is comparatively poorly developed—a finding to be correlated with the lack of morphologically independent lateral hemispheres in the cerebellum.

In comparing the relative size of the thin parts of the inferior olive of Platypus with those of Echidna, the dorso-lateral nuclei are found to be almost similar. The medial nucleus of Platypus is a little more developed than the same cell mass of Echidna, and the ventral or principal olive is slightly more massive in Echidna than in Platypus. Interpreting the use of body musculature from the relative olivary development in the two monotremes, we would conjecture that limb movements were more important to Echidna, and that trunk movements were of greater use to Platypus. However, if the medial and ventral nuclei are compared in Ornithorhynchus itself, we would conjecture that neither limb nor trunk movements played a dominant rôle. This peculiarity of development may be explained by the life habits of Platypus. Spending most of his active, acquisitive life in rivers or creeks, he has something of a seal-like agility of movement in the water. Further, he is clever with his feet. The pads, which are used for swimming, may be pulled up and his claws then used for digging the thirty odd feet of driveway to his isolated burrow. When compared to Echidna, his movements are more varied because he can negotiate two different media.

In this connection it is interesting to note the difference in structure within the inferior olives of the aquatic mammals studied by KOOY. The Cetacea (*Turslops tursio*, FABR., and *Phocœna communis*, BROOKES) have tremendous medial nuclei and fairly well-developed dorso-lateral and principal olives ; and the Pinnipedia (*Phoca vitulina*) possess small medial and dorso-lateral nuclei and a principal olive very like the Carnivora. These topographical findings are delightfully correlated with the functional emphasis placed upon different muscle groups. The seals have retained marked control over the manipulation of the flippers, while in the whales that control is lost, and trunk movements are dominant. This anticipated difference in the relation of development of the nuclei of the inferior olive within such widely separated groups of aquatic mammals, as whales, seals and Platypus, makes the similarity of certain nuclei related to the midbrain portion of the fasciculus longitudinalis medialis all the more intriguing.

In the inferior olive, the cells, small (much smaller than those of the nucleus arcuatus and nucleus raphés) and spindle shaped, follow the description of KOOY. In the animal here studied they show no definite distribution. Also no region could be made out for the reception of particular fibre systems or for their departure.

Just as KOOY describes for Echidna, the principal olive of Platypus is better developed at the frontal pole, the medial part of the olive extends further rostralward, and caudally the two parts of the palæo-olive cease about simultaneously.

The Cerebellum.

The outlines given by such workers as INGVAR, ELLIOT SMITH, BRADLEY or BOLK, for the comparative morphology of the cerebellum, appear simple enough when applied to the forms used for their studies, but when their various criteria for critical landmarks are applied to other forms, some difficulty is experienced and a few of the reasons for disagreement appear.

Because Platypus is so closely akin to the lower vertebrates the writer thought it wise to study the cerebella of such brains as those of the bird, the Echidna and the opossum. The cerebella of the common laboratory pigeon (fig. 87), the Virginia opossum (fig. 86) and Echidna (fig. 85) were drawn and accompany this discussion. When the medial sagittal sections of the cerebella of these four brains are examined, it will be noticed that only in the cerebellum of the opossum is the fissura prima the deepest fissure. In Platypus the deepest is the fissura secunda ; in the pigeon it is INGVAR'S fissure Y (fig. 87, *b* ; *f.s.p.*) and in the Echidna the critical furrow (fig. 85, *f.p.*) lies just anterior to what appears to be the declive. However, if this criterion of depth is slightly modified for Echidna, Platypus and the pigeon so as to define the fissure prima not as the deepest fissure but as the deepest fissure toward the anterior pole of the cerebellum, then the criterion for the fissura prima applicable to the Metatheria and Eutheria, can be extended to lower forms. Now if the morphology of the lateral surface is studied this same fissure will serve to form the posterior boundary of the anterior lobe, and therefore a certain conformity is reached.

In the case of Ornithorhynchus, the deepest posterior fissure was taken as the fissura secunda, using the nomenclature of ELLIOT SMITH. Anterior to this fissura lies the pyramis. According to his classification, the pyramis should be continuous laterally with the dorsal area of the paraflocculus. Certainly the fissure anterior to this group of folia, the sulcus prepyramidalis, is continued further laterally into what seems to be the stem of the paraflocculus. On the other hand, in Echidna, this deepest fissure, as seen in the medial surface, bears no correspondence laterally to the stem of the large spherical flocculus, so that if the first folia to be named the pyramis must be continuous with the paraflocculus, this first folia-group must lie posterior to the fissure marked *f.s.p.* (the sulcus prepyramidalis). In the pigeon the homologue of this sulcus, as given by INGVAR and as would appear to the writer, is sulcus Y. However, although it is the deepest in medial sagittal section it is not continued into the paraflocculus. INGVAR shows that this folium between his fissures 4 and 2 sometimes does and sometimes does not take part in the actual lateral invagination of the paraflocculus. In fig. 39, on p. 290, he shows such a lateral extension of the pyramis forming a part of the paraflocculus in *Columba domestica* (compare with this his fig. 40, sulcus *y*, *Oligyps auricularis*, p. 291). It is possible that there may be some variation here between the domestic dove as known in Holland and the laboratory pigeon in America. In the descriptive section, the writer has already noted that there are marked variations in this region even in the same brain, although its medial attachments do not vary. In the opossum, the part labelled pyramis (*pyr.*) forms with the uvula a thin strip of tissue which attaches itself to the paraflocculus-flocculus body.

In passing from one to the other of the four cerebella as seen from the lateral surface, the middle lobe of both Echidna and Platypus resembles that of the pigeon more than it does that of the opossum. There are no lateral hemispheres. The folia are continued latero-ventrally until they merge into a band, the pons, like the sides of a corrugated bonnet, ending in strings and tied around the medulla. Only the opossum shows any structural character which might be interpreted as a means of differentiation between medial and lateral parts of the middle lobe of the cerebellum. Although this lobe shows what might be taken to be a greater differentiation, nevertheless it does not contain more tissue than the same region so formed in Echidna or Platypus—a morphological differentiation unaccompanied by increase in size. Indeed, the middle of either of the monotremes shows a higher degree of foliation than does this marsupial. Such a difference could be correlated with the fact that the monotremes use their limbs in a bilateral manner, while the opossum is able to manipulate his hand-like paws unilaterally.

If we apply the criterion for the identification of the pyramis as the first cerebellar folia to be continued laterally into the paraflocculus, then the fissure anterior to it will be the sulcus prepyramidalis and the one posterior, the fissura secunda. We have, therefore, the landmark of the anterior boundary of the posterior lobe of ELLIOT SMITH, or if we include the pyramis, then the posterior lobe of INGVAR. Certainly, when this region is examined in the opossum and in the pigeon we are struck with the advisability of INGVAR'S classification, because in the first embryonic lobulation and the subsequent adult morphology, the pyramis falls more naturally as a lobule to be placed with the uvula and nodulus. In Platypus this relationship, although as clear, falls more easily into ELLIOT SMITH'S because the fissura secunda is so deep, although it may be added that the termination of this fissure laterally in the paraflocculus is not quite as clear. This particular anatomical arrangement stands midway between the situation discovered for the pigeon and that for the opossum. In Echidna, the second deep fissure (*f.s.* or *Z*, figs. 85, *a* and *b*), posterior to the deepest posterior one, marks the anterior boundary of the region which, followed laterally, is coincident with the paraflocculus. The flocculus is connected to the three folia posterior to the fissura secunda

In the opossum this connection is confined to the next two instead of three and in Platypus to the two ventro-anterior to the sulcus uvulo-nodularis.

The ventral limb of the auricle in the pigeon is the lateral limb of the nodulus. In the opossum the pyramis and next two folia are continued as a thin band laterally, leaving but one small folium with a thin cord-like lateral connection. Only the extreme posterior leaf in the Echidna has no lateral continuation; but in Platypus the last four have none. The question is now, wherein exactly lie the homologies between the areas as outlined for those four animals? If we turn to the scheme as presented by ELLIOT SMITH, the whole of the posterior lobe is attached by a thin cord to the posterior paraflocculus and the flocculus. If INGVAR'S scheme is examined, the pyramis and uvula are connected with the paraflocculus and the nodulus with the flocculus. This ground-plan is similar to that given by BRADLEY, his folia E being continuous laterally with the flocculus. BOLK says that the anterior part of the paraflocculus is attached to the pyramis—*i.e.*, C, and the flocculus to the nodulus, or "*a*." In Ornithorhynchus the fissure which marked the continuation of the posterior limit of the paraflocculus medially, was named the sulcus uvulo-nodularis. On such a criterion thus sulcus was also labelled ln Echidna. Although the connection between all the medial folia and the paraflocculo-flocculus is cord-like in the opossum, this sulcus was identified as the one lying between the two folia posterior to the fissura secunda, showing this attachment. Certainly, there are more medial folia in the nodulus of Platypus than in the other animals here examined. The spherical island of tissue (fig. 47, *e*) is too far posterior to be called the tonsil. The writer found nothing resembling it in closely related brains. The difference in development of lateral parts of the posterior lobe in Echidna and Platypus challenges an explanation. INGVAR found in general that the lobulus flocculus was more developed in water mammals than in land mammals; just the reverse occurs, however, in this case.

In large birds, INGVAR ascertained that the anterior lobe of the cerebellum was larger and held four or more folia, while in small ones it held often only two. Certainly, in all four brains presented here, the anterior lobe is quite large, comparatively speaking. The trigeminal musculature in the opossum and the facial in the Echidna and Platypus are quite unusual in their development. The body of opossum is larger than of either of the monotremes although its cerebellum is about the same in size. The difference lies in the development within the cerebellum. INGVAR'S generalisation of larger cerebella for larger muscular bulk will not hold here. This is no criticism of the generalisation, however. There are other generalisations which hold true for all other mammals, with the exception of these two eccentric monotremes. It would appear then that the cerebellum of the monotremes resembles in general morphology the anterior and middle lobes of birds, in that all are simple midline structures with no lateral development; and it would also appear that the posterior lobe, whose reputation for conservatism in the mammalian phyla is questioned by no investigator of this organ, is the one part to show definite mammalian characters. When they are compared to the opossum we easily see that the middle lobe shows greater difference—although in justice to the paraflocculus and flocculus in all three mammals here delineated, especially in Platypus itself, it is the lateral region of the posterior lobe which shows the greater variability.

The instability shown by the lateral parts of the posterior lobe of these four cerebella, is more arresting when they are viewed, alongside the cerebella of the higher mammalian orders. Viewed thus, the posterior lobe appears to reach a more or less constant morphological equilibrium. This equilibrium may be more apparent than real. Indeed, in all probability, the variability of this region is obscured by the greater changes which are demonstrable in the middle lobe. Nevertheless, in these four more ancient forms the striking differences between them lie in the phylogenetically older posterior lobe. INGVAR'S study of degeneration of vestibulo-cerebellar connections may offer a tentative explanation. A greater part of the direct vestibular fibres to the cerebellum end in the cortex of the nodulus, uvula and flocculus, and, of course, in the anterior lobe, particularly the lingula. These fibres are the oldest of all cerebellar afferent systems, being present and entering the auricle of fishes. It is possible then, that the variability under consideration might be correlated with that of the vestibulo-cerebellar connections, although such a consideration excludes an explanation of the greatest variable of the posterior lobe, the paraflocculus. There is at the present time no adequate explanation for this latter inconstancy.

The nuclei of this cerebellum are similar to those found in other lowly mammals—a medial and a lateral. The vestibular fibres, together with those from the nuclei of BECHTEREW and especially of DEITERS, may be traced into the medial one—and this medial nucleus appears, therefore, to be homologous with the nuclei tecti. The writer failed to discover a differentiation within it into a large-celled and a small-celled nucleus as reported for birds by VAN HOEVELL. Whether or not the fibre-content of the corpus restiforme contributes any collaterals to the medial nucleus as the corpus restiforme passes into the commissure of the cerebellum, this material did not reveal. However, these cerebellar nuclei are connected between themselves by a commissure of their own. There is no doubt about the connection for the lateral nucleus, as it is easily seen to be the origin of the efferent system, going to the midbrain, thalamus and tegmentum of the midbrain.

The attempt made to prepare a silver impregnation of the cerebellum of a brain belonging to Prof. WATSON was not successful. The preparation demonstrated only that the Purkinje cells cut the cortex into the traditional molecular and large granular layers, that there were climbing fibres on the Purkinje cells, that axones of basket cells occurred around the cell bodies of those cells, that many fibres ended about the ghosts of cells in the granular layer, and that there were also many ghosts in the molecular layer. By projecting this cortex by means of a camera lucida beside that of man it was found that its thickness was half as great—with no difference at all in comparative distribution of the layers within. In other words, these layers are twice as thick in man as in Platypus. At no place were collaterals from the Purkinje cells seen—an evident failure in technique. Nevertheless, Platypus appears to have a typical mammalian cerebellar cortex; although the preparations available do not offer any solution for the intrinsic relations of the incoming and outgoing fibres.

There was no peculiarity in the corpus restiforme content, fibres apparently from the cord, with additions of those from the olive, appearing to be crossed and uncrossed; the same is true of those from the nuclei gracilis et cuneatus. These are augmented medially by the vestibulo-cerebellar systems and the trigeminus. The fibre complex of the corpus restiforme forms the most massive connection of the cerebellum with other regions. The brachium conjunctivum appears to contain only efferent systems. The localisation of the entrance of the ventro-spino-cerebellar systems was not ascertained. In the midline of the anterior medullary velum three separate tecto-cerebellar systems enter (described in detail under the midbrain)—one from the optic tectum, one from the region of origin of tecto-spinal and bulbar systems, and another from the region about the mesencephalic nucleus of the trigeminus.

There are two noteworthy features in the afferent connections of the cerebellum in Ornithorhynchus—possibly not actually peculiar to this animal but only developed in it to an unprecedented degree—namely, the connections from the lateral nucleus of the sensory fifth and that from the mesencephalic nucleus of the fifth. In so far as it is permissible to draw a functional analogy from other animals, the mesencephalic fifth should be a nucleus of muscle sense and as such should be intimately related to the cerebellum. There is no previous report in the literature of mammalian brains which the writer could discover of an actual connection similar to this, although since the first report of this finding (March, 1925) TSAI (1925) has demonstrated a feeble tecto-cerebellar tract in the opossum. WINKLER, as reported elsewhere, believes a part (the lateral) of the sensory fifth serves this same purpose. His criterion is based upon the terminals of cells in that region being the same as those of the medial lemniscus. Such a finding, if it be a fact, would allow this connection a proprioceptive function. The chief tecto-cerebellar systems originate from the midbrain layers predominantly optic and probably would aid in the maintenance of tonic influence upon muscle groups in response to stimulation of the second nerve (see SCHIMAZONO (1912) in the bird).

The writer could identify none of the direct efferent systems outlined for birds by FRENKEL (1909) as the cerebello-spinal or bulbar tract, nor could a floccular commissure be demonstrated.

The pons, although it is small and insignificant in both Platypus and Echidna, is not as large as their respective cortexes might seem to warrant. Their size may be correlated with the negligible lateral hemispheres of middle lobe.

As a whole, the cerebellum shows many marked avian and mammalian characters—so that the place of Platypus in the phylogenetic scale is easily recognised as reflected in this organ. In other parts of this brain such a relationship will not be so clear.

The Midbrain.

The gross architecture of the tectum of Ornithorhynchus is definitely mammalian. The posterior colliculus has emerged and lies on the surface. It is mainly concerned with the lateral lemniscus and the medial geniculate body although some of the tecto-bulbar tracts appear to originate within it. The typical connections of the medial part of the superior colliculus separate themselves into a rostral and a caudal division. The rostral division is bound to the cerebellum by three definite tracts—the dorsal and intermediate from the third and fourth layers of the tectum, Lage der Endbüschel des Opticus, the ventral from the neighbourhood of the mesencephalic nucleus of the trigeminus. These three tracts suggest a midbrain optic and proprioceptive correlation with the cerebellum. HUBER and CROSBY (1926) found no tecto-cerebellar fibres in the alligator. TSAI (1925, *b*), however, described a small fibre system in the opossum. It is unfortunate that their terminations within the cerebellum of Platypus cannot be traced, because as systems they are the largest to be found in any mammal so far considered in the literature. Further, the tracts from the "optic" layers suggest correlation with the prominent systems of the superior and medial longitudinal fasciculi as being a part of an excellent mechanism for motor adaptation to a visual sense none too well developed itself. This high differentiation on the motor side beyond a sensory elaboration is not usual. The tecto-spinal system from the sixth layer is rather more confined (if the dorsal tegmental decussation be a just criterion for its limits) than the tecto-bulbar which has its origin throughout the whole of the fifth layer. The optic tract is difficult indeed to trace in this material, but consultation of younger stages lends support to the assumption that the tract itself connects with KOELLIKER's third and fourth layer.

The anterior connections are thalamus-ward, following in outline, though without the richness of detail, those described by HERRICK (1917) for Necturus and by HUBER and CROSBY (1926) for the alligator. The older parts of the diencephalon (the habenula, the nucleus pretectalis, the subthalamus and the hypothalamus) receive the majority of the fibre paths (crossed and uncrossed pathways); the medial and anterior nucleus, the lesser number. Such fibre relationships allow for association of all impulses converging in the tectum of the midbrain—sight, hearing, general cutaneous sensibility and probably proprioceptive sense—not only with the same impulses in the thalamus but more particularly with the older sensory receptive areas of the thalamus, and for discharge into motor centres (*i.e.*, into the subthalamic nuclei, lateral and dorsal, and into that receptive wilderness of the hypothalamus).

In the analysis of the tegmentum, three groups of connections appear—first, the dorsal co-ordinating systems of the fasciculi longitudinalis medialis et superior; second, those which pass anteriorly, the tegmento-thalamic and the tegmento-cerebral; and third, the posterior or descending motor pathways originating for the most part anterior to the midbrain.

The two longitudinal fasciculi are unusually large in an animal whose small eyes appear to play such an unimportant part in its somatic economy. However, the great agility (*i.e.*, rapid co-ordinated movement) may be reflected in their numerous systems. Although there is a smallish hippocampus and an insignificant lobus pyriformis and tuberculum olfactorium, nevertheless a large ganglion interpedunculare and ganglia tegmenti dorsale et ventrale (Edinger) appear in the midbrain, connected by many bands of fibres. Besides its relatively large size there is little that is unusual in the medial longitudinal fasciculus, except a definite origin in the posterior part of the nucleus dorsalis subthalami and the lateral nucleus of the subthalamus, the field of Luys and a connection with a nucleus in the central grey, anterior and dorsal to the oculomotor nucleus, specially designated the "nucleus of the fasciculus longitudinalis medialis." Undoubtedly, some of the fibres which compose the fibre bundles lateral to this fasciculus, have their origin in the nucleus of the posterior commissure and the nucleus interstitialis and may contribute some fibres to the fasciculus itself.

In the medulla, the fasciculus makes the traditional connections with the vestibular system and also with the large motor nuclei, like the tenth and twelfth. Caudal to the region of the latter it enters the ventral fasciculus proprius. Tsai (1925, *b*) found the posterior portion of the fasciculus dispersed in a similar way in the opossum, but with its anterior limit at the level of the commissura posterior. Muskens (1914) describes for the cat the origin of the innermost bundles of this fasciculus from the nucleus of the posterior commissure and from the interstitial nucleus of the tegmentum. Riese (1924, *b* and 1924 *c*) found in Delphinus and Phocæna a nucleus in the posterior part of the hypothalamus which he called the anterior nucleus of the fasciculus longitudinalis medialis—a nucleus not at all similar to the lateral nucleus of the subthalamus in Platypus, because of its lack of striatal relations, but rather like the caudal part of the nucleus dorsalis subthalami. On the other hand, no fibres from the lateral lemniscus were described as entering this fasciculus, as Tsai found in the opossum (1925, *b*, p. 243). No connections with the sensory fifth are discernible in this material, although *a priori* they would be expected and might be similar to those suggested by Huber and Crosby (1926) for the alligator.

The other longitudinal fasciculus, the superior, which in Platypus lies in the grey matter ventral to the aqueduct in the midbrain and to the fourth ventricle in the medulla, is characteristic (as far as the writer knows) of mammals. It appears in Platypus as a co-ordination mechanism between the eye-muscle nuclei and the ganglia tegmenti dorsale et ventrale. It is continued into the medulla as the dorsal tegmental bundle of Schütz. Undoubtedly this is a part of the system, so well described by Winkler (1918) in the rabbit and man, which forms a correlation and co-ordination mechanism between the sensory divisions of the vagus and glossopharyngeus, their motor nuclei, the hypoglossus, and the formatio reticularis nuclei of the midbrain.

The tegmentum of Ornithorhynchus is closely related with all parts of the palæothalamus by fibre systems whose direction of conduction cannot be determined, yet whose connections are unmistakable. The writer could distinguish no specialised tegmental nucleus like the entopeduncular described for Varanus (DE LANGE, 1913) and for birds (KAPPERS, 1921, ii, p. 879). The nuclei medialis et anterior thalami and the nucleus pretectalis probably discharge into the grey of the reticular formation of this generalised region. Two of the subthalamic nuclei, the dorsal and the ventral, together with the ventricular grey of the hypothalamus, send into the reticularis definite fibre bundles, apart from special peduncular tracts. Either these systems are more prominent in Platypus or other writers have not thought them worthy of description. TSAI (1925, *b*) records the medial fibres in the fasciculus medialis telencephali and a mammillary descending tract, which may end in the interpeduncular nucleus or in the reticular substance of the tegmentum. HUBER and CROSBY (1926) describe thalamo-tegmental connections as a part of the lateral division of the basal forebrain bundle in the alligator. These exaggerated connections of the dorsal and ventral thalamus with the recticular substance of the midbrain are to be correlated with the large cells found throughout the generalised intrinsic reticular formation in Platypus.

Closely allied systems arising from the ventral part of the thalamus and passing into the peduncle to distribute themselves to a similar generalised neuropile in the medulla are the peduncular tracts, characteristic of all mammalian brains. The only one which is peculiar to Platypus is that one which takes its origin from the nucleus pretectalis. Three of the four subthalamic nuclei, the hypothalamus, and the corpus mamillare are the sources of these important tracts. Their bulk is augmented in the medulla by the tract which arises in the ganglion interpedunculare.

The ventral thalamus of HERRICK'S descriptions for amphibians (the subthalamus here) and the hypothalamus discharge directly into the tegmentum of the midbrain and medulla ; while the older parts, the dorsal nuclear group, are directly connected with the tegmentum only. It is possible, of course, that the latter connection is afferent. In that case the generalised sensory part of the reticular substance is in close relation with the incoming impulses from the anterior part of the brain.

The cerebellar mesencephalic tracts, other than the tecto-cerebellar systems, are those which have their origin in the lateral cerebellar nucleus and their termination in the thalamus, in the tegmentum and in the nucleus ruber. They are the mammalian counterpart of the tractus cerebello-tegmentalis mesencephalicus of HUBER and CROSBY'S (1926) description of the alligator or the brachium conjunctivum anterior of KAPPERS' (1921) review of reptiles. Certainly they hold the same relation to the cell-masses of the nucleus ruber which VON MONAKOW (1909) has described for the cat and dog and even for man, because after their decussation (the decussation of the brachium conjunctivum of man) they pass medially to the nucleus magnocellularis of the red nucleus to end in the nucleus parvocellularis (MAGNUS, 1924).

The red nucleus itself, although on the whole not as discrete a body as found in the common laboratory mammals, nevertheless may be said to have emerged in Platypus from the tegmental formatio reticularis as a motor nuclear mass characteristic of mammals. The large-celled portion, the origin of the tractus rubro-spinalis, is posterior and medial, a typical position found in all forms from reptiles up. Its small celled part is more scattered in a triangular position, in the anterior tegmentum, than is the case in the rabbit, cat or dog. It is into the small-celled part, as is to be expected, that the striatum and cortex discharge. And if Platypus' physiology is as truly mammalian as its morphology, the anterior nucleus parvocellularis could be removed without causing the decerebrate rigidity of the SHERRINGTON (1897) and MAGNUS (1924) descriptions.

The substantia nigra makes its initial appearance in Ornithorhynchus as a separate part of the tegmentum and receives fibres from the striatum and the ventro-lateral part of the cortex. It is probably connected with the tegmentum and the hypothalamus.

The substantial ganglion interpedunculare and the ganglia dorsale et ventrale tegmenti lead an observer to believe that in spite of restricted development of olfactory sensory receptive centres olfactory stimuli are of great importance in the reflex motor responses of this beast. Not only are these centres unusually large but their interconnections (as has been previously noted) are easily traced. Especially is the differentiation into an anterior and posterior part within the ganglion interpedunculare worthy of note, as well as the number of fibres connecting the latter with the dorsalis Längsbündel of SCHÜTZ.

The long medial tongue-like nucleus, lying cephalward of the oculomotor nucleus in the midbrain, has no relationships discernible in this material and no recognisable morphological homology, except, as suggested by KAPPERS (in a private communication), that such a nucleus is found in a similar position in the elephant. The only character which the two beasts share is the peculiar development of the nose (soft, flat, beak-like proboscis) of Platypus and the trunk of the elephant. Such a correlation, however, lies only in the imagination of the writer.

At the present writing it appears impossible to homologise the nuclei of the oculomotor nerve of Platypus with those in the classical descriptions (KAPPERS, 1920, vol. 2, p. 549; BROUWER, 1918; HUNTER, 1923). There is in Ornithorhynchus no need for a nucleus of convergence, and yet there is a slender medial group of cells placed rostrally, whose axones may or may not contribute to the nerve trunk. The fact that the majority of the axones of both the posterior lateral and antero-lateral components decussate is slightly confusing. The medial dorsal division which lies quite cephalward may be the autonomic or Edinger-Westphal nucleus, if position and relative size of cells be a criterion. But what part the longish nucleus, medio-ventral to the medio-dorsal cell-group, plays in the physiology of the third nerve, the writer cannot suggest.

Then, again, in Platypus in the fourth nucleus, lateral to the typical large motor cells, is a group of smaller cells whose axones join those of the larger. These smaller cells are like nothing else described in this region in any other brain. Of course, it is possible that they may be cells belonging to the ever elusive proprioceptive mechanism.

The commissures of the midbrain of Platypus were regionally divided into those of the colliculi (superior and inferior) and the posterior commissure itself. The commissure of the inferior colliculus, apart from the commissural fibres connecting the two bodies characteristic of all reptiles and mammals and the decussation from posterior colliculus to central grey and the medial mesencephalic nucleus of the trigeminus, is either an isolated example, or is a part of the commissure which may have been mixed with the decussation of the root fibres of the mesencephalic trigeminus, reported for the opossum by TSAI (1925) and for amphibians as a portion of the decussatio veli by HERRICK (1917). The commissure of the superior colliculus in Platypus is not, as reported by HUBER and CROSBY (1926) for the alligator, a decussation of all fibre layers, nor is it confined to the seventh layer as pictured by TSAI for the opossum. It probaby includes decussations between the tectum and the central grey and between the tectum and the tegmentum, resembling therefore slightly the commissura tecti mesencephali of Amblystoma.

The posterior commissure could be divided into anterior and posterior parts, the anterior division connecting the two nuclei pretectales of opposite sides and perhaps passing beyond, while the posterior or main body of the commissure runs between the two nuclei of the commissure, those of the nuclei interstitiales, and turns into the medial division of the fasciculus longitudinalis medialis. Two such divisions, described as dorsal and ventral, are characteristic of birds, and were found by HUBER and CROSBY in the alligator. These authors said that the dorsal division was a tectal commissure and the ventral, the posterior commissure. The dorsal may be similar to HERRICK'S commissura tecti diencephali, which furnishes a place for the decussation of the tractus tecto-habenulo-cruciatus which is contained in the pars intercalaris diencephalica—a nucleus probably comparable to the nucleus pretectalis. However, in Platypus the commissure in question passes through the midbrain.

HERRICK'S (1917) description of the posterior commissure in Amblystoma and Necturus identifies no discrete nucleus with it, but outlines it as a decussation between the optic tectum, the tectum of one side, and the tuberculum posterior of the other, together with the supposition that it may connect the tectum with fasciculus longitudinalis medialis. In the work on reptiles as adequately reviewed by HUBER and CROSBY (1926, p. 196), a definite nucleus of the commissure is described, similar to one found by others in Varanus and Chelone. Here the two nuclei as well as the nuclei interstitiales are related through the commissure, particularly the nuclei interstitiales through that part which turns into the fasciculus longitudinalis medialis.

Up to 1896, KOELLIKER'S review on the "dorsale Längsbündel" (Vol. 2, p. 438) gives the history of the interrelation of the fasciculus longitudinalis medialis, the posterior commissure and its nucleus, known then as that of DARKSCHEWITSCH. RAMON Y CAJAL (vol. 2, p. 493) describes a nucleus interstitialis as a terminal station of the posterior commissure. CAJAL further believes, as a result of studying silver impregnation preparations, that this commissure is formed by axis cylinders of the grey substance of the anterior quadrigeminal tubercle of the opposite side. However, in the cat, CAJAL thought that the nucleus of DARKSCHEWITSCH may be the origin of the fasciculus longitudinalis medialis. On the basis of these connections he concluded that " The commissura posterior is a reflex optic pathway destined to transmit visual excitations to the motor nuclei of the eye " (p. 494).

These rather indefinite morphological findings have been recently elucidated by the experimental degenerations of MUSKENS (1914, 1922) on the cat and the rabbit. From these studies, one may conclude that the commissure is not as much a commissure as it is a decussation. For MUSKENS found that fibres forming the lateral division of the fasciculus longitudinalis medialis cross in the commissure to end in the nuclei commissuræ posterioris et interstitialis. Fibres leave these nuclei to form the medial part of the fasciculus, the tractus commissuræ medullaris and the tractus interstitialis spinalis. MUSKENS found further that partial destruction of the globus pallidus is associated with homolateral atrophy of the nucleus interstitialis and of the nucleus of the posterior commissure. TSAI'S (1925) opossum material demonstrated that the nucleus of the posterior commissure is connected with the field of Forel, the hypothalamus, the tegmentum and the fasciculus longitudinalis medialis. To the nuclei discussed by MUSKENS, TSAI adds that of the fasciculus just mentioned ; topographically, this cell mass is the nucleus of DARKSCHEWITSCH, pictured by CAJAL. It resembles slightly the nucleus dorsalis in that fasciculus, noted by RIESE (1924) for *Phoca vitulina*, although it lies anterior to the oculomotor nucleus rather than dorso-lateral. Besides the nuclei just mentioned, RIESE (1924) describes under the name of corpus ellipticum in *Phoca vitulina* and *Delphinus delphis* a nucleus dorso-lateral to the nucleus of the fasciculus longitudinalis medialis, seen first by HATSCHEK and SCHLESINGER (1902) in the brain of the porpoise and named the corpus ellipticum. In both Phoca and Delphinus, RIESE describes a fibre connection such that impulses may be transferred via the H_2 bundle from the globus pallidus to the medial part of the fasciculus longitudinalis medialis. Further, RIESE found that the fasciculus longitudinalis medialis is smaller on the side of degeneration of the nucleus lentiformis in a human brain and that, in an eight-month fœtus, this system is already myelinated. The writer is able to corroborate the last statement. But in no instance was the writer able to discover what RIESE found, a direct connection for the corpus ellipticum with these systems although as a nucleus this body has the peculiarity common to the midbrains of the water-living mammals he described.

In Ornithorhynchus, the main body of the posterior commissure is connected with its nucleus and with the nucleus interstitialis, as found by both TSAI and RIESE, although both nuclei appear to be more extensive than in the opossum and water-living mammals. The posterior commissure contributes fibres to the medial part of the fasciculus longitudinalis medialis as typical of the mammals studied by MUSKENS and RIESE. Into this same division of the fasciculus longitudinalis medialis run fibres which RIESE has found to be strio-fugal. However, in Platypus it is the interstitial nucleus rather than the nucleus of the commissura posterior which sends a large bundle of fibres into the tegmentum, in such a manner that they could not be traced further than the lateral boundary capsule of the nucleus ruber. They may or may not be homologous to the fibres which TSAI says go to the field of Forel and the hypothalamus.

The position of the nucleus of the fasciculus longitudinalis medialis is similar to that given by TSAI for the opossum, and by the older workers such as KOELLIKER (1896) and CAJAL (1909) for the nucleus of DARKSCHEWITSCH,or for the dorsal part of the dorsal nucleus of that fasciculus by RIESE. The termination of the medial division of the fasciculus in what the writer has called the nucleus dorsalis subthalami lends slight support to the possibility that the caudal part of that nucleus may possess some similarity to RIESE's anterior nucleus of this fasciculus (1924, Abs. 3). Further, the lateral termination of the fasciculus in the nucleus lateralis subthalami is probably comparable to that found in the opossum between the nucleus of the posterior commissure and Forel's field H_2, although the lateral nucleus of the subthalamus of Platypus is more like the corpus subthalamicum of Luys than it is to Forel's field.

In Platypus, the corpus ellipticum, certainly connected with the nucleus pretectalis and probably with the nucleus interstitialis, possibly sends a few fibres into the medial part of the fasciculus longitudinalis medialis. Also strio-fugal fibres may perhaps penetrate it. If so, that nucleus would form a part of an extensive co-ordination system involving the vestibular nuclei, the nuclei of the posterior commissure, the nuclei interstitiales, the nuclei of the medial longitudinal fasciculus, the posterior commissure, the lateral and medial parts of the fasciculus longitudinalis medialis, the subthalamus and the globus pallidus—all nuclear centres and tracts known to have something to do with either posture or muscular co-ordination. The finding of the peculiar differentiation of the mesencephalic central grey, anterior to the oculomotor nuclei, places Ornithorhynchus with the porpoise, investigated by HATSCHEK and SCHLESINGER (1902) and with the seal and whale of RIESE (1924). That mammals so phylogenetically different as these should demonstrate such a great similarity in a single nuclear differentiation, with but one characteristic in common (namely, that of water living) makes the writer think that perhaps this nucleus, so closely correlated with postural and co-ordinating mechanisms, may have something to do with the midbrain reflexes of breathing.

Therefore, we find in the midbrain of Ornithorhynchus definitely mammalian structures ; but, on the other hand, the motor systems are larger than in many other mammals, reminiscent of a kinship with lower vertebrate forms, in particular with reptiles.

The Thalamus.

Although the description of the thalamus of Platypus followed rather closely the divisions given by Comparative Neurology, the discussion will be facilitated by its consideration in functional groupings.

The "optic" thalamus includes not only the dorsal and ventral lateral geniculate bodies, but also the nucleus pretectalis and a part of the lateral nucleus of the subthalamus. The optic tract of Platypus cannot be divided morphologically into definite diencephalic and mesencephalic branches, as was done for the opossum (TSAI, 1925) and for Echidna, although certain of these fibres as inconsequential bands may be followed to the optic tectum and lateral geniculate field of the fœtal brain. Those which enter the dorsal nucleus have not been followed in the adult with complete certainty in the material at hand. They appear to enter a longish nucleus upon the lateral surface of the diencephalon in the region of the medial nucleus and of the habenula. This longish nucleus lies lateral to the anterior portion of the optic tectum. A superficial horizontal layer of fibres connects the two, but this longish mass is not any larger than the ventral nucleus of the lateral geniculate body. WOOLLARD (1926) has substantiated the generalisation that the better the development of the retina, the more important the dorsal nucleus of the lateral geniculate body, and at the same time the greater the importance of optic radiations to the cortex. Although many fibres are observed leaving this nucleus and passing toward the cortex, the writer was not able to trace them to a part of the cortex which might suggest visual function.

The ventral nucleus in Platypus is small, with no definite structure as revealed by the Bielschowsky series, suggesting poor differentiation on the sensory side of this system. However, several small fibres in the medial side of the optic tract interdigitate with those of the basis pedunculi and end in the lateral part of the lateral nucleus (the corpus Luysii) of the subthalamus, thus constituting the tractus opticus accessorius anterior of BOCHENEK or the pars peduncularis tractus optici of WINKLER'S investigation on the rabbit. This tract enters the corpus subthalamicum (TSAI, 1925*a*, p. 206) in the Virginia opossum. Nothing of a posterior tract ending in the nucleus opticus tegmenti, medial to the substantia nigra region as described for the marsupial by TSAI (1925, p. 204), was observed in this beast, although a nucleus which answered this description topographically was figured. The writer has been unable to substantiate ZIEHEN'S identification of both the dorsal and the ventral lateral geniculate bodies.

But what is perhaps the most interesting from the comparative point of view is that some of the fibres of the optic tectum enter the nucleus pretectalis. Special cellular differentiation was observed in this nucleus. It is medial and ventral to what has the appearance of a diencephalic extension of the optic tectum. The nucleus is connected with the superficial layers of the cephalic portion of the tectum and with the dorsal part of the tegmentum. Fibres join it to the habenula, the medial nucleus of the thalamus, the dorsal nucleus of the subthalamus as well as to the dorsal lateral geniculate body and to so distinct a nucleus as the corpus ellipticum. Of the strio-thalamic bundle destined for the medial nucleus a few fibres enter the nucleus in question. In relative position and connection with tectum and habenula, the nucleus pretectalis resembles the pars intercalaris diencephali of Necturus (HERRICK, 1917, p. 230). In its relation to the optic tectum, its fibre relation to the tegmentum, but unlike in non-reception of the lemniscus system, as far as has been ascertained by the writer, the nucleus pretectalis of Platypus shows small resemblance to the same nucleus of the opossum (TSAI, 1925, *a*). In Platypus, this nucleus lies in the same relative position as does the nucleus lentiformis thalami in *Varanus salvator* (fig. 460, p. 860, KAPPERS, 1921, vol. 2, pt. 2) or as does the nucleus posterior thalami of NISSL in the *Onychogale frenata* (KAPPERS, 1921, vol. 2, pt. 2, fig. 481, p. 909). Its connections in Platypus are similar to those described for the nucleus pretectalis in Varanus by DE LANGE (1913, fig. 19), who thinks this nucleus is the equivalent of BELLONCI'S nucleus thalami posterior. From KAPPERS' account, the nucleus pretectalis and the nucleus spiriformis of birds must be similar to the whole body of the nucleus pretectalis in Platypus (*see* fig. 467, p. 873, KAPPERS, 1921). Again, the position and total connections of the pretectal mass in Ornithorhynchus are similar to the position and connections of the three nuclei described for the alligator by HUBER and CROSBY, 1926), namely, the nucleus pretectalis (figs. 11 and 12), the nucleus lentiformis mesencephali (fig. 10), and the "geniculate pretectale" of BECCARI (fig. 9). Such a nucleus has been pictured by WINKLER and POTTER in their atlases on the brains of the rabbit (1911) and cat (1914).

Had the writer been able to trace the secondary fibres of either the eighth or the fifth, it would have been possible to conjecture that this nucleus pretectalis of Platypus was indeed one for correlation of the optic with other sensory centres from the medulla —the anlage perhaps of the pulvinar (suggested also by TSAI for the opossum). The tecto-pretectalis tract suggests such a correlation. It is possible that the specialisation of this region as found in birds and reptiles presents itself with similar connections in this lowliest of mammals as a large generalised region, a step apparently in the early development of a highly specialised region for general sensory correlation. Certainly, in the thalamus of Platypus there is no other area which has this variety of fibre connections and presents such a good face for resemblance to that little understood region of the mammalian thalamus, the pulvinar. Indeed Platypus will probably manifest his ability for sorting worms from pebbles in some part of his brain. Upon such a conjecture, the finding of a relatively larger and more generalised area than that of the opossum is not surprising. It also suggests that BROUWER'S recent finding of little or no direct connection of the optic tract with the pulvinar in dogs, rabbit and monkeys has a phylogenetic significance. The connections of the dorsal part resemble those of the nucleus pretectalis, while those of the ventral emulate those of the nucleus posterior thalami, the nucleus lentiformis or of the nucleus spiriformis. It is similar in position to the nucleus posterior thalami (nuc. præbigeminalis) in the rabbit, which WINKLER by degeneration experiments has proved to receive some of the fibres of the tractus opticus (1918, vol. 1, fig. 23). The nucleus, the writer believes, is that which KOELLIKER labelled the nucleus dorsalis. Further study of well fixed Nissl or Golgi material alone promises the solution for this interesting bit of evolution.

The thalamus of the lemniscus systems occupies by far the greater mass in this part of the brain of Platypus. The crux of the discussion lies in the correct identification of the limits of the medial, lateral and central nuclei. The medial nucleus may be divided conveniently into an anterior spherical nucleus and a posterior elliptical one. In the main the anterior subdivision is connected with the striatum, the hypothalamus, the tectum and the tegmentum of the midbrain. The posterior definitely receives the trigeminal lemniscus. Following the nomenclature of VON MONAKOW (1899) the former would be the nucleus medialis A, or the Hauptkern of large cells, resembling in its connections the nucleus medialis of SACHS (1909) in the cat and a nucleus of the same name described by HUBER and CROSBY (1926) for the alligator, or the nucleus rotundus of Varanus (DE LANGE, 1913). The posterior subdivision of the medial nucleus is VON MONAKOW's medial nucleus B, the centre médian of LUYS as described by SACHS for the cat, the nucleus rotundus of HUBER and CROSBY, or the nucleus ventralis B of DE LANGE. This region would correspond to the termination of WINKLER's (1918) division of the trigeminal lemniscus—an ending which in part is in the ventral nucleus. A part of this lemniscus passes a little lateral and ventral with the fibres of the medial lemniscus. These fibres of the medial lemniscus turn posteriorly into the large caudal extension of the thalamus and would therefore identify this area as the nucleus ventralis of VON MONAKOW, WINKLER, SACHS, etc.

It is impossible to distinguish any divisions other than the one dependent upon cellular morphology because the relation of its several parts to the cortex is completely unknown. Probably HUBER and CROSBY's area ventralis would correspond to this nucleus ventralis. Certainly that area which is found dorsal to the boundary of the subthalamus and posterior to the spherical part of the nucleus medialis, is similar to the nucleus ventralis thalami C of DE LANGE. This leaves an area dorsal to the nucleus ventralis, lateral to the medial and the dorsal part of the lateral geniculate body, to be labelled nucleus lateralis, which is subdivided in the text into nucleus dorso-lateralis and nucleus medio-lateralis. Small fibres connect it to the surrounding nuclei ; large bundles, with the cortex. From this discussion, it would appear that in Ornithorhynchus the part of the medial nucleus which corresponds to the sensory fifth hypertrophy is the centre médian of LUYS, VON MONAKOW's medial B and the ventral nucleus, all of which together KAPPERS (1922) calls the " nucleus spongioides."

The anterior part of the medial nucleus is connected with the striatum, with the secondary olfactory centres, with the tectum and tegmentum of the midbrain, with the nuclei of the subthalamus and with the central grey of the hypothalamus. It is similar therefore to the nucleus of the same name described by HUBER and CROSBY (1926), to the rotundus of birds (KAPPERS, 1921, vol. 2, p. 876) and of reptiles (DE LANGE, 1913), to the nucleus medialis A of VON MONAKOW (1899) of cats and dogs, to SACHS' (1909) medial nucleus and to the main body as described for man by DEJERINE. It is probable that this part of the medial nucleus is the oldest phylogenetically. It is more constant in appearance and in fibre connections in the vertebrate phyla than the nucleus anterior, which in mammals is so closely associated with it.

In this beast, fibres connect the nucleus anterior thalami with the striatum, the secondary olfactory centres and the corpus mamillare. Fibres from the tectum may reach this anterior nucleus and undoubtedly it is connected with the nuclei lateralis and medialis. The anterior nucleus of Platypus is the nucleus dorso-medialis anterior of HUBER and CROSBY, the nucleus anterior of all other authors. These connections with the striatum have been demonstrated by SACHS and KINNIER WILSON (1914) for the monkey and by DEJERINE for man. The mammillo-thalamic connection fails in the alligator, although DE LANGE thought he found a homologous tract for Varanus. Certainly these nuclei demonstrate the generalisation of KAPPERS that the medial is relatively larger in crocodiles and lizards (and we might add alligators), in monotremes and marsupials, although it is not that part of the medial which is directly concerned with the trigeminal system. This particular medial nucleus perhaps may be the region of synthesis of tactile sensibility with smell, while the anterior correlates smell with other body sensibilities by way of its connection with lateral nucleus and, in higher mammals, with the nucleus caudatus.

The nucleus reuniens is exceptionally well developed in crocodiles and turtles, in marsupials (RÖTHIG, TSAI), rodents (CAJAL, SACHS), and ungulates (SACHS). It is also connected with the striatum. In Platypus a large commissure or, it may be, a decussation passes through it, but is not a part of it. The function of the nucleus reuniens is unknown, but probably is closely associated with that of the nucleus medialis.

Besides these nuclei of the dorsal thalamus, two of the subthalamus are connected with the antero-medial portion of the corpus striatum, the nucleus ventralis and the nucleus lateralis. These tracts are probably motor.

The Subthalamus.

The motor part of the thalamus, the subthalamus, has been described under arbitrary divisions—the nucleus dorsalis, the nucleus ventralis, the nucleus lateralis and the nucleus lateralis magnocellularis. The writer has been unable to discover in the brains of either lower vertebrates, such as reptiles and birds, or in those of closely-related mammals, such as marsupials, any exact homologies of these nuclei. Probably there is something similar to both in Platypus. The lateral group is undoubtedly the corpus subthalamicum of higher mammals, while the medial group may correspond to the better developed dorsal part of the hypothalamus in birds and reptiles. The nucleus lateralis subthalami resembles the mammalian field of LUYS in fibre connections with the striatum; the tractus strio-subthalamicus enters its dorso-lateral parts and it receives the tractus opticus accessorius anterior. But unlike the older general descriptions for mammals, the nucleus lateralis also receives fibres, probably indirectly, from the posterior commissure and from the optic tectum; and the nucleus contributes fibres to the fasciculus longitudinalis medialis. The nucleus lateralis magnocellularis of the subthalamus is similar to the field of FOREL in that it receives fibres from the striatum, and is dissimilar, in that it receives the olfactory projection tract of RAMON Y CAJAL from the lateral amygdaloid nucleus and from the lentiform. This lateral large-celled nucleus is medial and a little ventral to the nucleus lateralis, rather than lying dorsal at an angle of 45°, as shown for the opossum by Tsai (1925, *a*, fig. 9) or as customary in other mammalian brains.

The resemblance to the Forel's field then rests upon its striatal connections, for neither in position nor in relative size of cell is it similar. In their atlas of the cat's brain (fig. xii, *a*), Winkler and Potter (1914) have pictured a group of cells labelled *h.a.* (the nucleus hypothalami medialis) lying dorso-medial to a nucleus, which, in turn, lies dorsal to the medial part of the basis pedunculi, set thickly with small cells and constituting the nucleus proprius pedunculi cerebri. Dorsal to the latter nucleus and medial to the corpus subthalamicum is the (*h.b.*) nucleus hypothalami lateralis. This same area in Platypus is in no wise so highly differentiated. There is, therefore, but one homology of which the writer can be certain—namely, that the nucleus lateralis subthalami is similar to the corpus subthalamicum of Luys. As far as position and size of cell are concerned, Winkler and Potter's nucleus hypothalami medialis is more similar to the nucleus lateralis magnocellularis subthalami than is the field of Forel in Primates. In view of the remote resemblance of the opossum, it is a little peculiar that Tsai did not find a nucleus in the subthalamus like the large-celled lateral one of Ornithorhynchus.

In position, the nucleus dorsalis resembles the nucleus entopeduncularis as described by Edinger (1899) for *Varanus griseus*, by Livini (1907) for Hypsiprimnus, by de Lange (1913) for *Varanus salvator* and *Draco volans*, and by Huber and Crosby (1926) for *Alligator mississippiensis*. Huber and Crosby think this nucleus to be undoubtedly in synaptic relation with the ventral portion of the lateral forebrain bundle. Just dorsal to this nucleus is one they call " nucleus Z," which is related to the tecto-reuniens system. Kappers (1921, p. 879) says that the nucleus entopeduncularis is connected with the " basales Riechbündel " (Wallenberg, 1902), and sends fibres to the eye muscle nuclei, and perhaps to the motor fifth.

In the hypothalamus, de Lange (1913, figs. 29–30) describes a nucleus periventricularis which sends fibres into the fasciculus longitudinalis dorsalis in a similar manner to that described by Johnston for fishes. Winkler and Potter's (1914) nucleus infundibularis anterior of the cat resembles the dorsal nucleus of Platypus in position and cellular size. This nucleus, together with the lateral, seems to be the thalamic origin or termination of the fasciculus longitudinalis medialis. Both are connected with the optic tectum, but this dorsal nucleus sends a large bundle into the tegmentum of the midbrain. The nucleus dorsalis is also connected with the other nucleus of the medial group, the ventral. As pointed out in the discussion of the midbrain, it is possible, since the Bielschowsky series suffered from the change of blocks in the caudal region of the dorsal nucleus, that a cellular differentiation exists between the anterior and posterior parts of this nucleus. Certainly the dorsal nucleus resembles Riese's (1924) anterior nucleus of the fasciculus longitudinalis medialis in its fasciculus connection, but not, however, in its relation to the tectum and tegmentum.

The ventral nucleus resembles no discrete nuclei in reptiles or birds. It is related distinctly with the striatum by the strio-subthalamic system, and with the lateral olfactory areas and certain amygdaloid nuclei *via* the ventral olfactory projection tract and *via* the peduncle of the medulla. Possibly the ventral nucleus is a differentiation of the dorsal portion of the hypothalamus, and might be so considered, if it were not for the fact that it lies a little dorsal to the general region and upon the same level with the lateral group.

Looking at the medial group, as opposed to the lateral, the connections of the medial nuclei are similar to those of the lateral with the following exceptions: the lateral nuclei are related to the olfactory projection tract of CAJAL, while the medial (*i.e.*, the ventral) connect with the ventral projection tract; the lateral nuclei (*i.e.*, the lateral proper) in part receive the accessory optic tract and the posterior commissure; and the medial nuclei (both dorsal and ventral) give origin to large descending tegmental and peduncular pathways. The lateral nuclei foreshadow the mammalian development of the subthalamic centres, and the medial recall the great importance which the generalised pathways from this region play in the motor adjustment of lower vertebrates. It is probable that the medial group in Platypus manifests a differentiation unusual for other mammalian forms. It is by way of these systems that the dorsal thalamus discharges into lower motor centres the impulses which it has resolved without aid of the telencephalon.

The Hypothalamus.

The hypothalamus of Platypus was considered as divisible into three centres—the corpus mamillare, the tuber cinereum, and the ventricular grey. Unlike TSAI's account for the opossum, but similar to that of WINKLER for the rabbit and man, the corpus mamillare has a medial large-celled nucleus and a lateral small-celled area. KAPPERS thinks the medial is newer phylogenetically. The medial is not only the origin of the tractus mamillo-thalamicus (the newest of mammillary connections, characteristic for mammals) and of the tractus mamillo-peduncularis dorsalis. This tract is well developed in all macrosmatic mammals. It appears in gross sagittal section, in manner similar to RAMON Y CAJAL's description, as a limb of the tractus mamillo-thalamicus. This bundle bifurcates in the commissura mamillaris, and gives off collaterals to the nucleus dorsalis tegmenti. The lateral nucleus receives the tractus olfacto-mamillaris from the tuberculum olfactorium, from the medial olfactory centres, as well as fibres from the area subcommissuralis and the tuber cinereum, connections having a common denominator in all vertebrates. Its efferent fibre system, the tractus mamillo-peduncularis ventralis, is first found in reptiles, such as lizards, snakes and alligators; this efferent system leaves a nucleus in this region which is similar to that of Platypus, and in the reptiles studied by DE LANGE, the nucleus receives the fornix tractus cortico-mamillaris. However, no fornix was found by HUBER and CROSBY in the alligator.

In the rest of the hypothalamus no discrete nuclei were distinguished, except a single structure which might have been called the nucleus magnocellularis. It lies caudal in the hypothalamus and surrounds the ventricle. It is probably similar to the one by the same name figured by TSAI for the opossum (1925, *a*, fig. 24). There is nothing within the rest of the region which corresponds to nuclei described by HUBER and CROSBY as the nuclei periventricularis hypothalami, or as the nuclei hypothalamici lateralis et ventralis, or to those of DE LANGE (the periventricularis, the nuclei ventralis et lateralis hypothalami). Both HUBER and CROSBY'S and DE LANGE'S lateral hypothalamic nucleus is similar to that part of the tuber cinereum which receives fibres from the striatum. The tuber cinereum and the ventricular grey matter share in common connections from the secondary olfactory centres *via* the medial forebrain bundle, and in those from the amygdaloid complex and pyriform cortex. Both are connected with the subthalamic nuclei. But the tuber cinereum not only sends fibres to the medial nucleus of the mammillary body, but also contributes fibres to the tractus mamillo-peduncularis, and is related to the nucleus preopticus. Indeed, all connections outlined for the hypothalamus in the alligator (HUBER and CROSBY, 1926) are duplicated in Platypus. Further, there is visible in the material studied, no connection which allows confirmation or criticism of ALLEN'S finding in the guinea-pig that fibres from the nucleus of the fasciculus solitarius in the region of the root of seventh nerve ascend with the lemniscus medialis and end in the corpus mamillare. Differentiation in this region has not proceeded as far in the lowest living mammal as it has in certain living reptiles.

The habenula of Platypus is strikingly similar to the descriptions for reptiles (DE LANGE, HUBER and CROSBY) and marsupials (RÖTHIG and TSAI). The lateral part receives impulses from the area subcommissuralis, from the pyriform lobe, from the nucleus tractus olfactorius lateralis, and from the nucleus basalis amygdalæ; the medial, from the hippocampus, and from the area anterior to the optic chiasma and ventral to the anterior commissure. The lateral is joined to the palæocortex and its associated centres; the medial, to the archicortex and to the perichiasmal region. The lateral is connected by a commissure, and sends out a large bundle from its ventral caudal part, forming the fasciculus retroflexus. The medial is placed in anatomic union with the dorsal part of the medial nucleus, as described by HUBER and CROSBY (1926) for the turtle (p. 146), by a connection between the habenula and the dorsal thalamus. In this same reptile these authors find "fine fibres from the habenula accompanying the ventro-lateral tecto-thalamic tract which apparently reach the tectum." These were not found in the alligator material. They are homologous probably with the tractus tecto-habenularis as described by HERRICK (1917) for Necturus. In other words, the habenula of Platypus resembles that of reptiles in all its glorious details. Again, it may be well to suggest that there is as elsewhere in the motor pathways of the olfactory systems quite an apparent hypertrophy of the efferent system—the fasciculus retroflexus or the tractus habenulo-peduncularis.

Study of the dorsal commissures of the midbrain and thalamus in Platypus adds nothing to our general understanding of their function. It is clear that a part of the posterior commissure does join the two nuclei pretectales. Of the ventral commissures, the pars dorsalis (HUBER and CROSBY) of the decussatio supraoptica ventralis in the alligator, the decussatio transversa supraoptica of DE LANGE in Varanus, has no correspondent in Platypus. TSAI (1925, *a*) in the opossum observed that only the medial geniculate bodies were connected, while KAPPERS (1921) ascertained that the ventral commissure joins the posterior midbrain region, constituting the commissura supra-optica ventralis. Were this commissure in Platypus to extend to the inferior colliculus it would then be homologous with the pars ventralis of HUBER and CROSBY's description.

KAPPERS' (1921, fig. 484) commissura supra-optica dorsalis, or MEYNERT'S, typically joins the two nuclei laterales magnocellulares subthalami, and the nucleus lateralis subthalami as well. The commissura infundibularis anterior (FOREL and GANSER) connects the surrounding region of the hypothalamus, and penetrates the nucleus ventralis subthalami, although TSAI did not find this true in the opossum. The nearest counterpart of this commissure in reptiles is a part of the decussatio retro-infundibularis of DE LANGE ; although it is perhaps more nearly like the posterior decussation of the hypothalamus. Besides these decussations there are those of the columns of the fornix and of the corpus mamillare. In other words, in Platypus the two anterior parts of the tectum, the two nuclei pretectales, the two lateral subthalami and the two hypothalami are joined by prominent fibre systems. In those commissures there is nothing which exactly corresponds to KOELLIKER'S (1896) two commissures of the hypothalamus, because these were found by him definitely in the hypothalamus, connecting the two subthalamic regions to the "Kommissur des Nuclei hypothalami" (fig. 649) which are for FOREL'S field H_2 and the field of LUYS, and to the decussatio hypothalami posterior (fig. 650) which appears to connect the two H_2 fields.

There is in Platypus a commissure system (the commissura thalami) which passes through what would be called the massa intermedia or commissura mollis in man, just ventral to the nucleus reuniens, peculiar, in the writer's knowledge, to this brain. Apparently this system ends for the most part in the nucleus lateralis amygdalæ and in a part of the lentiform ; it may also penetrate slightly the nucleus basalis amygdalæ, and perhaps the globus pallidus. The commissure cannot be traced to any part of the thalamus : it is apparently a striatal commissure and will be mentioned again.

In summary, we have a mammal which is peculiar in the hypertrophy of the medial and ventral nuclei of the dorsal thalamus, and in its thalamo-tegmental and peduncular systems. It is quite ordinary in the striatal-thalamic fibre groups, those entering the dorsal thalamus, the subthalamus, or the ventral thalamus. The tectum and its connections are more similar to the descriptions found in the literature of amphibian and reptilian brains than to those of mammals. Finally, the nucleus pretectalis is closely allied to similar structures in reptiles and birds and may perhaps be the precursor of the pulvinar.

The Corpus Striatum.

Any attempt to homologise the corpus striatum of Ornithorhynchus with that of either reptiles or marsupials is made exceedingly difficult, because that body in Platypus, particularly in the adult, resembles nothing on earth so much as itself. The genesis of its peculiarity of form is probably coincident with the marked hypertrophy of the ventral and medial nuclei of the thalamus. Some comparative neurologists would say that the thalamus has pushed the corpus striatum quite out of place, a slightly naïve way of expressing the simple morphological fact that the corpus striatum fits the lateral periphery of the dorsal thalamic complex very like a skull cap fits a bald head. Such an explanation of position carries with it the initial supposition that the growing corpus striatum is a completely plastic body, susceptible only to pressure without, generating none within by its own power of cell differentiation and hypertrophy. Were it true for the striatum, it should be true also for the cortex. It is difficult to imagine such a state of affairs in living tissue—namely, that influence acts in one direction only.

The striate body as a whole in Platypus is mammalian in character. In most particulars it substantiates JOHNSTON'S outline of the evolution of its component parts. Using the position of the internal capsule as a criterion for the ventro-lateral separation of the nucleus caudatus from the putamen of the nucleus lentiformis, then the putamen is, by all odds, the larger of the two. There is but one part of the lentiform which the writer has identified as the globus pallidus. As in all other mammals, in the region ventral to the anterior commissure and dorsal to the tuberculum olfactorium the head of the caudate meets the putamen. Here, however, the transition is aided by an enormous nucleus accumbens, the larger portion of which lies in intimate relation to the lentiform. In development, it is interesting to note that the striatal outer cells are more similar to those found in the developing lentiform, while its inner ones have the same heavy chromatic content as the cells of the nucleus caudatus. The nucleus accumbens is not large in reptiles (KAPPERS, 1921, p. 1015), but it is in marsupials and in Platypus. Its lack of definite fibre relations, except its small contribution to the medial forebrain bundle, leaves us without an explanation of its function. No comments are necessary upon the putamen nor the globus pallidus, except that the latter is indivisible and similar in form to that found in the opossum.

The nucleus caudatus conforms to JOHNSTON'S division into medial bed for the stria terminalis and into the lateral caudatus ridge—a division which is foretold as in other mammalian forms (HINES, 1922) by the development of medial and lateral striatal ridges (figs. 88 and 89). The stria terminalis lying within the medial ridge is interrupted by two nuclei, a phenomenon peculiar to Platypus. The tail of the caudate, which appears to be a part of the lateral ridge, runs into the nucleus lateralis amygdalæ ventro-posteriorly, in a manner similar to JOHNSTON'S (1923) description for the opossum. Further, the writer has found no description of nuclei within the lateral body of the caudate at its extreme dorso-posterior angle, which was suggestive even of similarity, nor did the writer find any mention of the heavy bundle of fibres connecting it to the nucleus lateralis amygdalæ.

The lateral forebrain bundle, or the non-olfactory striatal connection, is typically mammalian. The lateral group of fibres, which connect the lateral and ventral nuclei of the thalamus with the cortex, leaves those nuclei dorso-laterally and ventro-laterally, appearing to spread throughout the whole lateral wall of the hemisphere. No fibres were identified as connected with that part of the medial nucleus which is connected directly with the striatum. The material studied was not such that it could be ascertained whether or not these fibres synapse in the striatum and pass on—that is, whether the termination of these fibres is a remnant of a reptilian character (CROSBY, 1917), or a similarity to that reported for higher mammals (SACHS, 1909, and KINNIER WILSON, 1914). The outer fibre relationships are similar to those described in general for mammals. The chief difference is in the routes which they seek. The anterior part of the medial nucleus, the anterior nucleus and the nucleus reuniens of the thalamus are connected for the most part, not with nucleus caudatus close by, but with the anterior part of the putamen ; these fibres constitute the dorsal striatal-thalamic system, since they pass dorsal to the anterior commissure. If the caudate is caught in this system at all, it must be by strands of small fibres which run along its ventral outskirts. It is the dominance of thalamic-putamen connections which is strange, when SACHS' and WILSON'S work on cats and monkeys is remembered. On the other hand, a few fibres which are found in the putamen immediately ventral to the other group, take passage caudalward beneath the anterior commissure, some stopping in the globus pallidus, others passing to the medial nucleus. Among these fibres, some originate ventral to the others along the lateral border of the nucleus accumbens or from the ventro-lateral area of the lentiform, dorsal to the cortex of the tuberculum olfactorium.

The ventral system of Platypus was divided into a subthalamic, a hypothalamic, and a mesencephalic limb. The division into subthalamic and hypothalamic portions, unknown to reptilian brains, is correlated probably with the differentiation of the submammalian hypothalamus into a definite subthalamus,—a structure which in higher mammals is known as FOREL'S field H_2 and the field of LUYS, into which the globus pallidus discharges. There is no particular nucleus of reception for the hypothalamic bundle. The mesencephalic tract ends in the nucleus ruber and in the substantia nigra—a totally mammalian characteristic. A general tegmental tract (as described by HUBER and CROSBY (1926) and a striatal-tectal connection (the isthmic-striatal tract of EDINGER) were not seen. Also there was no evidence of a fibre relationship between the globus pallidus and the nucleus lateralis as described by WILSON (1914) for the monkey.

The amygdaloid complex.—The discussion of the origin and homologies of the lateral wall of the telencephalon has been characterised by the utter discordance of view and interpretation entertained by different observers. To some, the fact that the dorso-lateral wall of the reptilian telencephalon manifests a prodigious development, compared to the same region in amphibians, is sufficient reason for naming the area hypopallial and concluding that it develops from cortical areas. To other minds, such a fact calls for a more conservative interpretation—that since this tissue is not the result of a primary neuronic emigration outward to form a real cortex and a secondary one inward, it could not be properly said to be a derivative of the cortex and therefore pallial in origin. Further, the pyriform lobe is described as separated from the general pallium by the fissura rhinalis and from secondary olfactory centres, medially or ventromedially, by a fissura endorhinalis which becomes the fissura amygdala when it separates the pyriform from the nucleus amygdalæ. After such a definite delimitation it is difficult to understand how the origin of that complex may be adequately described as the result of an infolding along the fissura itself. If such an origin were authentic, it would mean that cells migrated from the matrix to the area of the fissure and then, multiplying further, were folded in from the region of the fissure to form the various nuclei of the complex: such a question can never be settled until the process of development takes place before our eyes. Further, the fact that a new development of nuclear masses in any part of the brain appears with a fibre system not found in the phyla below, does not mean that the coincidence is the cause of the development of the new nucleus. Rather, it demonstrates only a certain parallelism, in that a new fibre system must of course have a nucleus of origin and one of termination, and in that a hypertrophy of one generally indicates only that the other is large also.

This general criticism does not mean that after a complete survey of the nervous structure of various members of the vertebrate phyla, greater understanding is not possessed by the student, but it does imply that we know nothing about the cause or influences which brought about the so-called change. Such a study does not offer any solution of the problem why certain brains continue to develop past stages at which others become permanently adult; or why some remain embryonic longer; or what causes the varying degrees of energy manifested by their ability or non-ability to maintain cell division over a greater span of time; or what is the source of energy behind their various characteristic forms of development. It is impossible to look at a developing telencephalon of a frog, a reptile like Sphenodon, a lower mammal (such as Platypus), and a higher one (such as man), and not be struck by what appears to be an increasing liability of tissue, or by the evident fact that more cells proliferate. But the impression so gained, as well as a knowledge of all the fibre tracts involved, does not lead one to the cause of the differences in the dynamics of development. Causation, or the factorial elements of phylogenetic or ontogenetic differentiation, is hardly within the scope of inquiry by morphological studies. These considerations should be kept in mind during the whole of the discussion, and especially during the reading of that most intricate region of the corpus striatum, the amygdala.

This region was described for the first time in phylogenetic literature as an area of definite delimitation, under the designation of the occipito-basal lobe by C. L. HERRICK (1891 and 1893); it is identical with the nucleus sphæricus of ADOLF MEYER (1892), with the epistriatum of KAPPERS (1908) and DE LANGE (1911), with the medial nucleus of JOHNSTON (1915) for the turtle, with the ventro-medial nucleus of CROSBY (1917) for the alligator and of HINES (1923) for Sphenodon. In all these reptiles this area is connected with the base of the olfactory bulb, MEYER'S lateral olfactory tract, UNGER'S tractus bulbo-epistriaticus and with certain of the fibres in EDINGER'S tractus parolfactorio-epistriaticus. In Sphenodon the olfactory projection system, the stria medullaris, and connections wth the pyriform, distinguish the nucleus ventro-medialis from the posterior part of the neostriatal ridge, or from that part which is bound to the secondary olfactory centres. In turtles, JOHNSTON (1923) finds fibres from the chief nucleus of the amygdala connecting the parolfactory area and the hypothalamus, the stria terminalis, and the olfactory projection tract of CAJAL. However, in the alligator, HUBER and CROSBY'S (1926) tractus cortico-habenularis lateralis anterior et posterior and the tractus olfacto-habenularis posterior (from the nucleus of the lateral olfactory tract and the nucleus ventro-medialis) are homologous with the stria medullaris component of the stria terminalis in the opossum (JOHNSTON, 1923). From this area of the amygdala arises the ventral olfactory projection tract and from the pyriform, the olfactory projection tract of CAJAL : the typical, dominant connections of the amygdala are well delineated in reptiles with little or no differentiation into distinct nuclei.

However, in Platypus, differentiation into definite nuclei has taken place. The fibre connections which this complex shares in common with reptiles are those made with the medial and central nuclei. The lateral, the basal and the cortical nuclei have no components of any great phylogenetic age. On the surface, this finding agrees with JOHNSTON'S division of the nuclei into primitive and new, except that JOHNSTON believes that the small-celled part of the nucleus basalis is homologous with the nucleus medialis of turtles (if he does not mean the large-celled part of the nucleus medialis, which is the origin of the olfactory projection tract of CAJAL), and is indeed partly responsible for a hypothalamic fibre relationship. From this it would seem, then, that the part of the basal nucleus more closely associated with the pyriform lobe, occupied a position in age between the two extremes of antiquity and youth.

In Platypus, as in the opossum, the medial and central nuclei are closely identified with the stria terminalis. The medial is found somewhat in a line rostro-caudally with the lateral border of the tuberculum olfactorium and of the nucleus of the diagonal band. The central nucleus is not clearly a bed for the fanning out of the stria terminalis, as it is in the mammals JOHNSTON studied. But it does contain many island-like groups of cells which may be followed rostrally, ventral to the anterior commissure. The most anterior limit is that of the rostral extent of the commissure itself, and therefore extends much further anteriorly than the medial. Beneath the commissure these cells may not be a part of the central nucleus ; indeed they are slightly similar only to those of the nucleus tæniæ of RÖTHIG (1909). These cells form a continuous chain of islands from the subcommissural area into the centre of the central nucleus. In the region of the anterior commissure the relation of this nucleus to terminalis fibres appears similar to those fibres and cell masses which RAMON Y CAJAL (1911, vol. 2,

p. 798, fig. 513) has called the "strie ou tænia semi-circulaire avec ses cellules interstitielles."

The small-celled aggregation of the basal nucleus lies in closer relationship with the cortical nucleus than with the pyriform lobe. It is similar in position to that in the opossum, although its connections are not identical. The large-celled part is never prominent in Platypus, and seems to contain more fibres from the stria terminalis than in the opossum. The cortical nucleus is more definitely cortical in structure than that in the marsupial, and there is great difficulty in identifying any fibre relation with stria terminalis. However, there is a fibre tract which lies medial to it, apart from the lateral olfactory tract which may be traced rostrally to the medial lip of the endorhinal sulcus in the anterior perforated space, probably the longitudinal bundle.

The lateral nucleus of Platypus diverges more from the similar structure of the opossum. This nucleus receives a definite contribution (as OBENCHAIN, 1925, describes for Cænolestes) from the stria terminalis and from the peculiar dorso-posterior nucleus of the caudate, and is related to the lateral subthalamic nucleus *via* the indirect olfactory projection tract of CAJAL. Similarly to the conditions in the opossum, the lateral nucleus sends fibres into the external capsule posteriorly and into the anterior commissure or external capsule, anteriorly; the nucleus connected with the putamen, the pyriform lobe and the large-celled basal nucleus.

JOHNSTON (1923) has given in detail the homologies of the nuclei, described by him in marsupials, higher mammals and man, with those of VÖLSCH. It would be superfluous to repeat them. In DE VRIES' (1910) discussion the Hauptkern is the nucleus basalis amygdalæ of this account; the corpus poststriatum, the nucleus lateralis; the nucleus stria terminalis is probably the nucleus centralis; nucleus D is a portion of the medial, and there is no cortical mentioned. It is difficult to recognise the cortical nucleus in Weigert material. DE VRIES' nucleus of the stria terminalis is clearly not the one described for Platypus, nor is it homologous, as he states (p. 394), with the "Kern des sagittalen Längsbündels" of HATSCHEK, nor with RÖTHIG'S (1909) nucleus tæniæ semicircularis. DE VRIES' generalisation that in the mammals studied the variability of the Hauptkern and of the corpus poststriatum is greater than that of the other nuclei lends support to JOHNSTON'S idea that they are the newer differentiations within the amygdala. DE VRIES finds the stria terminalis entering the corpus poststriatum (*i.e.*, the lateral nucleus of JOHNSTON and HINES), and in the cat a fillet from the longitudinal bundle also enters. The absence of the strial connections with the lateral nucleus in the opossum begins to seem to be peculiar.

The writer has failed to find homologies for the two nuclei of the stria terminalis, in Ornithorhynchus, nor was it possible to note the separate components of the stria which JOHNSTON described so ably for the opossum.

No separate commissural bundle was identified. Fibres from all the amygdaloid nuclei and the lateral olfactory centres, enter the commissure directly. The hypothalamic bundle (JOHNSTON'S olfactory projection tract) which joins the medial and central nuclei with the hypothalamus *via* the medial forebrain bundle, is represented rostrally by two groups of fibres which leave the stria, infra- and supra-commissurally, and enter the ventricular grey matter of the hypothalamus. Their exact caudal origin is unknown. The infra-commissural bundle is represented by fibres which pass into the lateral borders of the nucleus accumbens and into the anterior perforated space (area subcommissuralis). The supra-commissural bundle of JOHNSTON appears as a part of those fibres which run over the anterior commissure—in Platypus to the grey of the tuberculum olfactorium, to the septum and the anterior perforated space.

The medial part of the stria terminalis turns into the lateral division of the stria medullaris. Rostrally fibres from the nucleus of the lateral olfactory tract, from the area of the diagonal band, from the nuclear mass ventral to the anterior commissure, and perhaps from the nucleus accumbens, coalesce into a bundle lateral to the optic tract. These are similar to the stria medullaris component of the stria terminalis of JOHNSTON, although in Platypus there is no actual assurance that these particular fibres ever reach the habenula.

The longitudinal bundle has two components in Ornithorhynchus ; first, the pyriform-amygdala connection similar to that of the opossum, constituting the tractus cortico-amygdaloideus for mammals, or the tractus cortico-epistriaticus of reptiles (p. 1084, KAPPERS, 1921). The second comes from the lateral part of the basal medial grey (KAPPERS, 1921)—here the tuberculum olfactorium and perhaps the nucleus of the lateral olfactory tract—to lie in the cell free layer of the cortical nucleus of the amygdala. The first reaches the central, the medial and the basal nuclei. The second appears to run along the outer boundary of the cortical nucleus and to disappear gradually. This connection of the cortical with the secondary olfactory centres suggests the similarity of the cortical nucleus with the neostriatal part of the amygdala in reptiles—the fibre tract which bound it to the rostral part of the telencephalon. If so, these nuclei would arrange themselves from point of view of age, the central and medial as the oldest, the cortical and small-celled basal as well developed in reptiles, and the large-celled basal and lateral as characteristic of mammals.

The lobus pyriformis, the central, the large and small celled basal, and the lateral amygdaloid nuclei all send fibres into the external capsule. The nucleus basalis is joined to the hippocampus.

There are two important systems which bind the amygdala with the nuclei of the subthalamus. The medial and central and possibly a part of the basal amygdaloid nuclei are joined to the nucleus ventralis subthalami, a system which suggests CROSBY's (1917) ventral projection tract, also coming in the alligator from the pyriform lobe and nucleus tractus olfactorius lateralis. Probably fibres from the lateral olfactory areas would be found in Ornithorhynchus if degeneration experiments were used. Those areas are suggestively near. The more lateral part of the central amygydaloid nucleus, the lateral and perhaps the ventromedial area of the lentiform are joined to the lateral subthalamic nucleus. This connection is certainly quite similar to CAJAL's olfactory projection tract from the striatum and temporal lobe, " voie motrice ou voie de projection de l'écorce temporale." However, his description places its termination in the hypothalamus rather than definitely in the subthalamus (CAJAL 1911, vol. 2, p. 721, fig. 462).

Further, no counterpart for the large paired nucleus of Platypus, dorsal to the anterior commissure, in which the stria terminalis is embedded, has been described in mammals.

The Telencephalon.

The basal centres of the telencephalon, dominated by olfactory impulses in Platypus, are simple structures compared with those of other closely related brains which have received any degree of intensive study. Without doubt, this fact may be correlated with the peculiarity of the life of a recluse, whose radius of activity is rather short and who, in spite of water as a medium for food exploration, prefers general cutaneous sensibility to olfactory stimulation. The olfactory bulb, although quite typical of mammals, is also not noticeably enlarged. The region about its dorso-lateral fissure, which the writer has identified as the accessory olfactory bulb, ELLIOT SMITH (1895) thought to contain " the ganglion of JACOBSON'S organ." He found no differentiation either in fibre or cellular content, peculiar to this area. McCOTTER (1912) substantiated this observation by finding in the accessory olfactory bulb of the opossum all those structures characteristic of the distinctly olfactory portion of the bulb. RAMON Y CAJAL'S (1911) description for the rabbit, mouse and guinea-pig (figs. 428 and 429, pp. 671 and 672, vol. 2) shows that a special bundle of fibres terminates within glomeruli, but that no true mitral cells are present. Their places are taken rather by triangular and stellate cells. There is nothing in the accessory portion of the olfactory bulb of Platypus which can be interpreted to support the latter statement of CAJAL.

In an old alcohol-fixed specimen, kindly lent by Prof. WATSON, the writer was able to trace a large compact nerve from JACOBSON'S organ to the olfactory bulb. Part of this nerve was lost on the medial side, which, since BROOKOVER'S (1910) work may be identified as the nervus terminalis. The whole of the nerve is, doubtless, identical with that of ELLIOT SMITH'S (1895) description in WILSON'S Delta and pictured in fig. 1, as JACOBSON'S nerve, connecting that organ with what he called JACOBSON'S ganglion (his fig. 18), lying on the dorso-lateral aspect of the olfactory bulb. The probability that the writer was dissecting two nerves is supported by the work of HUBER and GUILD (1913) on the day-old rabbit. In that animal the branches of the nervus terminalis are associated with those of the nervus vomero-nasalis and may be traced with them to a termination in the vomero-nasal organ itself.

The position of the accessory olfactory bulb in Platypus on the dorso-lateral face of the bulb is slightly aberrant. In McCOTTER'S (1912) account of the opossum and certain of the common laboratory animals it is found on the dorso-medial surface, except in the guinea-pig. ZUCKERKANDL (1910) finds it placed medially in Varanus, *Vipera ammodytes, Tropidonotus natrix,* Gecko and *Alligator lucius* and dorso-laterally in *Hypogeophis alternans* and ventro-laterally in Rana. Generally speaking, the lateral position might be considered as primitive—and in Platypus it is possible that its position may account for a peculiar group of fibres described under the section dealing with the consideration of the diagonal band of BROCA, as passing from the lateral to the medial side of the base of the olfactory bulb to take part in the tractus olfactorius medialis.

McCOTTER (1912) concluded from his studies that the size of the accessory olfactory bulb varied directly with that of JACOBSON'S organ. Both SYMINGTON (1891) and ELLIOT SMITH (1895) believed that this organ reaches its highest development in the monotremata. BROOM (1895) thought SYMINGTON'S figures for the diameter of this organ in Platypus quite correct (5 or 6 mm.), although in one large male it was 7 mm. In Echidna (compare BROOM'S figs. 9 and 10) its diameter is slightly less, but its length about three times as long. This author cannot agree with SYMINGTON, because even "among higher mammals it attains a greater proportional development in some bats." This organ, commonly thought to be an adaptation to terrestrial life, appears first in Amphibians, and has been lost or is present only in the early stages of development in higher forms which have secondarily taken to the sea, such as crocodiles, some Chelonia, the Cetacea, and Pinnipedia (VAN WIJHE, 1919). In birds where the olfactory system is atrophic this organ is completely lacking. In some of the bats it is lost, while in others it is well developed. Strangely enough, in these forms, and in particular in Echidna, there are no studies on the relation of size of that organ to that of the accessory olfactory bulb.

From TURNER'S (1892) comparison of the cerebral hemispheres of Platypus and Echidna, not only is the surface area of the general pallium of the latter approximately twice that of the former, but the respective areas concerned with olfaction would appear to be proportionally smaller in Ornithorhynchus than in Echidna. And yet the former mammal cannot in any sense of the word be described as microsmatic, although a large portion of its life is spent in water. Nor does Platypus resemble such mammals as Pinnipedia and Cetacea in having a rudimentary or lost vomero-nasal apparatus; for not only does JACOBSON'S organ persist into adult life, as a prominent receptive apparatus, but also a large cord-like vomero-nasal nerve may be traced to the region found folded in the fissure of the olfactory bulb. It seems to the writer, without actual measurement of the volume concerned, that size of the receptive centre for this nerve is proportionately slightly larger in the fœtus (WILSON'S "Delta," "xxviii B," and "Beta") than it is in the adult. Nevertheless, after the accessory olfactory bulb is discovered and its limits placed, the anticipated co-ordination of size between end organ, nerve trunk, and centre emerges. Thus in yet another instance Platypus proves itself dissimilar to other so-called aquatic mammals whose characteristics have appeared in the literature.

The simplicity of structure in the olfactory apparatus previously mentioned is particularly true of the nucleus olfactorius anterior and the tuberculum olfactorium. The differentiation in the former lies between that of the turtle (JOHNSTON, 1915) and that described in great detail for marsupials by HERRICK (1924), OBENCHAIN (1925), and for Orycteropus by SONNTAG and WOOLLARD (1925). As in the opossum, the anterior olfactory nucleus is closely related to the adjacent cortex through the funiculus olfacto-corticalis superior (probably the same as the tractus olfacto-frontalis, here a part of the tractus olfactorius intermedius), and to the basal centres *via* the medial forebrain bundle. But whether or not the nucleus is connected to the hippocampus and pyriform lobe by a longitudinal association tract, the writer cannot make out. Fibres leave the anterior olfactory nucleus for all the olfactory tracts and for the tuberculum olfactorium—in manner similar to that seen in *Orycteropus afer*. The tubercle in Platypus, as in the latter Edentate, has no indication of a centre for the reception of any other sense than olfactory. Certainly there is no relation of the trigeminal lemniscus with the medial forebrain bundle—a relation to be anticipated if HERRICK'S revival of EDINGER'S " oral sense " within this area is to have an added substantiation. It is probably rather an area for the re-distribution of impulses reaching it from secondary olfactory centres, from olfactory cortical areas (as the hippocampus and perhaps the pyriform lobe), and from the neighbouring caudate, and for the dispatch of these impulses into the area subcommissuralis, the tuber cinereum, the corpus mamillare, and the amygdaloid complex.

With two additions, the boundaries given by JOHNSTON (1923) for the anterior perforated space correspond to those of the structure which the writer has chosen to call the area subcommissuralis (see footnote on p. 190 of this paper), namely, posteriorly, by the optic chiasma, and dorsally, by the anterior or ventral commissure. At the more caudal extremity, the sulcus endorhinalis gives place to the sulcus hemisphæricus. In this particular instance the anterior perforated space is not in any way similar to the tuberculum, for it contains no cortex, as it does in the opossum. The perforated space is a quite complex region. It includes within its boundaries the nucleus of the diagonal band, the cellular areas, and the nucleus of the area subcommissuralis, which may be a part of the nucleus centralis amygdalæ. It is possible that these structures are specialised parts of the former nucleus. The position of these cell-masses is proper enough, but their cellular continuity with the islands of the central amygdaloid nucleus and their fibre relation with the sagittal longitudinal bundle seem to place them as a part of the amygdaloid complex. These nuclei may be homologous to the " Kern des Sagittales Längsbündels " (see KAPPERS (1921), fig. 563) or the nucleus tæniæ of RÖTHIG (1909). Fibres from these same nuclei enter the anterior commissure. These cell masses are closely connected with the relatively poorly differentiated area labelled the diagonal band nucleus. The nuclei receive fibres medially from the undifferentiated grey matter of the subcommissural region ; and, posterior to the anterior commissure, they contribute to the ventral olfactory projection tract. The undifferentiated grey matter which lies medially, is interspersed with members of the medial forebrain bundle, as well as with fibres which belong to the stria terminalis and stria medullaris system, as JOHNSTON (1913 and 1923) has described for the opossum. Besides, in this undifferentiated grey matter, there are fibres from the septum and the nucleus accumbens.

A part of this undifferentiated grey is grouped into the nucleus preopticus. It is quite similar in its relationships to the same body described by CROSBY (1917) for the alligator by CAIRNEY (1926) for Sphenodon, and by GURDJIAN (1925) for the rat. The lateral part of this region is therefore related to the pyriform lobe and the amygdaloid complex, while the medial is in connection with the hippocampus, medial olfactory centres and hypothalamus. It is possibly here, rather than in the tuberculum, that modified olfactory impulses may be correlated with those from secondary olfactory centres and redistributed into the generalised and differentiated areas of the hypothalamus.

Septal nuclei. (On the usage of the term "Septum," see footnote on p. 156 of this paper.) The medial septal nucleus is little discussed because its boundaries are clear and concise; its fibre relations have the air of certainty. In Ornithorhynchus the nucleus differs from that of reptiles, marsupials and the Eutheria only in being placed a little more dorsal in the septum. The nucleus receives fibres from the medial olfactory tract, contributes its portion to the medial forebrain bundle, and is connected with the rostral part of the fascia dentata, the stratum zonale and the medial side of the pyramidal layer of the hippocampus. It is perhaps a nucleus on the afferent side, passing impulses on to the medial olfactory cortex. But at the mention of the lateral septal nucleus, as many interpretations appear as there are contributors in the field. In the present writer's analysis, there is a difference between the medial wall dorsal to the anterior commissure and that in the same position rostral to the commissure, at least in fibre connections. Fibres from the alveus enter it and fibres leave it for the medial forebrain bundle. The "primordium hippocampi" of JOHNSTON* (1913) is the paraterminal body of ELLIOT SMITH (see SONNTAG and WOOLLARD, 1925) plus the bed for the fimbria. Caudal to the hippocampal commissure, however, no fibre-free area is found ventral to the hippocampal formation in the Weigert series, but in the Bielschowsky brain this area is filled with small cells. This is the area fulfilling the definition of JOHNSTON for his "primordium hippocampi"—not, of course, that any hippocampus will appear within it. As in *Orycteropus afer*, some of the lateral fibres of the stria terminalis appear to end in the septum, particularly within the region of the lateral nucleus. In all probability the lateral nucleus correlates incoming olfactory stimuli from nasal centres with those received from the cortical areas and discharges them into the hypothalamus and perhaps into the tegmentum of the midbrain.

Considering the phylogenetic position of Ornithorhynchus, it is somewhat surprising to find the olfactory cortical centres of secondary importance in the cortex as a whole. The major part of the cortex is doing something other than adjusting to incoming olfactory stimuli. And yet the descending motor systems from the cortex are not

---

* It is unfortunate that JOHNSTON should have utilised in a widely different sense a term introduced by ELLIOT SMITH in 1903 to designate a specified primordial structural formation. The writer has here only employed the term in JOHNSTON's sense in default of any other recognised descriptive term for the region referred to. An alternative to JOHNSTON's confusing misuse of a previously current designation would seem to be highly desirable.

noticeably large. The pyramidal tract (Koelliker, 1901) does not penetrate further than the cervical region of the cord, and occupies only a small area upon the ventral surface of the medulla. We would anticipate that the general pallium should be dominantly somæsthetic, and that the hypertrophy of the cortical area of reception for general cutaneous sensory components for the head would follow suit. Certainly, if fibres from the medial geniculate body circumscribe the cortical auditory projection area, it is rather small and lies at the posterior and lateral pole of the hemisphere. And if the site of origin of the cortico-thalamo-bulbo-spinal system outlines in part the motor cortex, then the great area of the lateral hemisphere is left for such a projection area as the somœsthetic cortex and for whatever association areas possibly exist. Their extent is not likely to prove great.

A glance at the relatively minute pyriform lobe does not suggest that the non-olfactory sense, which it is thought to correlate with the olfactory, is general cutaneous sensibility. The small nucleus tractus olfactorius lateralis and the diminutive lateral olfactory tract suggest that such a correlation is relatively an unimportant ingredient in the make-up of this beast's brain. However, within the lobe itself, its three antero-posterior divisions resemble on a small scale those which Gray (1924) has described for the opossum, with a similar, though slightly different histological structure and arrangement of cells. And similarly to Gray's finding, the most posterior part which the writer has recognised as a part of the pyriform, is not accompanied by any lateral olfactory fibres, visible in the Weigert series studied. Nor was it possible to identify a temporo-ammonic bundle to the hippocampal cortex and the gyrus dentatus. On the other hand, a clear-cut band of fibres leaves the lobe laterally in its medial division, joins the external capsule, swings in an arc laterally, medial to a circular area of temporal cortex and then on into the overlying cellular area. The writer thinks that these cells may be the claustrum, but heterotopically placed, if the fibre tract is companion to the capsula extrema. It is the same as Röthig's (1909) lobo-temporalis tract.

As a formation the cortex hippocampi anterior is found in the ventral lip of the most anterior limit of the hippocampal fissure, in the medial line dorsal to the nucleus medialis septi. Within five sections caudally it lies above and below its fissure. The ventral limit of its ventricular part is bounded by fibres which connect it with the nucleus lateralis septi immediately below Johnston's "primordium hippocampi." Even in its precommissural area this cortex is separated from the tuberculum by the two nuclei and by the head of the caudate or the nucleus accumbens. In this region the lateral septal nucleus is distinct. Immediately rostral to the bulk of the hippocampal commissure lies a well circumscribed nucleus—that of the hippocampal commissure. Dorsal to the hippocampal commissure, the fibres of the dentate portion of the tractus septo-corticalis lie medial to the curved tip of the gyrus dentatus and the tænia of the choroid plexus. These fibres are comparable no doubt to Johnston's (1913, figs. 29—31) stria medialis Lancisii. They no longer appear as a distinct bundle caudal to the hippocampal commissure. As in all other mammalian forms the hippocampal cortex is reduced to two layers—the second or outer pyramids (GRAY, 1924, says to the second and sixth for the opossum) and the sixth or polymorphous of BRODMANN (1909). The fascia dentata contains two layers, a granular and a polymorphous. In the figure, the hippocampal cortex shows the same discontinuity in the outer pyramidal layer at the point of transition to the area subicularis as JOHNSTON figures for the opossum (1913, figs. 29 and 30). Whether or not the fascia dentata cortex is continuous with that of the hippocampus ventral to its most rostral division, as GRAY (1924) pictures for the opossum in fig. 31, the writer cannot say. The arrangement of the fibres makes it unlikely, however.

The tractus olfactorius of Platypus falls more naturally into a dorsal and a ventral group than in the closely related marsupial brains, described by RÖTHIG (1909), OBENCHAIN (1925) and HERRICK (1924). It is the dorsal and the medial part which form the medial tract; the remainder is lateral. The intermediate does not appear in the bulb proper as a distinct system. At the crus, however, a part of the medial fibre bundle lies upon the surface of the brain ventral to the tuberculum. Some of the dorsal fibres curve into the frontal pole; these were described with the tractus intermedius. In a like manner the medial tract is found, as described for *Didelphys* by KAPPERS. But here in Platypus this tract sends fibres into the nucleus medialis septi and into the fascia dentata, with no relation to any nucleus similar to the nucleus tæniæ, as KAPPERS suggests (1921). Probably, as described for other mammals and reptiles, the fibres of the tract synapse in the medial part of the nucleus olfactorius anterior. The lateral olfactory tract varies in no way from marsupials in its division into medial and lateral groups of fibres. It is dwarf-like compared to that of the marsupials figured in the literature. This must be remembered together with the marked differentiation and size of the amygdaloid complex. The destiny of the medial tract in Platypus is more closely related to that set forth in the description of the alligator (CROSBY, 1917) and of the turtle (JOHNSTON, 1915) than to that found in the opossum (HERRICK, 1924). Rather, it is the tractus olfactorius intermedius which, resembling that in reptiles, is more similar to the medial tract of marsupials. This finding does not necessarily suggest a real difference between the monotreme and the next higher order. It may be simply a matter of interpretation. The system, however, in Ornithorhynchus, is intermediate between the medial and lateral tracts. This system spreads itself beneath the tuberculum, and its more lateral fibres enter the region of the nucleus of the lateral olfactory tract, of the nucleus of the diagonal band and perhaps of the subcommissural nuclei. Some fibres of the superficial ventral part of the tract end in the tubercle, as described for reptiles and for the medial tract in the opossum (HERRICK, 1924, p. 333). Others maintaining the same position trail to the area subcommissuralis and a few may reach the tuber cinereum without synapse.

A part of the dorsal fibres of the bulb turn without synapse into the neopallium, constituting the funiculus olfactorius corticalis superior. This is not the tractus olfactorius frontalis of OBENCHAIN (1925) because that system comes from the neopallium into the septum, nor is it the tract of the same name (HERRICK 1924) for the opossum, which connects the nucleus olfactorius anterior with the neopallium. If the tract under discussion synapses in the dorsal area of the nucleus olfactorius anterior, and it probably does, it would resemble in part that of HERRICK'S description. OBENCHAIN'S observation is interesting and suggestive. In this connection ROGERS (1922) found degeneration of fibres in the septum of pigeons after decortication, and RAMON Y CAJAL (1917 and 1918) identified a cortical projection system from the "general" pallium of Varanus and Lacerta. However, it is not improbable that some of the fibres in the alveus, which have their origin beyond the definite limits of the hippocampal formation, may enter the cortico-septal tracts and reach the thalamic motor centres. Only degeneration experiments can prove this.

The tuberculo-cortical system is separated from the septo-cortical group as it is in the alligator. In marsupials the descriptions and figures led to the belief that the same group appears, but is mingled with those definitely septal (SONNTAG and WOOLLARD, 1925, p. 1208, and HERRICK, 1924, fig. 9). No fibres from the deep cells of the cortex prepyriformis are observed to form the tractus lobo- et septo-hippocampalis (KAPPERS, 1921, vol. 2, pt. 2, p. 1063, fig. 560) unless some of those which stand out clearly in the sagittal series had their origin more laterally in the pyriform ; this is quite possible.

The tractus septo-corticalis from the medial septal nucleus to the stratum zonale of the fascia dentata and the medial side of the pyramidal layer of the hippocampus is the same as the "voie ascendante" of the "faisceau de Zuckerkandl" (CAJAL, 1911, vol. 2, pp. 781 and 790). This is the ascending part of the precommissural fasciculus of ELLIOT SMITH and is quite rostral to the main body of the general group, which is descending. The more caudal sweep of this system is descending, and forms the tractus cortico-septalis. This tractus leaves the hippocampus *via* the alveus, ending partially in the nucleus lateralis septi and curving medially and ventrally to the anterior commissure. This is the "voie descendante" of the "faisceau de Zuckerkandl" (CAJAL, 1911), the descending fibres of ELLIOT SMITH'S (1896) precommissural fasciculus, the tractus cortico-olfacto-septalis medialis of KAPPERS (1921), the hypothalamic bundle of precommissural fibres of JOHNSTON (1913, fig. 38). Ventral and rostral in this same bundle are fibres which JOHNSTON (1913) says come from the lateral olfactory areas. At the present, the writer has failed to identify them in Ornithorhynchus. However, the later olfactory areas in part (*i.e.*, the nucleus tractus olfactorius lateralis, the diagonal band and the nucleus subcommissuralis) are connected with the area subcommissuralis. The septal system, ventral to the anterior commissure, turns under and swings laterally into these areas. The writer is inclined to interpret this septal system, as CAJAL suggests, as being composed of descending fibres, not ascending. Some of these end in the nuclei of the area subcommissuralis and are called the tractus subcommissuralis. From this area other neurones take the impulses of the tractus into the central grey of the hypothalamus, into the tuber cinereum, into the ventral nucleus of the subthalamus or into the corpus mamillare. These fibre systems make up what RÖTHIG (1909) and

WALLENBERG (1902) call the " basal Riechbundel " which ends in the zona incerta of the ventral thalamus and in the hypothalamus ; into these structures the area olfactoria, the basi-medial grey and the basal nucleus of the striatum, of the descriptions for reptiles and marsupial brains (KAPPERS, 1921, vol. 2, Abs. 2, p. 1066), send fibres.

Immediately lateral to the above system in Platypus are those of the fornix and stria terminalis. The latter has been described under the discussion of the corpus striatum. The fornix is made up of its constant components, the tractus cortico-habenularis lateralis and the tractus cortico-mamillaris. Some of these fibres cross in the psalterium. The septum (*i.e.*, the lateral nucleus) is connected with the habenula by fibres which flow above the anterior commissure, forming the tractus septo-habenularis. Besides, the nucleus preopticus contributes fibres to the habenula, together with the general region of the subcommissural area, which may mean that impulses from the lateral olfactory areas reach the habenula *via* this route. These tracts are similar to CROSBY'S (1917) description for the alligator, where one has the tractus olfacto-habenularis medialis and the tractus cortico-habenularis lateralis anterior. The latter would lie in the stria medullaris lateral to the hippocampal connection. Some of the fibres of the tractus septo-habenularis send off collaterals to the anterior nucleus and to the anterior limit of the medial thalamic nucleus. The latter strand WALLENBERG (1902) has noted. No record appears in reptiles of such a connection to the writer's knowledge. Possibly the nucleus accumbens contributes also a slip of fibres ventral to the commissure.

The medial forebrain bundle in Ornithorhynchus might be said to be formed by two large systems, one which ends in the hypothalamus and is the more medial, and a lateral, which is continued into the midbrain and medulla. The former is comparable with the basal Riechbündel of earlier authors and is contributed to by the tuberculum, the nucleus accumbens, and the area subcommissuralis, and it ends in the tuber cinereum of the corpus mamillare. The latter tract has similar origins, but its bulk is clearly augmented in the area subcommissuralis. It is possible that the lateral olfactory areas contribute to it. Certainly, their connections with the generalised region below the commissure will allow impulses from those centres to find their way along the olfactory tegmental and peduncular systems.

The posterior part of the pyriform lobe may be connected to the hippocampus by a tract similar to that described by GRAY (1924) and OBENCHAIN (1925) as the temporo-ammonic bundle, the cingulum ammonis or the fibræ hippocampi externi (fig. 554, KAPPERS, 1921, vol. ii, pt. ii, or CAJAL, 1911, vol. ii, fig. 491). The pyriform and neo-cortex as well as the nuclear-like cortex, dorso-lateral to the pyriform, are connected by a fibre system which resembles the capsula extrema in higher mammals, but called by RÖTHIG (1909) in Didelphys, the fibræ lobo-temporales.

The pars neo-corticalis of the anterior commissure, in Ornithorhychus as in other pre-Eutherian mammals, is much larger than the pars olfactoria (KAPPERS, 1921, p. 1068). The writer is inclined to place the putamen's contribution with the newer part.

The older division embraces, as in all other mammals, connections from the olfactory bulbs, the nucleus of the lateral olfactory tract, the nucleus of the area subcommissuralis, the pyriform and the whole of the amygdala. The dorsal or hippocampal commissure is particularly concerned with the hippocampus, the fornix, the subiculum, the nucleus of the commissure, and perhaps with the neocortex. The writer is fully aware of the contentions the last statement may produce ; but a careful examination will show any observer that morphologically no dorsal limit can be drawn for the origin of the alveus fibres, and the experimental degeneration of JOHNSTON (1913) in the opossum cannot be ignored.

In recapitulation, the fibre systems of the telencephalon of this beast are typically mammalian. Impulses coming over the medial olfactory tracts may reach the hippocampal cortex and return to lower centres *via* the fornix and the mammillary peduncular tract or *via* the cortico-septal system and the olfactory peduncular fibres ; or these impulses may reach the habenula and the peduncular systems *via* the fasciculus retroflexus, or they may attain the amygdala by way of the stria terminalis. Such impulses may be correlated in the medial and lateral nucleus of the thalamus with other types of sensibility, entering *via* the septo-thalamic tract fibres or including the hippocampus *via* the mammillo-thalamic bundle. Impulses over the lateral olfactory systems reach the pyriform, and may become associated with those reaching the hippocampus, and the neocortex, or with those obscure and little understood fibres which terminate in the amygdala. The discharge into motor systems is similar to that of the medial system, except for those impulses which leave the amygdala *via* the projection systems, the ventral or the dorsal. They are peculiar only in that the discharge into lower motor centres takes place by way of the subthalamic peduncular and tegmental systems, rather than *via* the hypothalamus. The putamen of the corpus striatum is closely associated with the lateral or neo-amygdaloid group of nuclei and the pyriform cortex ; the medial caudate (or the bed of the stria terminalis) with the palæo-amygdaloid group, with the nucleus of the lateral olfactory tract and with the nucleus of the diagonal band. The nucleus accumbens appears to be related to the medial olfactory centres and seems to send fibres into the medial forebrain bundle.

As we should anticipate from the remarkable hypertrophy of the general cutaneous sensibility of the head of Platypus, and the importance of its centres in the brain stem, the cortex is little concerned with areas for the elaboration of smell impulses. A study of the cortical lamination of Ornithorhynchus will be awaited with interest and eagerness.

CLASSIFIED BIBLIOGRAPHY.

The Rhombencephalon.

Medulla oblongata

ALLEN, W. F., 1919. "Application of the Marchi method to the study of the radix mesencephalica trigemini in the guinea-pig." 'Jour. Comp. Neur.,' vol. 30, p. 169.

—— 1923. "Origin and distribution of the tractus solitarius in the guinea-pig." 'Jour. Comp. Neur.,' vol. 35, p. 171.

—— 1927. "Experimental-anatomical studies on the visceral bulbo-spinal pathway in the cat and guinea-pig." 'Jour. Comp. Neur.,' vol. 42, p. 393.

BARTELMEZ, G. W., 1915. "Mauthner's cell and the nucleus motorius tegmenti." 'Jour. Comp. Neur.,' vol. 25, p. 87.

BROUWER, B., 1913. "Ueber Hemiatrophia neocerebellaris." 'Arch. f. Psych., Berl.,' vol. 51, H. 2, p. 539.

—— 1915. "Anatomische Untersuchungen über das Kleinhirn des Menschen." 'Psych. en Neur. Bladen, Amsterdam,' vol. 19, p. 104.

—— 1915. "Die biologische Bedeutung der Dermatomerie: Beitrag zur Kenntnis der Segmentalanatomie und der Sensibilitätsleitung im Rückenmark und in der Medulla Oblongata." 'Folia Neuro-biol.,' vol. 9, p. 225.

CAJAL. See RAMON Y CAJAL.

DAVIS, L. E., 1923. "The deep sensibility of the face." 'Arch. Neur. und Psych.,' vol. 9, p. 283.

ESSICK, C. R., 1912. "The development of the nuclei pontis and the nucleus arcuatus in man." 'Amer. Journ. Anat.,' vol. 13, p. 25.

FUSE, G., 1912. "Ueber die Striæ am Boden des IV. Ventrikels." 'Neur. Centralbl.,' vol. 31, p. 403.

—— 1913. "Beiträge zur Anatomie des Bodens des IV. Ventrikels." 'Arb. d. hirnanat. Inst. in Zürich, Wiesb.,' Hft. 8, p. 213; also Hft. 7, 1913.

GERARD, M. W., 1923. "Afferent impulses of the trigeminal nerve. The intramedullary course of the painful, thermal, and tactile impulses." 'Arch. Neur. and Psych.,' vol. 9, p. 306.

VAN GEHUCHTEN, A., 1900. "Le faisceau de Munzer ou faisceau tecto-protub-erantiel et les voies courtes." 'Le Névraxe,' vol. 1, fasc. 2, p. 171.

— 1901. "Recherches sur les voies sensitives centrales. La voie centrale du trijumeau." 'Le Névraxe,' vol. 3, p. 235.

HELD, H., 1891. "Die centralen Bahnen des Nervus acusticus bei der Katze." 'Arch. f. Anat. u. Physiol. (Anat. Abth.),' p. 271.

— 1893. "Die centrale Gehörleitung." 'Arch. f. Anat. u. Physiol. (Anat. Abth.),' p. 201.

van Hoevell, J. J. L. D., 1911. "Remarks on the reticular cells of the oblongata in different vertebrates." 'Proc. Kon. Akad. v. Wetensch. Amsterdam,' vol. 13, p. 1047.

Hines, M., 1921. "The superior olive in Ornithorhynchus." 'Jour. of Anat.,' vol. 55, p. 290.

Holmes, G., and Stewart, T. G., 1908. "On the connection of the inferior olives with the cerebellum in man." 'Brain,' vol. 31, p. 125.

Ingvar, S., 1918. "Zur Phylo- und Ontogenese des Kleinhirns." 'Folia Neuro-biol.,' vol. 11, p. 204.

Kappers, C. U. A., 1920. 'Die vergleichende Anatomie,' vol. 2, Abschnitt 1, p. 338.

—— 1922. (Personal Communication.)

Koelliker, A. von, 1893. "Handbuch der Gewebelehre des Menschen." Vol. 2, 1 Hft., Leipzig.

—— 1901. 'Die Medulla Oblongata und die Vierhügelgegend von Ornithorhynchus und Echidna.' Engelmann, Leipzig, 100 pp.

Kooy, F. H., 1916. "The inferior olive in vertebrates." 'Folia Neuro-biol.,' vol. 10, p. 205.

Langworthy, O. R., 1924. "A study of the innervation of the tongue musculature with particular reference to the proprioceptive mechanism." 'Jour. Comp. Neur.,' vol. 36, p. 273.

Monakow, C. von, 1905. 'Gehirnpathologie.' 2. Auflage, Wien.

Nageotte, J., 1906. "The pars intermedia or nervus intermedius of Wrisberg, and the bulbopontine gustatory nucleus in man." 'Rev. Neur. and Psych.,' vol. 4, p. 473.

Oort, H., 1918. "Über die Verästelung des Nervus octavus bei Säugetieren." 'Anat. Anz.,' vol. 51, p. 272.

Poulton, E. B., 1883. "The tongue of Ornithorhynchus paradoxus. The origin of taste buds and the parts upon which they occur." 'Quart. Jour. Micr. Science,' vol. 23, p. 453.

Ramon y Cajal, S., 1909. "Histologie du système nerveux de l'homme et des vertébrés." Vol. 1, p. 754. Paris.

Schepman, 1918. "De octavo-laterale zintuigen en hun verbindungen in de hersenen der Vertebraten." Dissertatie, Amsterdam (Kappers. 'Die Vergleichende Anatomie, etc., Labs. Rep.,' ch. 4, p. 448).

Van der Sprenkel, H. B., 1924. "The hypoglossal nerve in an embryo of Erinaceus Europæus." 'Jour. Comp. Neur.,' vol. 36, p. 219.

Staderini, R., 1894. "Sopra un nucleo di cellule nervose intercalato fra i nuclei di origine del vago e dell' ipoglosso." 'Monitore Zool. Italiano,' Anno 5, p. 178.

Stokes, J. H., 1912. "The acoustic complex and its relations in the brain of the opossum (*Didelphys Virginiana*)." 'Amer. Journ. Anat.,' vol. 12, p. 401.

STOPFORD, J. S. B., 1925. "The function of the spinal nucleus of the trigeminal nerve." 'Journ. Anat.,' vol. 59, p. 120.

TUMBELAKA, R., 1916. "Konsekutive Veränderungen eines kleinen Herdes in dem ventro-lateralen Thalamuskern und das demselben zugrunde liegende klinische Bild." 'Psychiatrische en Neurologische Bladen, Amsterdam,' vol. 20, p. 377.

VAN VALKENBURG, C. T., 1911. "Zur vergleichenden Anatomie des mesencephalen Trigeminusanteils." 'Folia Neuro-biol.,' vol. 5, p. 360.

—— 1911. "Nucleus facialis dorsalis, nucleus trigemini posterior, nucleus trochlearis posterior." 'Proc. Kon. Akad. v. Wetensch., Amsterdam,' vol. 13, p. 143.

—— 1911. "Zur Kenntnis der Radix spinalis Nervi Trigemini." 'Monats. f. Psych. u. Neur.,' vol. 29, Hft. 5, p. 407.

—— 1912. "On the splitting of the nucleus trochlearis." 'Proc. Kon. Akad. v. Wetensch., Amsterdam,' vol. 14, p. 1023.

WALLENBERG, A., 1896. "Die secundäre Bahn des sensiblen Trigeminus." 'Anat. Anz.,' vol. 12, p. 95.

—— 1905. "Sekundäre Bahnen aus dem frontalen sensibeln Trigeminuskerne des Kaninchens." 'Anat. Anz.,' vol. 26, p. 145.

WILSON, J. T., 1906. "On the anatomy of the calamus region in the human bulb; with an account of a hitherto undescribed 'nucleus postremus.'" Part I. 'Jour. Anat. Physiol.,' vol. 40, p. 210.

—— 1906. "On the anatomy of the calamus region in the human bulb; with an account of a hitherto undescribed 'nucleus postremus.'" Part II. 'Journ. Anat. Physiol.,' vol. 40, p. 357.

WILSON, J. G., and PIKE, F. H., 1915. "The mechanism of labyrinthine nystagmus and its modification by lesions in the cerebellum and cerebrum." 'Arch. Int. Med.,' vol. 15, p. 31.

WINKLER, C., 1907. "The central course of the Nervus Octavus and its influence on motility." 'Verhandl. Kon. Akad. v. Wetensch., Amsterdam,' Deel 14, No. 1, p. 1.

—— 1910. "Die Folgen der Abtragung des Tuberculum acusticum beim jungeborenen Kaninchen." 'Folia Neuro-biol.,' vol. 3, p. 275.

—— 1918. "Manuel de Neurologie," vol. 1, pt 1, Haarlem.

—— 1921. "Manuel de Neurologie," vol. 1, pt. 2, Haarlem.

YAGITA, K., and HAYAMA, S., 1909. "Über das Speichelsekretionscentrum." 'Neurologisches Zentralblatt,' vol. 28, p. 738.

ZIEHEN, T., 1897. "Der Aufbau des Cervicalmarks und der Oblongata bei Marsupialiern und Monotremen." 'Anat. Anz.,' vol. 13, p. 171.

Cerebellum.

BOLK, L., 1906. "Das Cerebellum der Säugetiere.—Eine vergleichend-anatomische Untersuchung." Fischer, Haarlem and Jena.

BRADLEY, O. C., 1903. "On the development and homology of the mammalian cerebellar fissures." 'Journ. Anat. Physiol.,' vol. 37, p. 112.

FRENKEL, B., 1909. "Die Kleinhirnbahnen der Taube." (Extrait du Bulletin de l'Académie des Sciences de Cracovie. Juni.)

HOLMES, G., and STEWART, T. G., 1908. "On the connection of the inferior olives with the cerebellum in man." 'Brain,' vol. 31, p. 125.

INGVAR, S., 1918. "Zur Phylo- und Ontogenese des Kleinhirns." 'Folia Neuro-biol.,' vol. 11, p. 204.

KAPPERS, C. U. A., 1921. "Die vergleichende Anatomie des Nervensystems der Wirbeltiere und des Menschen." Abschn. 2, Haarlem.

KUITHAN, D. W., 1895. "Die Entwickelung des Kleinhirns bei Säugetieren." 'Münchener Med. Abh.,' 7. Reihe, 6. Heft.

DE LANGE, S. J., 1917. "Das Hinterhirn, das Nachhirn und das Rückenmark der Reptilien." 'Folia Neuro-biol.,' vol. 10, p. 385.

RAMON Y CAJAL, S., 1909. "Histologie du système nerveux de l'homme et des vertébrés." Vol. 1, Paris.

SHIMAZONO, T., 1912. "Das Kleinhirn der Vögel." 'Arch. f. Mikr. Anat.,' vol. 80, p. 397.

SMITH, G. ELLIOT, 1898. "The brain in the Edentata." 'Trans. Linn. Soc., London,' vol. 7, p. 277.

—— 1902. "The primary subdivision of the mammalian cerebellum." 'Journ. Anat. Physiol., London,' vol. 36, p. 381.

—— 1903. "On the morphology of the brain in the mammalia, with special reference to that of the Lemurs, recent and extinct." 'Trans. Linn. Soc. London, Zool.,' vol. 8, pt. 10, p. 319.

—— 1903. "Further observations on the natural mode of subdivision of the mammalian cerebellum." 'Anat. Anz.,' vol. 23, p. 368.

—— 1903. "Notes on the morphology of the cerebellum." 'Jour. Anat. Physiol.,' vol. 37, p. 329.

STROUD, B. B., 1895. "The mammalian cerebellum. Part I. The development of the cerebellum in man and the cat." 'Jour. Comp. Neur.,' vol. 5, p. 71.

VAN HOEVELL, J. J. L. D., 1916. "The phylogenetic development of the cerebellar nuclei." 'Proc. Kon. Akad. v. Wetensch., Amsterdam,' vol. 18, No. 9, p. 1421.

WINKLER, C., 1923. "A case of olivo-pontine cerebellar atrophy and our conceptions of neo- and palæo-cerebellum." 'Schweiz. Arch. f. Neur. u. Psych.,' vol. 13, p. 684.

WOOLLARD, H. H., 1925. "On anatomy of Tarsius." 'Proc. of Zool. Soc. of London.' Oct. 27, p. 1071 (page 36 of article).

ZIEHEN, T., 1897. "Das Centralnervensystem der Monotremen und Marsupialier. I Teil." 'Makroskopische Anatomie, Fischer,' Jena. 156 pp.

—— 1901. "Über die Furchen und Lappen des Kleinhirns bei Echidna." 'Monats. f. Psych. u. Neur., Berlin,' vol. 10, p. 143.

The Mesencephalon and Diencephalon.

BECCARI, N., 1923. "Il centro tegmentale o interstiziale ed altre formazioni poco note nel mesencefalo e nel diencefalo di un rettile." 'Arch. Ital. di Anat. e di Embriol.,' vol. 20, fasc. 4, p. 560.

BOCHENEK, A., 1908. "Ueber die zentrale Endigung des Nervus opticus." 'Anz. d. Akad. Wiss. zu Krakau.'

BROUWER, B., 1917. "Ueber die Sehstrahlung des Menschen." 'Monats. f. Psych. u. Neur.,' vol. 41, p. 203.

—— 1918. "Klinisch-anatomische Untersuchung über den Oculomotoriuskern." 'Zeitschr. gesamt Neur. u. Psych.,' vol. 40, p. 152.

—— 1923. "Experimentell-anatomische Untersuchungen über die Projektion der Retina auf die primären Opticuszentren." 'Schweizer Arch. f. Neur. u. Psych.,' vol. 13, p. 118.

BROUWER, B., and ZEEMAN, W. P. O., 1926. "The projection of the retina in the primary optic neuron in monkeys." 'Brain,' vol. 49, p. 1.

DEJERINE, J., 1901. "Structure et connexions de la couche optique et dans région optique. Paris, vol. 2, fasc. 1, p. 344.

EDINGER, L., 1899. IV. "Studien über das Zwischenhirn der Reptilien." 'Abh. Senckens. Ges.,' vol. 20.

FARRARO, A., 1924. "Étude anatomique du système nerveux central d'un chien dont le pallium a été enlevé." Utrecht.

HARRIS, W., 1904. "Binocular and stereoscopic vision in man and other vertebrates, with its relation to the decussation of the optic nerves, the ocular movements, and the pupil light-reflex." 'Brain,' vol. 27, p. 107.

HATSCHEK, R., and SCHLESINGER, H., 1902. "Der Hirnstamm des Delphins (*Delphinus delphis*)." 'Arb. a. d. Neur. Inst. d. Wiener Univ.,' vol. 9, p. 1.

HATSCHEK, R., 1907. "Zur vergleichenden Anatomie des Nucleus ruber tegmenti." 'Arb. a. d. Neur. Inst. Wiener Univ.,' vol. 15, p. 89.

HERRICK, C. J., 1917. "The internal structure of the midbrain and thalamus of Necturus." 'Jour. Comp. Neur.,' vol. 28, p. 215.

HUBER, G. C., and CROSBY, E. C., 1926. "On thalamic and tectal nuclei and fibre paths in the brain of the American Alligator." 'Jour. Comp. Neur.,' vol. 40, p. 97.

HUNTER, J. I., 1923. "The oculomotor nucleus of Tarsius and Nycticebus," 'Brain,' vol. 46, p. 38.

KAPPERS, C. U. A., 1921. "Die Vergleichende Anatomie des Nervensystems der Wirbeltiere und des Menschen." Abschn. 2, p. 834, Haarlem.

KOELLIKER, A. VON, 1896. "Handbuch der Gewebelehre des Menschen." Vol. 2, p. 413, Leipzig.

Kosaka, K., and Hiraiwa, K., 1915. "Zur Anatomie der Sehnervenbahnen und ihrer Zentren," 'Folia Neuro-biol.,' vol. 9, p. 367.

de Lange, S. J., 1913. "Das Zwischenhirn und das Mittelhirn der Reptilien." 'Folia Neuro-biol.,' vol. 7, p. 67.

Livini, F., 1907. "Il Proencefalo di un Marsupiale." 'Arch. Ital. di Anat. e di Embriol.,' vol. 6, fasc. 3, p. 549.

Magnus, R., 1924. "Körperstellung." 'J. Springer.'

Malone, E., 1910. "Über die Kerne des Menschlichen Diencephalon." 'Phys.-math. Cl., Abhandl. Kgl. Preuss. Akad. d. Wissen.'

Monakow, C. von, 1895. "Experimentelle und pathologish-anatomische Untersuchungen über die Haubenregion, den Sehhügel und die Regio subthalamica, nebst Beiträgen zur Kenntniss früherworbener Gross- und Kleinhirndefecte." 'Arch. f. Psych. u. Nervenkrankheiten,' vol. 27, p. 1.

—— 1909. "Der rote Kern, die Haube und die Regio subthalamica bei einigen Säugetieren und beim Menschen." 'Arb. Hirn-anat. Inst. Zürich,' Hft. 3.

Muskens, L. J. J., 1914. "An anatomico-physiological study of the posterior longitudinal bundle in its relation to forced movements." 'Brain,' vol. 36, p. 352.

—— 1921. "Clinical observations on impulsive movement in the horizontal position due to injuries to the central vestibular connection in the forebrain." 'Psych. en Neur. Bladen,' Amsterdam, p. 248.

—— 1922. "The central connections of the vestibular nuclei with the corpus straitum, and their significance for ocular movements and for locomotion." 'Brain,' vol. 45, p. 454.

Parsons, J. H., 1921. "The evolution of visual perceptions." 'Trans. Ophthalmol Soc.,' vol. 41, p. 97.

Rademaker, G. G. J., 1926. "Die Bedeutung der roten Kerne und des übrigen Mittelhirns für Muskeltonus, Körperstellung und Labyrinthreflexe." Berlin.

Ramon y Cajal, S., 1911. "Histologie du système nerveux de l'homme et des vertébrés." Paris, vol. 2, p. 175.

Riese, W., 1924. "Zur vergleichenden Anatomie der Striofugalen Faserung." 'Zentralbl. f. d. gesamte Neur. u. Psych.,' vol. 34, Hft. 3—1924, Anat. Anz., vol. 57, p. 487.

—— 1924. "Über faseranatomische Verbindungen im 'striären System' der wasserlebenden Säuger." 'Zeitsch. f. d. gesamte Neur. u. Psych.,' vol. 90, p. 591.

—— 1924. "Beiträge zur Faseranatomie der Stammganglien." 'Jour f. Psych. u. Neur.,' vol. 31, p. 81.

Röthig, P., 1909. "Riechbahnen, Septum, und Thalamus bei *Didelphys Marsupialis*." 'Neur. Inst., Frankfurt, a. M.'

—— 1911. "Beiträge zum Studium des Zentralnervensystems der Wirbeltiere." 'Arch. f. mikr. Anat.,' vol. 77, p. 48.

SACHS, E., 1909. "On the structure and functional relations of the optic thalamus." 'Brain,' vol. 32, p. 85.

SHERRINGTON, C. S., 1897-98. "Decerebrate rigidity and reflex co-ordination of movements." 'Jour. Physiol.,' vol. 22, p. 319.

THIELE, F. H., 1905. "On the efferent relationship of the optic thalamus and Deiters' nucleus to the spinal cord." 'Jour. Physiol.,' vol. 32, p. 358.

TREACHER COLLINS, E., 1921. "Changes in the visual organs correlated with the adoption of arboreal life and with the assumption of the erect posture (Bowman Lecture, 1921)." 'Trans. Ophthalmol. Soc.,' vol. 41, p. 10.

TSAI, C., 1925. "The optic tracts and centres of the opossum, *Didelphis virginiana.*" 'Jour. Comp. Neur.,' vol. 39, p. 173.

—— 1925. "The descending tracts of the thalamus and midbrain of the opossum, *Didelphis virginiana.*" 'Jour Comp. Neur.,' vol. 39, p. 217.

WINKLER, C., 1918. "Opera omnia," vol. 6, ch. 2, Haarlem.

WINKLER, C., and VAN LONDEN, D. M., 1909. "About the function of the ventral group of nuclei in the thalamus opticus of man." 'Proc. Kon. Akad. v. Wetensch., Amsterdam,' vol. 11, p. 295.

WOOLLARD, H. H., 1926. "Notes on the Retina and lateral Geniculate Body in Tupaia, Tarsius, Nycticebus and Hapale." 'Brain,' vol. 49, p. 77.

The Telencephalon.

BRODMANN, K., 1909. "Vergleichende Lokalizationslehre der Grosshirnrinde." Leipzig.

BROOKOVER, C., 1910. "The olfactory nerve, the nervus terminalis and the preoptic sympathetic system in *Amia calva* L." 'Jour. Comp. Neur.,' vol. 20, p. 49.

BROOM, R., 1895. "Organ of Jacobson in Monotremata." 'Jour. Anat. and Phys.,' vol. 30, p. 70.

CAIRNEY, J., 1926. "A general survey of the forebrain of *Sphenodon punctatum.*" 'Jour. Comp. Neur.,' vol. 42, No. 2, p. 255.

CROSBY, E. C., 1917. "The forebrain of *Alligator mississippiensis.*" 'Jour. Comp. Neur.,' vol. 27, p. 325.

DART, R. A., 1920. "A contribution to the morphology of the corpus striatum." 'Jour. Anat.,' vol. 55, p. 1.

DEJERINE, J., 1901. "Anatomie des centres nerveux," vol. 2, fasc. 1, Paris.

DE VRIES, E., 1910. "Das Corpus striatum der Säugetiere." 'Anat. Anz.,' vol. 37, p. 385.

EDINGER, L., 1911. 'Vorlesungen über den Bau der Nervösen Zentralorgane des Menschen und der Tiere.' 8th Ed., vol. 1, Leipzig.

GRAY, P. A., 1924. "The cortical lamination pattern of the opossum, *Didelphys virginiana.*" 'Jour. Comp. Neur.,' vol. 37, p. 221.

GURDJIAN, E. S., 1925. "Olfactory connections in the albino rat, with special reference to the stria medullaris and the anterior commissure." 'Jour. Comp. Neur.,' vol. 38, p. 127.

HALLER, B. 1900. "Vom Bau des Wirbelthiergehirns. III. Theil. *Mus*, nebst Bemerkungen über das Hirn von Echidna." 'Morphol. Jahrb,' vol. 28, p. 347.

HERRICK, C. L., 1891. "Contributions to the comparative morphology of the central nervous system. II. Topography and histology of the brain of certain reptiles." 'Jour. Comp. Neur.,' vol. 1, p. 14.

—— 1893. 'Jour. Comp. Neur.,' vol. 3, pp. 77, 119.

HERRICK, C. J., 1910. "The morphology of the forebrain in Amphibia and Reptilia." 'Jour. Comp. Neur.,' vol. 20, p. 413.

—— 1921. "The connections of the vomeronasal nerve, accessory olfactory bulb and amygdala in Amphibia." 'Jour. Comp. Neur.,' vol. 33, p. 213.

—— 1924. "The nucleus olfactorius anterior of the opossum." 'Jour. Comp. Neur.,' vol. 37, p. 317.

—— 1925. "The amphibian forebrain. III. The optic tracts and centres of Amblystoma and the frog." 'Jour. Comp. Neur.,' vol. 39, p. 433.

HINES, M., 1922. "Studies in the growth and differentiation of the telencephalon in man. The fissura hippocampi." 'Jour. Comp. Neur.,' vol. 34, p. 73.

—— 1923. "The development of the telencephalon in *Sphenodon punctatum*." 'Jour. Comp. Neur.,' vol. 35, p. 483.

HUBER, G. C., and GUILD, S. R., 1913. "Observations on the peripheral distribution of the nervus terminalis in Mammalia." 'Anat. Rec.,' vol. 7, p. 253.

JOHNSTON, J. B., 1913. "The morphology of the septum, hippocampus, and pallial commissures in Reptiles and Mammals." 'Jour. Comp. Neur.,' vol. 23, p. 371.

—— 1913. "Nervus terminalis in Reptiles and Mammals." 'Jour. Comp. Neur.,' vol. 23, p. 97.

—— 1915. "The cell masses in the forebrain of the turtle, *Cistuda carolina*." 'Jour. Comp. Neur.,' vol. 25, p. 393.

—— 1916. "The development of the dorsal ventricular ridge in Turtles." 'Jour. Comp. Neur.,' vol. 26, p. 481.

—— 1923. "Further contributions to the study of the evolution of the forebrain." 'Jour. Comp. Neur.,' vol. 35, p. 337.

KAPPERS, C. U. A., 1908. "Weitere Mitteilungen über die Phylogenese des Corpus striatum und des Thalamus." 'Anat. Anz.,' vol. 33, p. 321; p. 834.

—— 1921. "Die Vergleichende Anatomie des Nervensystems der Wirbeltiere und des Menschen." Vol. 2, p. 834, Haarlem.

KOELLIKER, A., 1893. "Handbuch der Gewebelehre des Menschen," vol. 2, Leipzig.

KUHLENBECK, H., and KIESEWALTER, C., 1923. "Zur Phylogenese des Epistriatums." 'Anat. Anz.,' vol. 55, p. 145.

LANDAU, E., 1919. "The comparative anatomy of the nucleus amygdalæ, the claustrum and the insular cortex." 'Journ. Anat.,' vol. 53, p. 351.

DE LANGE, S. J., 1911. "Das Vorderhirn der Reptilien." 'Folia Neuro-biol.,' vol. 5, p. 548.

—— 1913. "L'évolution phylogénétique du corps strié." 'Le Névraxe,' vol. 14, p. 105.

MEYER, A., 1892. Über das Vorderhirn Einiger Reptilien." 'Zeitsch. wiss. Zool.,' vol. 55, p. 63.

MCCOTTER, R. E., 1912. "The connection of the vomeronasal nerves with the accessory olfactory bulb in the opossum and other mammals." 'Anat. Rec.,' vol. 6, p. 299.

OBENCHAIN, J. B., 1925. "The brains of the South American Marsupials, Cænolestes and Orolestes." 'Field Museum of Natural History, Chicago, Zool. Series,' vol. 14, No. 3, p. 175.

RAMON Y CAJAL, S., 1911. "Histologie du système nerveux de l'homme et des vertébrés." vol. 2, Paris.

—— 1917-18. "Nuevo estudio del encefalo de los reptiles." 'Trabajos del Lab. de Investigaciones Biol. de la Univ. de Madrid,' vol. 15, p. 83 ; vol. 16, p. 309.

—— 1922. "El Cerebro de los Batracios." 'Libro en honor de S. RAMON Y CAJAL,' Madrid, p. 13.

ROGERS, F. T., 1922. "Studies of the brain stem. VI. An experimental study of the corpus striatum of the pigeon as related to various instinctive types of behaviour." 'Jour. Comp. Neur.,' vol. 35, p. 21.

SACHS, E., 1909. "On the structure and functional relations of the optic thalamus." 'Brain,' vol. 32, p. 95.

SMITH, G. ELLIOT, 1895. "JACOBSON'S organ and the olfactory bulb in Ornithorhynchus." 'Anat. Anz.,' vol. 11, No. 6, p. 161.

—— 1896. "The brain of a fœtal Ornithorhynchus." 'Quart. Jour. Micr. Sci., London,' vol. 39, p. 187.

—— 1896. "The structure of the cerebral hemisphere of Ornithorhynchus." 'Jour. Anat. and Physiol.,' vol. 30, p. 463.

—— 1896. "The morphology of the true 'limbic lobe,' corpus callosum, septum pellucidum and fornix." 'Journ. Anat. and Physiol.,' vol. 30, p. 157, also p. 185.

—— 1898. "The relation of the fornix to the margin of the cerebral cortex." 'Jour. Anat. and Physiol.,' vol. 32, p. 23.

—— 1898. "The brain in Edentata." 'Trans. Linn. Soc., London, 2nd series, Zool.,' vol. 7, p. 277.

—— 1899. "Further observations on the anatomy of the brain in the Monotremata." 'Jour. Anat. and Physiol.,' vol. 33, p. 309.

—— 1903. "Further observations on the natural mode of subdivision of the mammalian cerebellum." 'Anat. Anz.,' vol. 23, p. 368.

SMITH, G. ELLIOT, 1919. "A preliminary note on the morphology of the corpus striatum and the origin of the neopallium." 'Jour. Anat.,' vol. 53, p. 271.

SONNTAG, C. F., and WOOLLARD, H. H., 1925. "A monograph of *Orycteropus afer*.—II. Nervous system, sense-organs and hairs." 'Proc. Zool. Soc., London,' Part 3, p. 1185.

SYMINGTON, J., 1891. "On the nose, the organ of Jacobson, and the Dumb-bell-shaped bone in Ornithorhynchus." 'Proc. Zool. Soc.'

TURNER, W., 1892. "The cerebral hemispheres of *Ornithorhynchus paradoxus*." 'Journ. Anat. and Phys.,' vol. 26, p. 256.

UNGER, L., 1906. "Untersuchungen über die Morphologie und Faserung des Reptiliengehirns; mit einem Vorworte von E. Zuckerkandl." 'Anat. Hefte. Wiesb.,' Abt. 1, vol. 31, p. 269.

VAN DER SPRENKEL, H. B., 1926. "Stria terminalis and amygdala in the brain of the opossum (*Didelphis virginiana*)." 'Jour. Comp. Neur.,' vol. 42, p. 211.

VÖLSCH, MAX, 1906. "Zur vergleichenden Anatomie des Mandelkerns und seiner Nachbargebilde." 'Arch. f. mikr. Anat.,' vol. 68, p. 573.

—— 1910. "Zur vergleichenden Anatomie des Mandelkerns und seiner Nachbargebilde." 'Arch. f. mikr. Anat.,' vol. 76, p. 373.

WALLENBERG, A., 1902. "Das basale Riechbündel des Kaninchens." 'Anat. Anz.,' vol. 20, p. 175.

VAN WIJHE, J. W., 1919. "On the nervus terminalis from man to Amphioxus." Kon. Akademie Wetensch. te Amsterdam. (From 'Proceedings,' vol. 21, Nos. 1 and 2, p. 172.)

WILSON, S. A. K., 1914. "An experimental research into the anatomy and physiology of the corpus striatum." 'Brain,' vol. 36, p. 427.

WINKLER, C., and POTTER, A., 1911. "An anatomical guide to the experimental researches on the rabbit's brain." Versluys. Amsterdam.

—— 1914. 'An anatomical guide to experimental researches on the cat's brain.' Amsterdam.

ZIEHEN, T., 1897. "Das Centralnervensystem der Monotremen und Marsupialier. I. Teil, Makrosk. Anat.," 'Zoologische Forschungsreisen,' vol. 3, p. 1. G. Fischer; or 'Denkschr. Med. Nat. Ges.,' Jena, vol. 6, p. 1.

—— 1906. 'Hertwig's Handbuch der Entwicklungslehre der Wirbeltiere.' III. Teil, vol. 2.

—— 1908. "Das Centralnervensystem, &c. II. Teil, Mikrosk. Anat." SEMON, 'Zoologische Forschungsreisen,' vol. 3, p. 789. (Denkschr., &c., vol. 6.)

ZUCKERKANDL, E., 1910. "Über die Wechselbeziehung in der Ausbildung des Jacobsonschen Organs und des Riechlappens, nebst Bemerkungen über das Jacobsonsche Organ der Amphibien." 'Anat. Hefte,' vol. 41, p. 1.

General.

BOAS, J. E. V., & PAULLI, S., 1908. 'The elephant's head.—Studies in the comparative anatomy of the organs of the head of the Indian Elephant and other mammals. I. The facial muscles and the proboscis.' Jena.

BURRELL, H., 1927. "The Platypus." Sydney.

CALDWELL, W. H., 1885. "On the development of the Monotremes and Ceratodus." 'Jour. and Proc. Roy. Soc. N.S.W.,' vol. 18, p. 117.

GERVAIS, P., 1869. "Mémoire sur les Formes Cérébrales propres aux Marsupiaux." 'Nouv. Arch. du Mus.,' vol. 5.

HILL, A., 1893. "On the cerebrum of *Ornithorhynchus paradoxus*." 'Phil. Trans.,' B.

MECKEL, J. F., 1826. "Ornithorhynchi paradoxi descriptio anatomica. Lipsiæ."

OWEN, R., 1847. 'Monotremata. Todd's Cyclopædia of Anatomy,' vol. 3, p. 383.

—— 1865. "On the marsupial pouches, mammary glands, and mammary fœtus of the *Echidna hystrix*." 'Phil. Trans.,' p. 671.

POULTON, E. B., 1884. "On the tactile terminal organs and other structures in the bill of Ornithorhynchus." 'Proc. Physiol. Soc.,' pp. xv and xvi ('Jour. Physiol.,' vol. 5, 1885).

———— 1894. "The structure of the bill and the hairs of *Ornithorhynchus paradoxus* with a discussion of the homologies and origin of mammalian hair." 'Quart. Jour. Micr. Sci.,' N.S., vol. 36, p. 143.

RUGE, G., 1895. "Die Hautmuskulatur der Monotremen und ihre Beziehung zu dem Marsupial- und Mammarapparat." 'Aus Semons "Zoologische Forschungsreisen in Australien und dem Malayischen Archipel,' vol. 2, 'Jenaische Denkschriften,' vol. 15, p. 75.

SCHULMANN, H., 1905. "Über die ventrale Facialismuskulatur einiger Säugetiere, besonders der Monotremen." 'Festschrift für PALMEN.' Nr. 18, Helsingfors, p. 1.

SMITH, G. ELLIOT, 1896. "The brain of a fœtal Ornithorhynchus." 'Quart. Jour. Micr. Sci.,' vol. 39, p. 187.

WILSON, J. T., and MARTIN, M. B., 1892. "Macleay Memorial Volume." Sydney, p. 190. Review in 'Abstract of Proceedings of Linn. Soc. of N.S.W.,' August 31, 1892.

WILSON, J. T., 1894. "Description (with figures) of a young specimen of *Ornithorhynchus anatinus* from the collection of the Australian Museum, Sydney." 'Proc. Linn. Soc., N.S.W.,' Series 2, vol. 9, p. 682.

WILSON, J. T., and MARTIN, C. J., 1894. "Further observations upon the anatomy of the integumentary structures in the muzzle of Ornithorhynchus." 'Proc. Linn. Soc., N.S.W.,' Series 2, vol. 9, Oct. 31, p. 660.

ABBREVIATIONS USED ON THE FIGURES.

a.ac., area acustica.
a.c., anterior commissura.
a.col., anterior colliculus.
a.l., ansa lenticularis.
alv., alveus.
a.m.v., anterior medullary velum.
aq.S., aquæductus Sylvii.
a.p.s., anterior perforated space.
a.ret.sp., area retrosplenialis.
a.s., area subcommissuralis.
b.am., boundary of the amygdaloid complex.
b.o.a., bulbus olfactorius accessorius.
b.p., basis pedunculi.
br.c., brachium conjunctivum.
c.a., see *a.c.*
c.d., commissura dorsalis.
c.ell., corpus ellipticum.
cer., cerebellum.
c.ex., capsula extrema.
c.g., central grey.
c.h., commissura habenularis.
c.i., colliculus inferior.
c.i.c., commissura colliculi inferioris.
cing., cingulum.
claus., claustrum.
c.m., corpus mamillare.
c.m.l., corpus mamillare laterale.
c.m.m., corpus mamillare mediale.
com.m., commissura mollis.
c.o., chiasma opticum.
c.p., commissura posterior.
c.p.o., commissura postoptica.
c.r., corpus restiforme.
c.s., colliculus superior.
c.str., corpus striatum.
c.sup., commissura superior.
c.th., commissura thalami.
c.tr., corpus trapezoideum.
cul., culmen.
d.b., diagonal band of Broca.
d.br.c., decussatio brachii conjunctivi.
d.c., dorsal or hippocampal commissure.
d.c.m., decussatio corporis mamillaris.
d.d.M., dorsal decussation of von Monakow.
dec., declive.

dec.l.m., decussatio lemnisci medialis.
dec.l.t., decussatio lemnisci trigemini.
d.g.i., decussatio ganglion interpedunculare.
d.H., intermediate decussation of Held.
d.h.p., decussatio hypothalamica posterior.
d.i.c., decussatio colliculi inferioris.
d.l.m., see *dec.l.m.*
d.l.n., dorsal lateral nucleus of the olive.
d.M., decussation of Meynert.
d.t.gr., di-telencephalic groove.
d.t.S., dorsal tegmental bundle of Schütz.
e.a.f., external arcuate fibres.
e.c., external capsule.
e.th., epithalamus.
f., folium.
fais.precom., faisceau precommissural.
f.am., fissura amygdalæ.
f.b.o., fissura bulbi olfactorii.
f.c., fissura centralis.
f.c.G., fibres of commissure of Gudden.
f.c.M., fibres of commissure of Meynert.
f.cr., fissura cruciatus.
f.cun., fasciculus cuneatus.
f.d., fascia dentata.
f.d.tr.M., fibres direct from tract of von Monakow.
f.e.rh., fissura endorhinalis.
f.gr., fasciculus gracilis.
f.h., fissura hippocampi.
f.i., fissura intercruralis.
f.l., fissura lateralis.
fl., flocculus.
f.l.m., fasciculus longitudinalis medialis.
f.l.s., fasciculus longitudinalis superior.
for., fornix.
f.p., fissura prima.
f.p.f. or *f.p.fl.*, fissura paraflocculi.
f.p.l., fissura postlunata.
f.r., fasciculus retroflexus.
f.rh., fissura rhinalis.
f.s., fissura secunda.
f.s., fasciculus solitarius.
f.sec., see *f.s.*
f.s.p., fissura suprapyramidalis.
fun.o.c.sup., funiculus olfactorius corticalis superior
g.d., or *g.d.t.*, ganglion dorsale tegmenti.
g.i., ganglion interpedunculare.
g.p., globus pallidus.

gr.c., granular cells.
g.t., ganglion tegmenti.
g.v., ganglion vestibulare.
g.vii., genu nervi facialis.
hab., habenula.
hab.l., habenula lateralis.
hab.m., habenula medialis.
hip., hippocampus.
H.o., Haupt-olive.
h.th., hypothalamus.
h.th.vent., hypothalamus ventralis.
h.th.med., hypothalamus medialis.
i.a.f., internal arcuate fibres.
i.c., internal capsule.
i.o., inferior olive.
inf., infundibulum.
infracom.b., infracommissural bundle of stria terminalis.
l.ant., lobus anterior.
lat.h.th., hypothalamus lateralis.
l.b., longitudinal bundle.
l.c., lobulus centralis.
lem.l., lemniscus lateralis.
lem.m., lemniscus medialis.
lem.t., lemniscus trigeminus.
l.f.b., lateral forebrain bundle.
l.g.b.d., corpus geniculatum lateralis dorsalis.
l.g.b.v., corpus geniculatum lateralis ventralis.
lin., lingula.
l.med., lobus medialis.
l.m.c., lamina of mitral cells.
l.post., lobus posterior.
l.s., lobulus simplex.
l.temp., lobus temporalis.
mes.m., cells from medial part of mesencephalic tegmentum.
mes.teg., mesencephalic tegmentum.
m.f.b., medial forebrain bundle.
m.f.d.b., mossy fibres, deep bundle.
m.f.m.b., mossy fibres, main bundle.
m.f.o.b., mossy fibres, overlying bundle.
m.g.b., corpus geniculatum mediale.
m.n.o., medial nucleus of the inferior olive.
n., nodulus.
n.a., nucleus anterior.
n.a.b., nucleus amygdalæ basalis.
n.a.c., nucleus amygdalæ centralis.
n.a.c.a., nucleus adjacens commissuræ anterioris.
n.a.cort., nucleus amygdalæ corticalis.

n.a.K., nucleus accumbens, sometimes known as that of Kappers, at others as of Ziehen.
n.a.l., nucleus amygdalæ lateralis.
n.a.m., nucleus amygdalæ medialis.
n.a.p., nucleus amygdalæ basalis.
n.a.s., nucleus of the area subcommissuralis.
n.b.str.t., nucleus of the bed of the stria terminalis.
n.c., nucleus caudatus.
n.c.l., nucleus cerebellaris lateralis.
n.c.m., nucleus cerebellaris medialis.
n.c.p., nucleus commissuræ posterioris.
n.c.tr., nucleus corporis trapezoidei.
n.D., nucleus of Darkschewitch.
n.d.b.B., nucleus diagonal band of Broca.
n.d.s., nucleus dorsalis subthalami.
n.d.t., nucleus dorsalis tegmentalis.
neop., neopallium.
neostr., neostriatum.
n.f.l.m., nucleus fasciculus longitudinalis medialis.
n.i., nucleus interstitialis.
n.l.m.s., nucleus lateralis magnocellularis subthalami.
n.l.s., nucleus lateralis subthalami.
n.m.s., see *n.s.m.*
n.m.t., nucleus mesencephalicus trigemini.
n.m.v., nucleus motorius trigeminus.
n.m.v., in fig. 46, *b*, nervus motorius trigemini.
n.o.a., nucleus olfactorius anterior.
n.op., nervus opticus.
nos., nostril.
n.p., nuclei pontis.
n.p.o., nucleus preopticus.
n.p.s., nucleus posterior subthalami.
n.r., nucleus ruber.
n.r.r., nucleus reticularis raphes (inferior).
n.s.l., nucleus septi lateralis.
n.s.m., nucleus septi medialis.
n.s.op., nucleus supra-opticus.
n.t.o.l., nucleus tractus olfactorii lateralis.
n.t.r., nucleus triangularis reticularis.
n.tr.op.ac.p., nucleus tracti optici accessorii posterioris.
nuc.a., nucleus ambiguus.
nuc.a.c., nucleus near the anterior commissure.
nuc.a.k., nucleus accumbens, see *n.a.k.*
nuc.c., nucleus centralis.
nuc.c.d., nucleus cochlearis dorsalis.
nuc.c.str., nuclei corporis striati.
nuc.cun., nucleus cuneatus.
nuc.c.v., nucleus cochlearis ventralis.

nuc.d.l., in fig. 63, *a*, see *nuc.d.l.th.*
nuc.d.l., nucleus dorso-lateralis oculomotorii.
nuc.d.l.th., nucleus dorso-lateralis thalami.
nuc.d.m., nucleus dorso-medialis oculomotorii.
nuc.d.vii., nucleus dorsalis facialis.
nuc.d.x., nucleus dorsalis vagi.
nuc.d.x.s.c., nucleus dorsalis vagi, small celled part.
nuc.f.s., nucleus fasciculi solitarii.
nuc.f.s.lat., nucleus fasciculi solitarii, lateral division.
nuc.f.s.med., nucleus fasciculi solitarii, medial division.
nuc.gr., nucleus gracilis.
nuc.i., or *nuc.int.*, nucleus intercalatus.
nuc.iii., nucleus oculomotorius.
nuc.iv., nucleus trochlearis.
nuc.ix., nucleus glossopharyngeus.
nuc.l., nucleus lentiformis.
nuc.lat.th., nucleus lateralis thalami.
nuc.l.l., nuclei lateralis lemnisci.
nuc.m., nucleus medialis.
nuc.m.l., in fig. 63, *a*, see *nuc.m.l.th.*
nuc.m.l.th., nucleus medio-lateralis thalami.
nuc.m.t.c., nucleus mesencephalicus trigemini centralis.
nuc.m.t.l., nucleus mesencephalicus trigemini lateralis.
nuc.m.t.m., nucleus mesencephalicus trigemini medialis.
nuc.m.V., nucleus mesencephalicus trigemini.
nuc.o.m., nucleus olfactorius medialis.
nuc.p., nucleus pretectalis.
nuc.p.op., nucleus preopticus.
nuc.r., nucleus ruber.
nuc.reu., nucleus reuniens.
nuc.r.l., nucleus reticularis lateralis.
nuc.r.r., nucleus reticularis raphes.
nuc.r.t., nucleus reticularis triangularis.
nuc.s.op., nucleus supraopticus.
nuc.s.V., nucleus sensibilis trigemini.
nuc.s.V.l., nucleus sensibilis trigemini lateralis.
nuc.s.V.m., nucleus sensibilis trigemini medialis.
nuc.str.t., nucleus striæ terminalis.
nuc.s.x., nucleus sensibilis vagi.
nuc.tr.o.l., nucleus tractus olfactorius lateralis.
nuc.v.d., nucleus vestibularis dorsalis.
nuc.V., nucleus trigemini.
nuc.vi., nucleus abducens.
nuc.v.l., nucleus ventro-lateralis oculomotorii.
nuc.v.l., nucleus vestibularis lateralis.
nuc.v.l., in figs. 45 and 63, *a* is nucleus ventro-lateralis thalami.
nuc.v.l.th., nucleus ventro-lateralis thalami.

nuc.v.m., nucleus vestibularis medialis.
nuc.v.s., see *nuc.v.d.*
nuc.v.sp., nucleus vestibularis spinalis.
nuc.v.vii., nucleus ventralis facialis.
nuc.xii., nucleus hypoglossus.
n.v.n., nervus vomero-nasalis.
n.v.s., nucleus ventralis subthalami.
n.vi., nervus abducens.
n.vii., nervus facialis.
n.x., nervus vagus.
n.xi., nervus spino-accessorius.
n.xii., nervus hypoglossus.
o.b., bulbus olfactorius.
occ.l., lobus occipitalis.
o.i., olive inferior.
occ.p., occipital pole.
o.ch., see *c.o.*
op.t., optic tract.
o.s.p., olive-shaped process.
o.tr., see *tr.o.*
p., pons.
paleostr., paleostriatum.
par., lobus parietalis.
pars ant. n.v.s., pars anterior of n.v.s.
pars med. et vent., *n.l.s.*, pars medialis et pars ventralis of n.l.s.
pars preop., pars preoptica.
pars subth., pars subthalamica.
pes ped. or *p.p.*, see *b.p.*
p.col., posterior colliculus.
p.f., paraflocculus.
p.fl., paraflocculus.
p.g., pineal gland.
p.l.h., lobus posterior hypophysis.
p.o., principal olive.
poly.m.c., polymorphous cells.
polym.c., polymorphous cells.
put., putamen.
pyr., pyramis.
pyr.c., pyramidal cells.
pyr.l., pyriform lobe.
R.d.Z., Riechbundel des Zuckerkandl.
ret.cells, reticular cells.
r.iii., radix nervi oculomotorii.
r. man., radix mandibularis.
r. max., radix maxillaris.
r.m.v., radix mesencephalica trigemini.
r.vii., radix nervi facialis.

r.viii., radix nervi auditorii.
r.xii., radix nervi hypoglossi.
sept., septum, or the paraterminal body of ELLIOT SMITH.
s.f.n.o., stratum fibrarum nervi olfactorii.
s.f.z., stratum fibrarum zonalium.
s.g., stratum gelatinosum.
s.g.i., stratum granulosum internum.
s.gl., stratum glomeruli.
s.g.m., stratum griseum mediale.
s.g.p., stratum griseum profundum.
s.g.per., stratum griseum periependemale.
s.gr., stratum of granular cells.
s.gr.e., stratum granulosum externum.
s.gr.i., stratum granulosum internum.
s.g.s., stratum griseum superficiale.
s.l., stratum lacunosum.
s.m., stratum medullare.
s.m.m., stratum medullare mediale.
s.m.p., stratum medullare profundum.
s.m.s., stratum medullare superficiale.
s.n., substantia nigra.
s.o., superior olive.
s.o. ?, dorso-lateral superior olivary nucleus ?
s.o.f., stratum fibrarum olfactorii.
s.o.K., superior olive of Koelliker.
s.op., stratum opticum.
s.p., stratum of polymorphous cells.
s.p.fl., sulcus paraflocculo-flocculus.
s.r.f., stratum tangentium fibrarum.
s.t.o., stratum tracti olfactorii.
str.m. (*preop.*), stria medullaris (preoptic division).
str.m.th., or *str.m.t.*, stria medullaris thalami.
str.m.th.l., stria medullaris thalami, lateral division.
str.t., stria terminalis.
str.t.h.c., stria terminalis, hypocommissural bundle.
str.t.l., stria terminalis lateralis.
str.t.m., stria terminalis medialis.
str.z., stratum zonale.
sub., subiculum.
subth., subthalamus.
s.u.n., sulcus uvulo-nodularis.
supracom.b., supracommissural bundle of stria terminalis.
s.z., stratum zonale.
s.z.s., stratum zonale subiculi.
t., tuber.
t.c., tuber cinereum.
teg., tegmentum.

tel., telencephalon.
temp.l., lobus temporalis.
th., or *thal.*, thalamus.
thal.lat., lateral part of thalamus.
thal.med., medial part of thalamus.
th.op., thalamus opticus.
t.o., tuberculum olfactorium.
tr.b.c., tractus bulbo-corticalis.
tr.c.b., tractus cortico-bulbaris.
tr.c.h., tractus cortico-habenularis.
tr.c.h.l., tractus cortico-habenularis lateralis.
tr.c.h.m., tractus cortico-habenularis medialis.
tr.c.m., tractus cortico-mamillaris.
tr.c.o., tractus cortico-olfactorius.
tr.c.r., tractus cerebello-rubricus.
tr.c.s., tractus cortico-septalis.
tr.c.sp., tractus cortico-spinalis.
tr.c.t., tractus cortico-tubercularis.
tr.d.r.et.th., tractus dentato-rubricus et thalamicus.
tr.F., tractus Fuse.
tr.h.l.s., tractus habenulo-lateralis superficialis.
tr.h.th.p., tractus hypothalamico-peduncularis.
tr.h.th., tractus habenulo-thalamicus.
tr.h.th.p., tractus hypothalamo-peduncularis.
tr.i.p., tractus interpedunculo-peduncularis.
tr.i.r., tractus interstitio-rubricus.
tr.i.t., tractus interstitio-tegmentalis.
tr.m.p., tractus mamillo-peduncularis.
tr.m.p.d., tractus mamillo-peduncularis dorsalis.
tr.m.p.v., tractus mamillo-peduncularis ventralis.
tr.m.q.c., tractus mesencephalicus quinto-cerebellaris.
tr.m.th., tractus mamillo-thalamicus.
tr.m.t.l., tractus mamillo-tectalis lateralis.
tr.o., tractus olfactorius.
tr.o.c., tractus olfacto-corticalis.
tr.o.h.l., tractus olfacto-habenularis lateralis.
tr.o.h.m., tractus olfacto-habenularis medialis.
tr.o.h.th., tractus olfacto-hypothalamicus.
tr.o.i., tractus olfactorius intermedius.
tr.o.l., tractus olfactorius lateralis.
tr.ol.m., tractus olfactorius medialis.
tr.o.m., tractus olfactorius mamillaris.
tr.op., or *tr.o.*, tractus opticus.
tr.o.p.C., tractus olfactorius projectionis Cajal.
tr.o.p.v., tractus olfactorius projectionis ventralis.
tr.o.s.c., tractus olfactorius subcommissuralis.
tr.o.th., tractus olfacto-thalamicus.

tr.p.p., tractus pretecto-peduncularis.
tr.q.c., tractus quinto-cerebellaris, the same tract as *tr.m.q.c.*
tr.r.sp., tractus rubro-spinalis.
tr.s.c., tractus septo-corticalis.
tr.s.c.l., tractus septo-corticalis lateralis.
tr.s.c.m., tractus septo-corticalis medialis.
tr.s.h., or *tr.s.hab.*, tractus septo-habenularis.
tr.s.h.d., tractus septo-hypothalamicus dorsalis.
tr.s.h.v., tractus septo-hypothalamicus ventralis.
tr.s.o., tractus subthalamo-olivaris.
tr.s.p., tractus subthalamo-peduncularis.
tr.s.p., in fig. 79, tractus vestibulo-spinalis.
tr.sp.t., tractus spinalis trigemini.
tr.s.s., tractus septo-subcommissuralis (part of medial fore-brain bundle).
tr.s.s.et th., tractus septo-subcommissuralis et thalamicus.
tr.s.t., tractus spino-trigeminus.
tr.s.th., tractus septo-thalamicus.
tr.str.h.th., subth., et mes., tractus strio-hypothalamicus, subthalamicus et mesencephalicus.
tr.str.s.et m., tractus strio-subthalamicus et mesencephalicus.
tr.st.th., or *tr.str.th.*, tractus strio-thalamicus.
tr.st.th.d., tractus strio-thalamicus dorsalis.
tr.st.th.v., tractus strio-thalamicus ventralis.
tr.s.V., tractus sensorius trigeminus.
tr.t.a.s., tractus tuberculo-area subcommissuralis.
tr.t.b., tractus tecto-bulbaris.
tr.t.c., tractus tuberculo-corticalis.
tr.t.c., tractus trigemino-cerebellaris.
tr.t.c.d., tractus tecto-cerebellaris dorsalis.
tr.t.c.v., tractus tecto-cerebellaris ventralis.
tr.te.h.th., tractus tegmento-hypothalamicus.
tr.te.s., tractus tegmento-subthalamicus.
tr.te.th.a., tractus tegmento-thalamicus anterior.
tr.te.th.m., tractus tegmento-thalamicus medialis.
tr.te.th.m. et s. et h.th., tractus tegmento-thalamicus medialis et subthalamicus et hypothalamicus.
tr.t.h., tractus tecto-habenularis.
tr.th.c., tractus thalamo-corticalis.
tr.th.h., tractus thalamo-hypothalamicus.
tr.th.o., tractus thalamo-olivaris.
tr.th.str., tractus thalamo-striaticus.
tr.th.str.d., tractus thalamo-striaticus dorsalis.
tr.th.str. or *tr.th.str.v.*, tractus thalamo-striaticus ventralis ?
tr.th.t., tractus thalamo-tegmentalis.
tr.t.h.th., tractus tecto-hypothalamicus.
tr.t.l.s., tractus tecto-lateralis superficialis.
tr.t.o.h.th., combined tractus tuberculo-olfacto-hypothalamicus.
tr.t.p., tractus tecto-pretectalis.
tr.t.s., tractus tecto-subthalamicus.

tr.t.sp., tractus tecto-spinalis.
tr.t.s.v., tractus tecto-subthalamicus ventralis.
tr.t.teg., tractus tecto-tegmentalis.
tr.t.th., tractus tecto-thalamicus.
tr.t.th.a., tractus tecto-thalamicus anterior.
tr.t.th.a. et m., or *tr.t.t.m. et a.*, tractus tecto-thalamicus anterior et medialis.
tr.t.th.l., tractus tecto-thalamicus lateralis.
tr.t.th.m., tractus tecto-thalamicus medialis.
tr.tub.c., tractus tuberculo-corticalis.
tr.tub.s.c., tractus tuberculo-subcommissuralis.
tr.v.c., tractus tuberculo-corticalis.
tr.v.c., tractus vestibulo-cerebellaris.
tr.v.sp., tractus vestibulo-spinalis.
u., uvula.
v.c., commissura ventralis.
v.iii., ventriculus tertius.
v.l., ventriculus lateralis.
v.l.n.o., ventro-lateral nucleus of the inferior olive.
x., Ingvar's designation for fissura prima.
y., Ingvar's designation for fissura suprapyramidalis.
z., Ingvar's designation for fissura secunda.

DESCRIPTION OF FIGURES.

PLATE 41.

FIG. 1.—This is a photograph of the brain of Platypus taken *in situ*. The walls of the cranium have been removed, so that the whole is revealed in its relation to the eyes and the interesting fleshy rostrum which bears the openings of the nostrils, the so-called duck's bill. S. T. N. × 1.

FIGS. 2 to 11.—These are photographs of a sagittal series, at one time a part of Sir VICTOR HORSLEY's collection. × 4.

FIG. 2.—This section is taken slightly lateral to the median plane and shows the mesencephalic root of the fifth nerve, the fasciculus longitudinalis medialis, the roots of the oculo-motor nerve, the dorsal and ventral commissures, the fornix and the corpus mamillare.

FIG. 3.—Through the septum, the tuberculum olfactorium, the corpus mamillare and the ganglion inter pedunculare. It shows the trigeminal lemniscus and the medial portion of the sensory nucleus of the fifth.

PLATE 42.

FIG. 4.—Through the trabecula and the stria medullaris thalami showing in particular the tecto-cerebellar tracts, the lateral cells of the mesencephalic nucleus of the trigeminus, the tractus strio-thalamicus ventralis and the tractus septo-corticalis.

FIG. 5.—Section showing the tractus habenulo-mamillaris, the fasciculus retroflexus, another tecto-cerebellar system, the trigeminal lemniscus, the commissura thalami, the medial nucleus of the cerebellum, and the great tegmental systems.

FIG. 6.—Section through the medial fibres of the cerebello-ruber fibre system, the lateral ventricle, the hippocampus, the fascia dentata and the tractus mamillo-thalamicus.

PLATE 43.

FIG. 7.—Through the inferior and superior colliculi showing the following tracts: strio-thalamic, the septo-thalamic and mesencephalic tracts, the lateral lemniscus, the brachium conjunctivum and the optic tract.

FIG. 8.—Section taken through the lateral part of the medulla, the corpus restiforme, the cerebellum, the thalamus, the anterior lateral part of the corpus striatum and the amygdaloid nuclei.

PLATE 44.

FIG. 9.—The rhombencephalon and prosencephalon may be seen lateral to the level of fig. 8, showing in particular the nuclei of the stria terminalis, the stria itself, and the medial and basal nuclei of the amygdala.

FIG. 10.—Section more lateral than fig. 9: the stria terminalis and three of the amygdaloid nuclei are easily distinguished lying above the fibres of the external capsule.

FIG. 11.—In this level the corpus striatum surrounds the numerous posterio-lateral extension of the nucleus lateralis thalami.

PLATE 45.

FIGS. 12 to 31 *b*.—These figures are photographs at various levels of the transverse Weigert series belonging to Prof. ELLIOT SMITH. × 6.

FIG. 12.—Through the level of the nucleus of the tenth and twelfth motor nerves, the nucleus gracillis and the inferior olive.

FIG. 13.—At the level of the rostral part of the eighth nerve, showing also the sensory nucleus of the fifth, the inferior olive, the medial, lateral and spinal nuclei of the vestibular system, the nucleus cuneatus and the lateral nucleus of the cerebellum.

FIG. 14.—Through the radix and nucleus of the facial nerve, showing the dorsal and ventral cochlear nuclei, the lateral lemniscus and the superior olive.

PLATE 46.

FIG. 15.—Through the dorsal motor nucleus of the tenth, the nucleus of the fasciculus solitarius, the lateral and medial cerebellar nuclei and the nucleus cuneatus.

FIG. 16.—This level is slightly cephalward of the preceding figure showing the dorsal motor nucleus of the vagus, the spinal nucleus of the vestibular group and many internal arcuate fibres.

FIG. 17.—Through the level of the superior olive, the trapezoid body, the sensory nucleus of the trigeminus, the brachium conjunctivum and the inferior colliculus.

PLATE 47.

FIG. 18.—Through both colliculi, the motor nucleus of the fifth nerve and the pons, showing the basal amygdaloid nucleus and the hippocampus.

FIG. 19.—This section passes through the caudal portion of both colliculi and the largest part of the sensory fifth nucleus. It shows also the nucleus of the stria terminalis, the hippocampus, the nucleus amygdalæ basalis, the lemnisci medialis, lateralis, et trigeminus and the brachium conjunctivum.

PLATE 48.

FIG. 20.—Through the superior colliculus, the ganglion interpedunculare, the nuclei of the pons and the pes pedunculi. It shows the stria terminalis cut in two places, the lateral geniculate body and the nuclei of the stria terminalis.

FIG. 21.—Through the caudal part of the superior colliculus and the sensory nucleus of the trigeminus, cutting the lateral geniculate body, the lateral nucleus of the thalamus, the lateral and medial nuclei of the amygdaloid complex.

PLATE 49.

FIG. 22.—This section is taken at the level of the commissure superior, the great lateral nucleus of the thalamus, the corpus mamillare and the basal amygdaloid nucleus.

FIG. 23.—Through the level of the habenula, and the hypothalamus showing the optic tract, the nucleus opticus thalami, the medial nucleus, the most anterior portion of the nucleus lateralis, the lateral and anterior nuclei of the amygdaloid complex and the corpus striatum.

PLATE 50.

FIG. 24.—Through the main body of the thalamic commissure cutting the nuclei anterior and lateral of the amygdala, the nucleus reuniens and the nucleus medialis.

FIG. 25.—Through the stria medullaris thalami, the anterior and medial thalami nuclei, the medial forebrain bundle, the fornix, the optic chiasma and the major part of the internal capsule fibres.

PLATE 51.

FIG. 26.—Section is taken at the level of the main body of the anterior commissure, showing the stria terminalis, the caudate-lentiform complex, the lateral olfactory nucleus and the pyriform lobe.

FIG. 27.—Through the region of the septum cephalward to the anterior commissure. The rhinal fissure, the lateral olfactory tract, the hippocampus with the fascia dentata and the anterior part of the corpus striatum are plainly visible.

PLATE 52.

FIG. 28.—Through the tuberculum olfactorium, the pyriform lobe, the hippocampus, the fascia dentata and the septum.

FIG. 29.—Just anterior to the tuberculum olfactorium through the cephalad part of the corpus striatum.

PLATE 53.

FIG. 30.—Through the root of the olfactory bulb, and the nucleus olfactorius anterior.

FIG. 31 (*a*).—Through the posterior part of the bulbus olfactorius. (*b*) Through the middle part of the bulbus olfactorius.

PLATE 54.

FIG. 32 (*a*).—Photomicrograph taken through the ventral nucleus of the facial nerve, showing what the writer thinks to be the superior olive, as well as the direct fibres of the secondary acoustic tract of von Monakow. Bielschowsky series. 28.3. × 46.

FIG. 32 (*b*).—Through the more ventral of the dorsal seventh nuclei, showing the ventral facial nucleus, three possible divisions of the superior olive, and the dorsal (von Monakow) and the intermediate (Held) decussations of the lateral lemniscus. W. T. B. 31.3. × 46.

FIG. 32 (*c*).—Through the ventral nucleus of the seventh nerve, showing two parts of the superior olive, a possible nucleus of the trapezoid body and the trapezoid body. W. T. B. 32.2. × 46.

FIG. 33 (*a*).—Photomicrograph taken through the nucleus ruber and the substantia nigra in the level of the corpus mamillare, showing a possible caudal nucleus of the tractus opticus accessorius posterior. W. T. B. 139.1. × 120.

PLATE 55.

FIG. 33 (*b*).—Photomicrograph taken through the midbrain, showing three nuclei of the oculomotor nerve the fasciculus longitudinalis medialis and its nucleus, together with the richly cellular central gray. W. T. B. 109.2. × 32.

FIG. 33 (*c*).—Through the midbrain, showing the more caudal level of the nucleus fasciculus longitudinalis medialis, the two divisions of the commissura posterior, and the corpus ellipticum. W. T. B. 140.2. × 32.

FIG. 33 (*d*).—Through the midbrain, showing the commissura posterior and the corpus ellipticum. W. T. B. 146.3. × 32.

FIG. 34.—Photograph of a section from Prof. WILSON'S Bielschowsky series showing the pyriform lobe and the amygdaloid complex. 123.1. × 12.

PLATE 56.

FIGS. 35 to 43.—Pen-and-ink sketches of Prof. WILSON'S sagittal Weigert series, drawn with camera lucida and dissecting microscope. (Only the more prominent fibre systems could be included.) × 4.

FIG. 35.—Through the ventral expansion of the third ventricle. 39.1.2.

FIG. 36.—Through the ganglion interpedunculare. 38.1.2.

FIG. 37.—Through the tegmento-thalamic tracts, lateral to fig. 36. 36.1.2.

PLATE 57.

FIG. 38.—Through the main body of the stria medullaris thalami. 35.1.2.

FIG. 39.—Through the tecto-thalamic system lateral of the stria medullaris. 34.1.2.

FIG. 40.—Lateral to fig. 39, showing the tecto- and thalamo-tegmental tracts. 31.1.2.

PLATE 58.

FIG. 41.—This sketch shows the level which contains the more lateral of the tecto-cerebellar connections. 30.1.2.

FIG. 42.—Through the main portion of the fibre system of the cerebellum, showing in particular the brachium conjunctivum. 28.1.2.

FIG. 43.—Section passes through mid-lateral portion of the thalamus and midbrain, shows the fibre tracts connecting the striatum with the diencephalon and mesencephalon. 24.1.2.

PLATE 59.

FIG. 44.—Wash drawing of the lateral surface of a wax model of the medulla : midbrain and thalamus, after removal of the cerebellum, the corpus striatum and the telencephalon. × 6.

FIG. 45.—Wash drawing of the medial surface of a wax model of the corpus striatum, made by dissecting away the surrounding parts of the model of the whole brain, including the globus pallidus. Made from Prof. ELLIOT SMITH'S transverse Weigert series. × 6.

PLATE 60.

FIG. 46.—Pen-and-ink drawing of the whole brain from which Prof. WILSON'S Bielschowsky series was cut. (*a*) Dorsal view. (*b*) Ventral view showing the peculiar enlargement of the nucleus of sensory part of the trigeminal nerve. (*c*) Pen-and-ink drawing of the medial surface of a brain, from which the greater part of the diencephalon has been removed, showing in particular, the hippocampus, the fascia dentata and the septum, *i.e.*, ELLIOT SMITH'S paraterminal body. Drawn from a poorly preserved brain removed from a Platypus belonging to Prof. WATSON'S collection. (*a*) and (*b*) × 1·5, (*c*) × 2.

FIG. 47.—Pen and-ink sketches of the cerebellum, drawn from specimens belonging to Prof. J. T. WILSON and Prof. D. M. S. WATSON. (*a*) Lateral aspect. (*b*) Medial sagittal section.

Plate 61.

Fig. 47.—(*c*) Dorsal view. (*d*) Dorsal anterior showing the full content of the anterior lobe. (*e*) Ventral aspect showing the posterior lobe and the attachments of the cerebellar peduncles. (*f*) Various views of the flocculus and paraflocculus of a young Ornithorhynchus. (*g*) The lateral caudal aspect of the cerebellum of an adult showing a greater complication of the flocculus and paraflocculus. × 3·2.

Plate 62.

Figs. 48 and 49.—Camera lucida drawing of the levels about the transition between the hippocampus and the pyriform amygdaloid complex in the region of the tip of the temporal pole.

Fig. 48.—Anterior to the transition. Slide 12, number 2, on row 1. × 20.

Fig. 49.—At the beginning of the transition. Slide 24, and section 135. × 17·5.

Figs. 50 and 51. Camera lucida sketches of the pyriform lobe and its fibres, taken from Prof. Elliot Smith's transverse Weigert series. × 15.

Fig. 50.—Pyriform lobe, hippocampus and fibre relations, sec. No. 128.

Fig. 51.—Pyriform lobe and immediate fibre connection, sec. No. 180.

Fig. 52.—Camera lucida drawing from sagittal section taken near the midline showing fibres at the base of the olfactory bulb. Slide 34, section 60, Wilson transverse series. × 15.

Fig. 53.—Camera lucida drawing of the nucleus ruber at the level of the decussation of the brachium conjunctivum, from Wilson's transverse Weigert brain. 21.3, section No. 129. × 16·6.

Plate 63.

Figs. 54 to 62.—These drawings of various regions of the Bielschowsky series of Wilson were made under a projection apparatus. It was attempted to copy the size, shape, and arrangement of cells, at the magnification used.

Fig. 54.—Through the pyriform lobe on the level of the anterior commissura, showing the arrangement of cells in the nucleus of the area subcommissuralis and that of the pyriform. 215.2. × 15·3.

Fig. 55.—Through the nuclei anterior and medialis of the thalamus, the anterior commissure, its nucleus and that of the bed of the stria terminalis. 204.3. × 15·3.

Fig. 56.—Through the anterior part of the corpus striatum in the region of the anterior commissure, the medial nucleus of the thalamus, and the nucleus of the bed of the stria terminalis. The internal capsule fibres divide the striatum, latero-medially. Dorsal to it lies an area of medium-sized cells, the nucleus caudatus, while ventral to it is a large lateral region of small cells, the putamen, a small latero-medial area, where the cells are similar to the nucleus caudatus, and a large region, characterised by very large triangular cells, the globus pallidus. 198.2. × 22·6.

Plate 64.

Fig. 57.—Through the thalamus caudal to the anterior commissure, showing the medial, the anterior and reuniens nuclei of the thalamus, the nucleus of the bed of the stria terminalis, the pyriform lobe and amygdaloid complex, the corpus striatum and especially the globus pallidus. 188.3. × 15·6.

Plate 65.

Fig. 58.—Drawing at the level of the tuber cinereum. The nuclei anterior and the medialis, together with the dorsal extension of the lateral thalamus are shown. The pons, the four nuclear divisions of the subthalamus, as well as the large motor cells of the tuber cinereum, are particularly prominent. 184.2. × 15·6.

PLATE 66.

FIG. 59.—Through the nucleus pretectalis and the three divisions of the lateral group of the dorsal thalamus. The lateral, central, basal and cortical nucleus of the amygdala are present. The large triangular-like cells, ventral to the nucleus pretectalis, are probably a part of the motor tegmentum of the midbrain. 146.2. × 15·6.

PLATE 67.

FIG. 60.—Through the nucleus pretectalis showing the difference between the size of cells of which it is made and those of the nearby areas. 136.3. × 30·6.

FIG. 61.—Drawing made from a section caudal to fig. 55, showing the medio-lateral relationship of position between the nucleus pretectalis and the tectum of the midbrain. The large spherical cells are those of the mesencephalic nucleus of the trigeminus. 130.2. × 15·3.

PLATE 68.

FIG. 62.—Through the region of transition from the pyriform cortex and nucleus amygdalæ corticalis to the hippocampus and fascia dentata. 81.1. × 7·6.

FIGS. 63 to 65.—These various groups of cells were drawn under the projection apparatus, at an original magnification of 250 diameters, in order to demonstrate that the different parts of the thalamus may be so distinguished.

FIG. 63.—The cells of the dorsal thalamus compared with those of the corpus striatum. (*a*) Those of the lateral nuclei of the dorsal thalamus. 146.8. (*b*) Those of the medial nuclei of the dorsal thalamus. 184.2. (*c*) Those of the corpus striatum. 198.2. × 125.

PLATE 69.

FIG. 64.—The cells of the ventral thalamus compared with those of other definitely motor areas of the thalamus. (*a*) Those of the four nuclei of the subthalamus. 184.2. (*b*) Those of the tuber cinereum region, both medial and lateral. 184.2. (*c*) Those of the caudal part of the tuber cinereum compared with those of the rostral part of the motor tegmentum of the midbrain. 140.2, compared with 126.2. × 125.

PLATE 70.

FIG. 65.—The outlines of the cells of the various nuclei connected with the stria terminalis system compared. 201.2 ; 184.2 ; 126.2 ; 113.1 ; 82.2. × 125.

PLATE 71.

FIGS. 66 to 70.—These drawings were made with a projection apparatus. The outline of each cell shown was placed there under the machine. An attempt was made to show the majority of the cells characteristic of the nucleus illustrated. All were drawn from WILSON'S Bielschowsky series, except fig. 70. × 45.

FIG. 66.—The pyriform lobe, the cortical and basal nuclei of the amygdaloid complex. 126.2. × 45.

PLATE 72.

FIG. 67.—The amygdaloid nuclei ; area immediately dorsal to fig. 47 ; from WILSON'S transverse Bielschowsky series. 126.2. × 45.

FIG. 68.—The nucleus ruber in the region of the substantia nigra. 126.1. × 45.

PLATE 73.

FIG. 69.—The nucleus ruber and the nucleus oculomotorius. (*a*) 118.2. (*b*) 123.2.

PLATE 74.

FIG 69.—(*c*) 125.2. × 60.

FIG. 70.—The inferior olive. (*a*) Through its caudal portion, together with the lateral reticular nucleus; drawn from the WATSON series. 16.2.3.

PLATE 75.

FIG. 70.—(*b*) Through the more caudal part anterior to the lateral reticular nucleus. 21.2.3. (*c*) Through the more cephalward part of the inferior olive. 23.1.5. (*d*) Through the most cephalward part of the inferior olive. 23.1.5. × 45.

FIGS. 71 to 75.—These sketches were drawn from the Nissl series of Prof. ELLIOT SMITH, with a projection apparatus at a magnification of 90 and reduced to 36 diameters.

PLATE 76.

FIG. 71.—Through the medulla, showing only the nuclei of the hypoglossal and the vagus nerves, the nucleus fasciculus solitarius and the vestibular nuclei. 21.3.1.

FIG. 72.—Through the medulla showing the nuclei of the sensory fifth, the twelfth motor, the dorsal motor tenth, the ninth, the nucleus ambiguous and the nucleus of the fasciculus solitarius.

PLATE 77.

FIG. 73.—Through the medulla showing in particular the sensory nucleus of the fifth, *i.e.*, the spinal portion, the nucleus of the hypoglossal nerve, that of the vagus, the nucleus fasciculus solitarius and the nucleus ambiguous. 14.1.6.

FIG. 74.—Section taken through the caudal part of the medulla. Showing the spinal division of the sensory nucleus of the trigeminus. 9.3.3.

PLATE 78.

FIG. 75.—Drawing from a transverse section, taken at the cephalad portion of the fourth ventricle, through the level of the motor nucleus of the trigeminus showing the division of the sensory nucleus of the fifth into two nuclei with a large medial and a smaller lateral. 58.1.2.

FIG. 76.—Camera lucida drawing of the hippocampus and fascia dentata, showing the medullated fibres as stained in the Weigert series, belonging to Prof. ELLIOT SMITH. It lies at a level anterior to the anterior commissure. No. 230. × about 15.

FIG. 77.—Camera lucida drawing of the cells of the precommissural hippocampus and fascia dentata as seen in Prof. ELLIOT SMITH's Nissl series. × about 15.

PLATE 79.

FIG. 78.—Diagram of the extent of the nuclei of the medulla projected upon what would be the floor of the fourth ventricle. From Prof. ELLIOT SMITH's transverse Weigert series.

FIG. 79.—Diagram of the fibre connections of the cerebellum.

FIG. 80.—Diagram of the fibre connections of the midbrain.

PLATE 80.

FIG. 81.—Diagram of the fibre connections of the paleo-thalamus.

FIG. 82.—Outline of the nuclei of the pars dorsalis thalami, projected upon the lateral surface of the outline of the wax model shown in fig. 39. S. T. W. series.

FIG. 83.—Diagram of the fibre connections of the non-olfactory part of the corpus striatum.

PLATE 81.

FIG. 84.—Diagram of the fibre connections of the amygdaloid complex.

FIG. 85.—Pen-and-ink drawing of the cerebellum of Echidna. (*a*) Lateral aspect. (*b*) Medial view. × 2·6.

FIG. 86.—Pen-and-ink drawing of the cerebellum of Didelphys virginiana. (*a*) Lateral aspect. (*b*) View of the mid-sagittal section. × 2·2.

FIG. 87.—Pen-and-ink drawing of the cerebellum of the common pigeon. (*a*) Lateral surface. (*b*) Section through the midline. × 2·2.

PLATE 82.

FIG. 88.—Three pen-and-ink sketches drawn with the camera lucida from WILSON's embryo Platypus. Delta four. (*a*) Through the septum, showing the lateral and medial root of the nucleus caudatus 7.3.5. (*b*) Through the ganglion, habenula, the medial nucleus and a slender nucleus which receives fibres from the optic tract. 9.2.6. (*c*) Through the caudal part of the Telencephalon cutting the depth of the fissura hippocampi. 11.1.7. × 33·3.

PLATE 83.

FIG. 89.—Four camera lucida drawings from WILSON's "Mammary Fetus," X, which measured 33 mm. along the dorsal curvature from tip of snout to tip of tail. (*a*) Through the septum, the lateral root of the nucleus caudatus is more developed at this stage, in comparison with the medial, than is ever found in reptiles. 20.3.5. (*b*) Through the ventral part of the thalamus and the main body of the corpus striatum. 19.1.8. (*c*) Through the medial nucleus of the thalamus and the caudal part of the corpus striatum. 18.1.9. (*d*) Through the midbrain and the caudal pole of the Telencephalon. 16.3.5. × 25·5.


S.t.n.

1

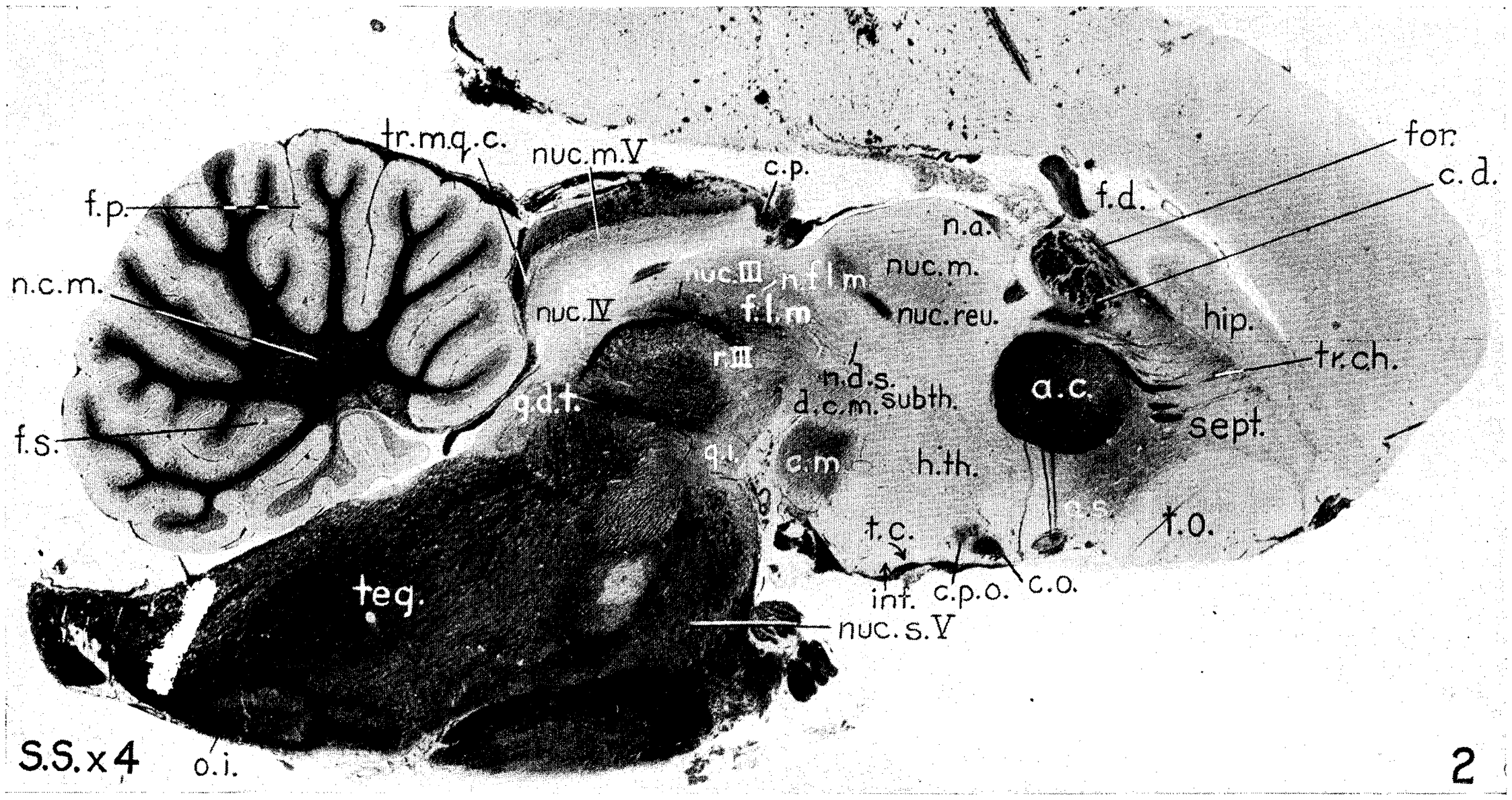
tr.m.q.c.
nuc.m.V
c.p.
for.
c.d.
f.d.
n.a.
f.p.
nuc.m.
n.c.m.
nuc.III
n.f.l.m.
nuc.IV
f.l.m.
nuc.reu.
hip.
r.III
n.d.s.
tr.ch.
a.c.
g.d.t.
d.c.m.
subth.
sept.
f.s.
q.i.
c.m.
h.th.
a.s.
t.o.
t.c.
teg.
inf.
c.p.o.
c.o.
nuc.s.V
S.S. x 4
o.i.

2

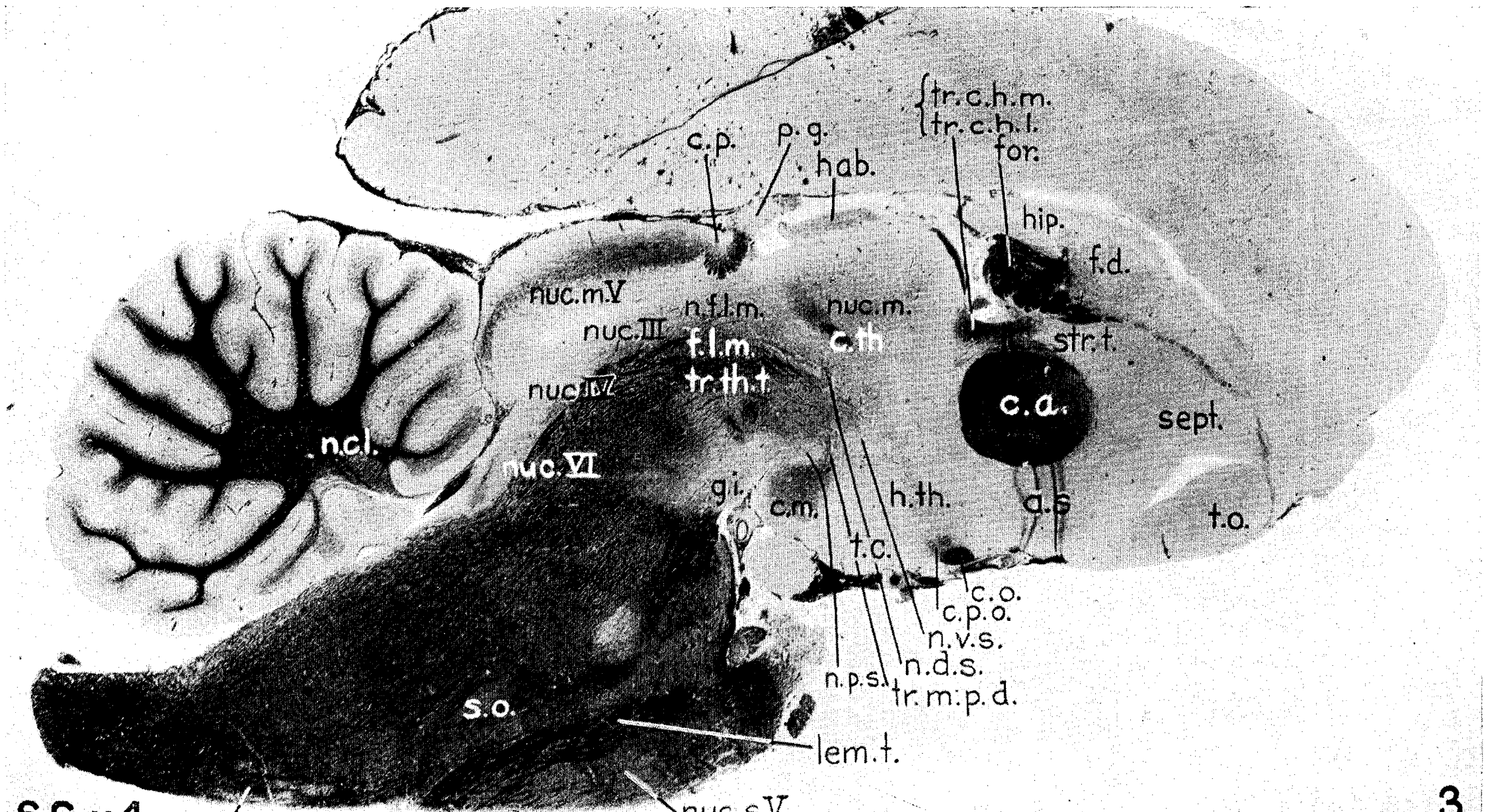
tr.c.h.m.
tr.c.h.l.
c.p.
p.g.
for.
hab.
hip.
f.d.
nuc.m.V
n.f.l.m.
nuc.m.
nuc.III
f.l.m.
c.th
str.t.
nuc.IV
tr.th.t.
c.a.
sept.
n.cl.
nuc.VI
g.i.
c.m.
h.th.
a.s
t.o.
t.c.
c.o.
c.p.o.
n.v.s.
n.d.s.
n.p.s.
tr.m.p.d.
s.o.
lem.t.
S.S. x 4
i.o.
nuc.s.V

3

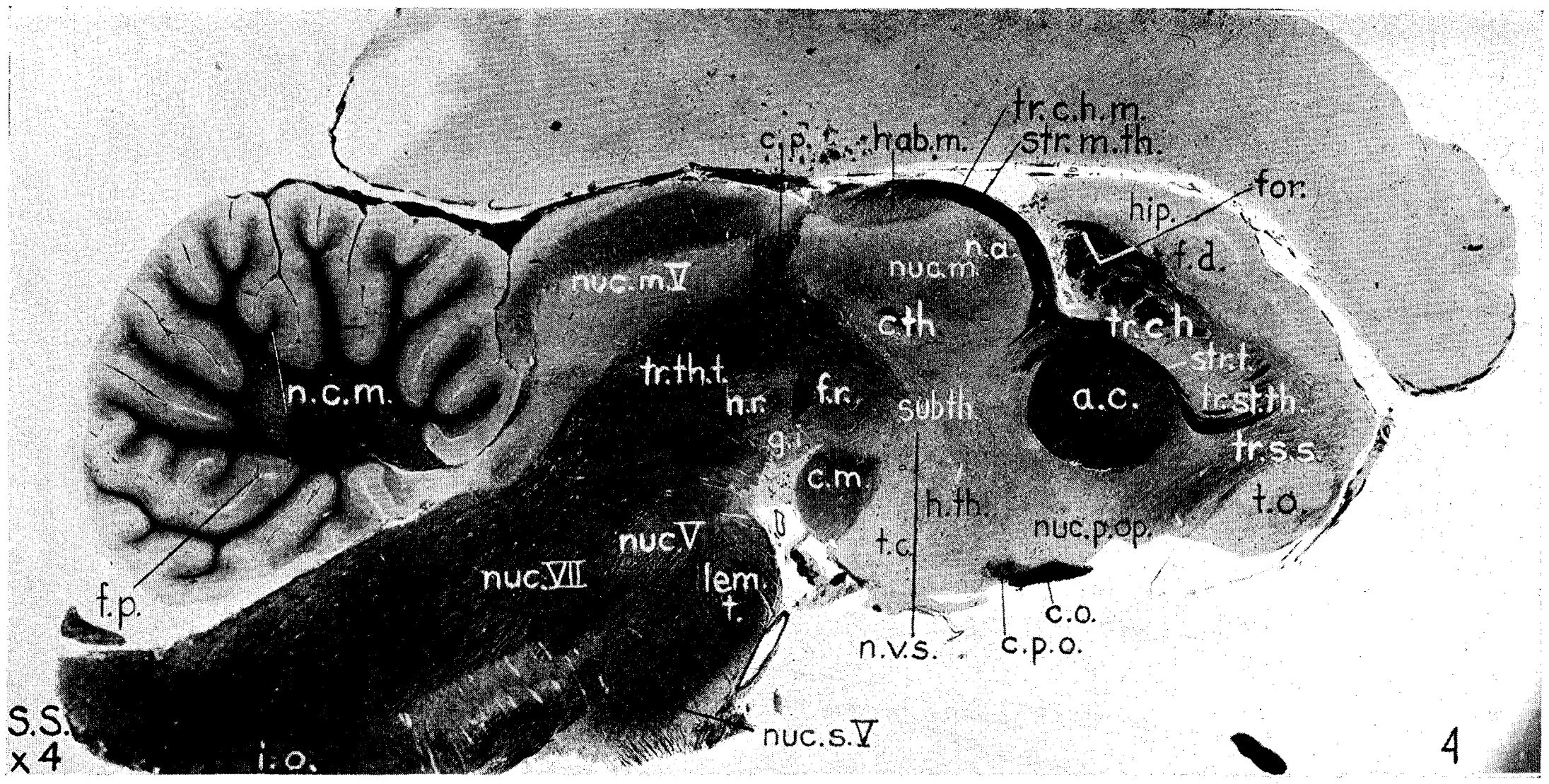
tr.c.h.m.
str.m.th.
c.p.
hab.m.
for.
hip.
f.d.
n.a.
nuc.m.
nuc.m.V
c.th.
tr.c.h.
str.t.
tr.st.th.
n.c.m.
tr.th.t.
n.r.
f.r.
subth.
a.c.
tr.s.s.
g.i.
c.m.
h.th.
t.o.
nuc.p.op.
nuc.V
t.c.
nuc.VII
lem.t.
f.p.
c.o.
n.v.s.
c.p.o.
S.S.
x 4
i.o.
nuc.s.V

4

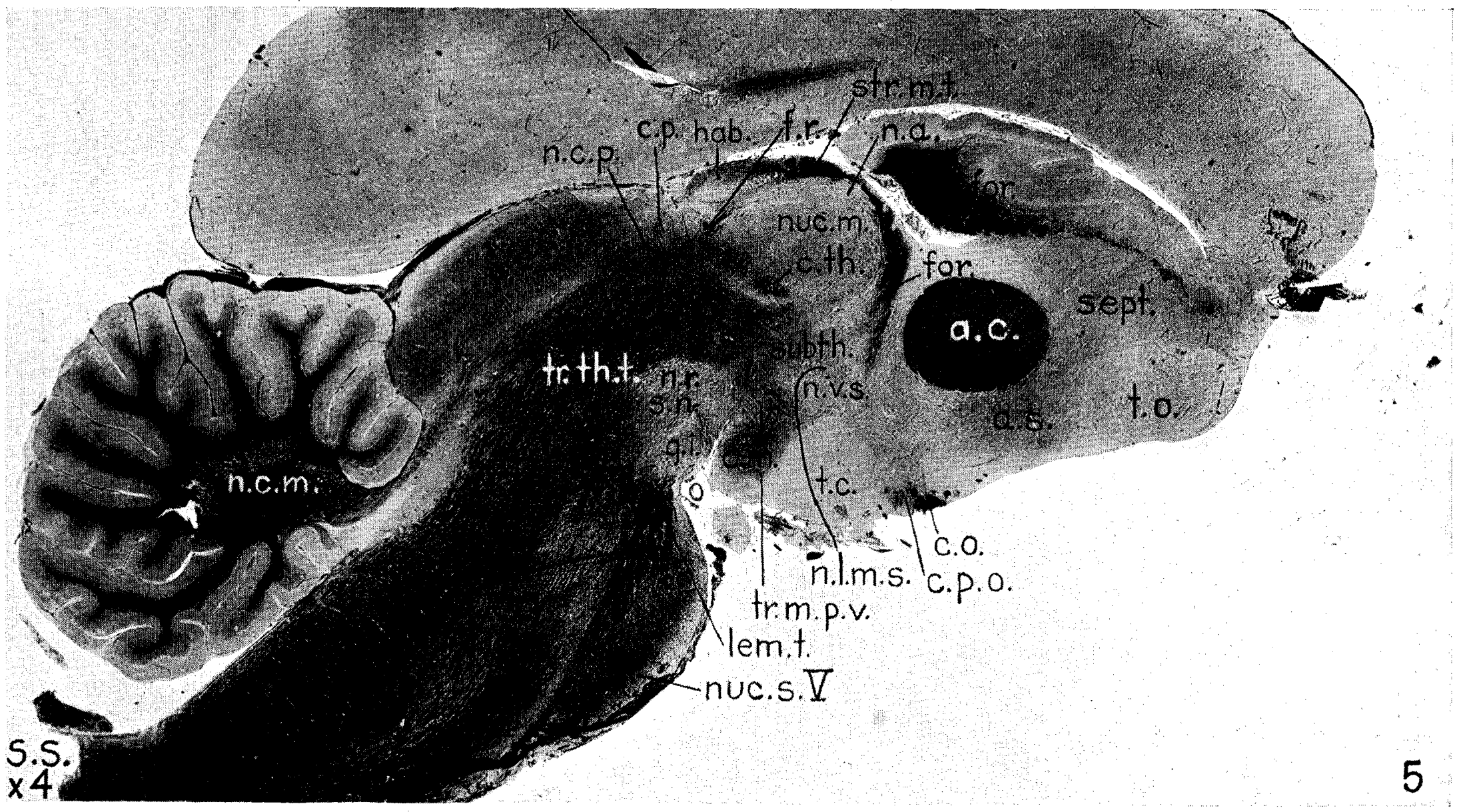
str.m.t.
c.p.
hab.
f.r.
n.a.
n.c.p.
for.
nuc.m.
c.th.
for.
sept.
a.c.
tr.th.t.
n.r.
s.n.
subth.
n.v.s.
a.s.
t.o.
g.i.
n.c.m.
t.c.
c.o.
n.l.m.s.
c.p.o.
tr.m.p.v.
lem.t.
nuc.s.V
S.S.
x 4

5

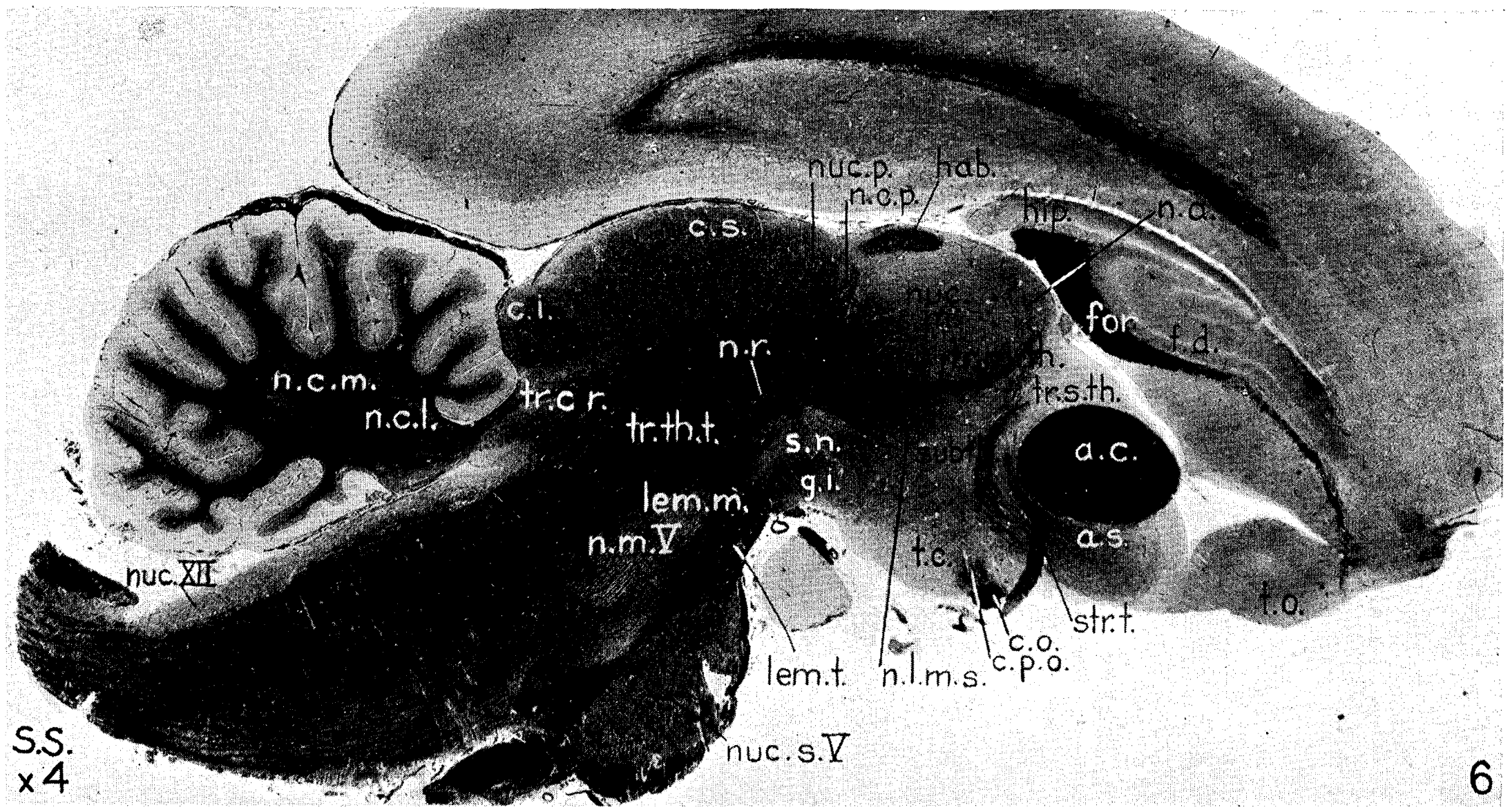
nuc.p.
hab.
n.c.p.
hip.
n.a.
c.s.
c.i.
for.
f.d.
n.r.
tr.s.th.
n.c.m.
n.c.l.
tr.c.r.
tr.th.t.
s.n.
a.c.
g.i.
lem.m.
n.m.V
a.s.
t.c.
nuc.XII
str.t.
t.o.
c.o.
c.p.o.
lem.t.
n.l.m.s.
nuc.s.V
S.S.
x 4

6

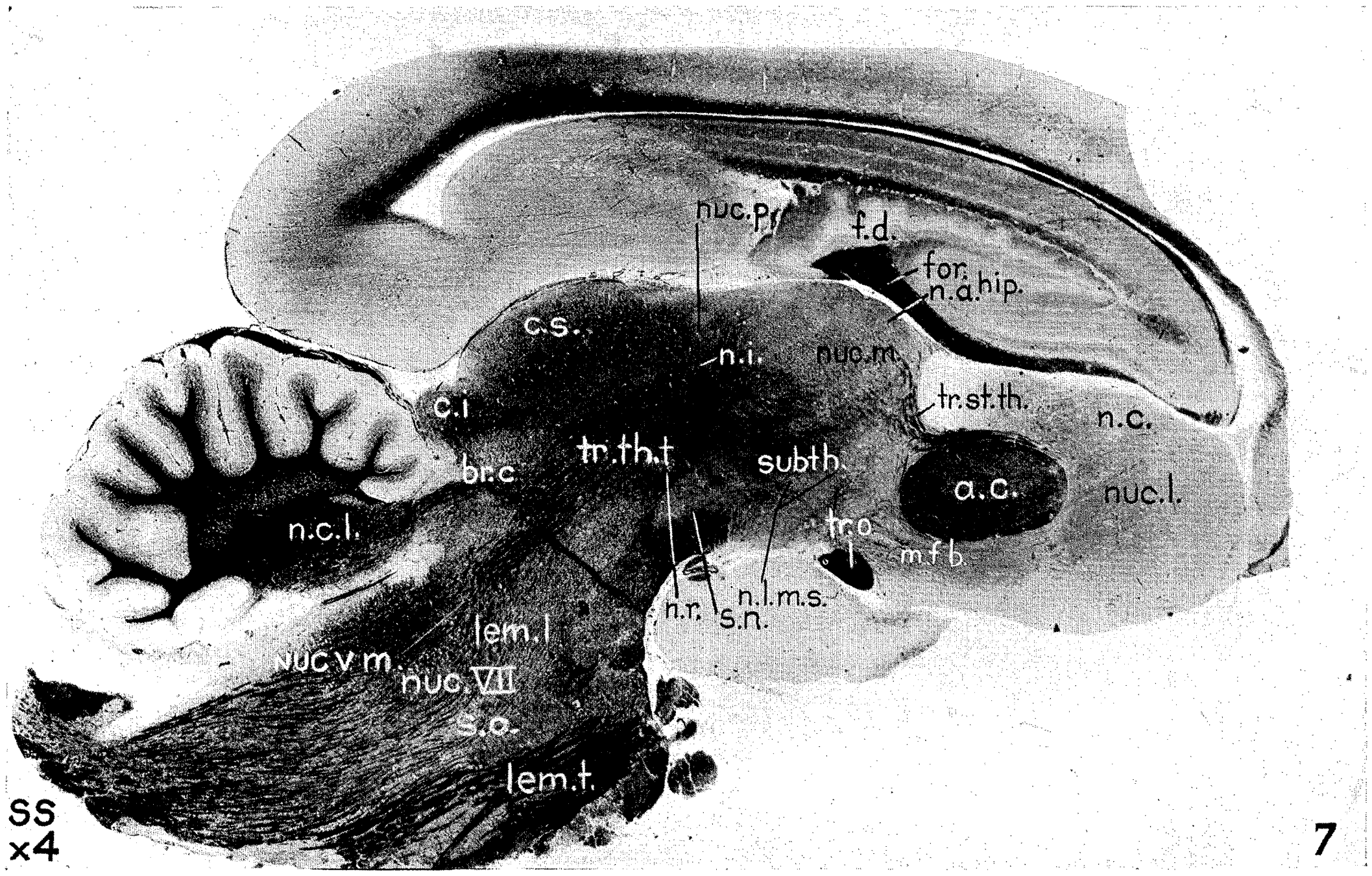
nuc.p.
f.d.
for.
n.a.
hip.
c.s.
n.i.
nuc.m.
tr.st.th.
n.c.
c.i
br.c
tr.th.t
subth.
a.c.
nuc.l.
n.c.l.
tr.o
m.f.b.
n.r.
s.n.
n.l.m.s.
lem.l
nuc.v.m.
nuc.VII
s.o.
lem.t.
SS
x4

7

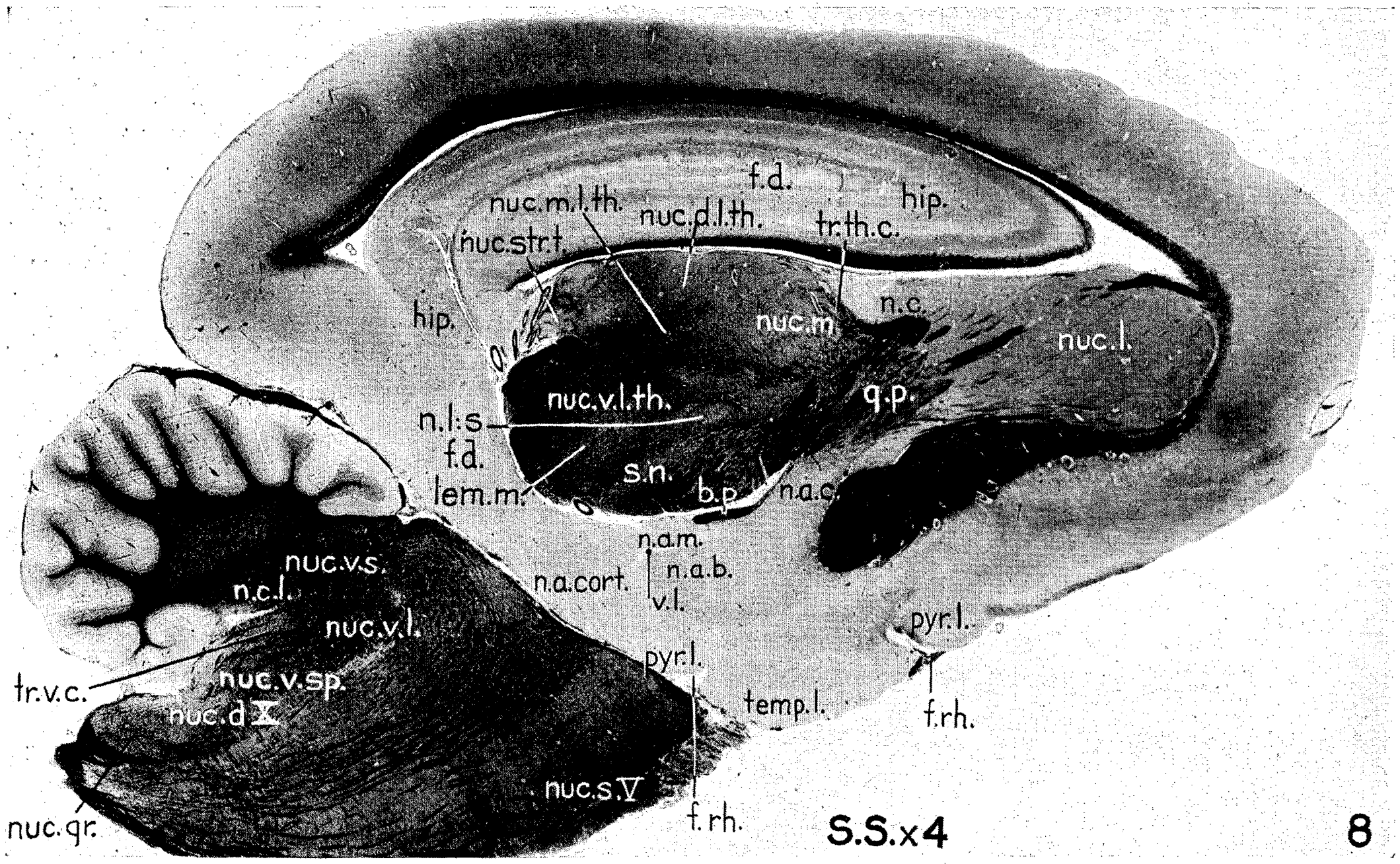
f.d.
hip.
nuc.m.l.th.
nuc.d.l.th.
tr.th.c.
nuc.str.t.
hip.
nuc.m.
n.c.
nuc.l.
nuc.v.l.th.
q.p.
n.l.s.
f.d.
s.n.
lem.m.
b.p.
n.a.c.
n.a.m.
n.a.b.
v.l.
n.a.cort.
nuc.v.s.
n.c.l.
nuc.v.l.
tr.v.c.
nuc.v.sp.
nuc.d.X
pyr.l.
pyr.l.
temp.l.
f.rh.
f.rh.
nuc.gr.
nuc.s.V
S.S.x4

8

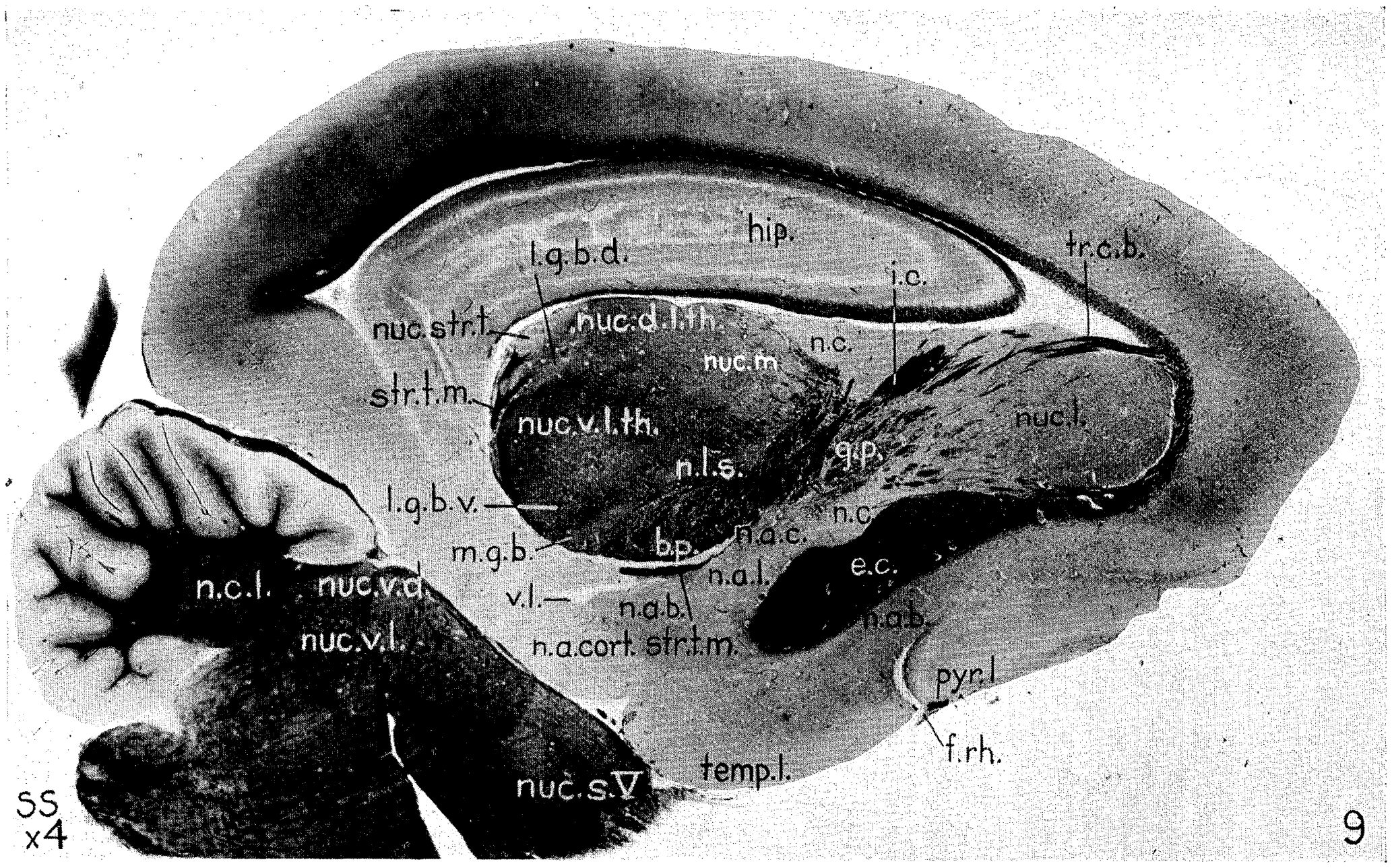
hip.
l.g.b.d.
tr.c.b.
i.c.
nuc.str.t.
nuc.d.l.th.
n.c.
nuc.m
str.t.m.
nuc.v.l.th.
nuc.l.
n.l.s.
g.p.
l.g.b.v.
n.a.c.
n.c.
m.g.b.
b.p.
n.a.l.
e.c.
n.c.l.
nuc.v.d.
v.l.
n.a.b.
n.a.b.
nuc.v.l.
n.a.cort.
str.t.m.
pyr.l.
f.rh.
temp.l.
nuc.s.V
SS
x4

9

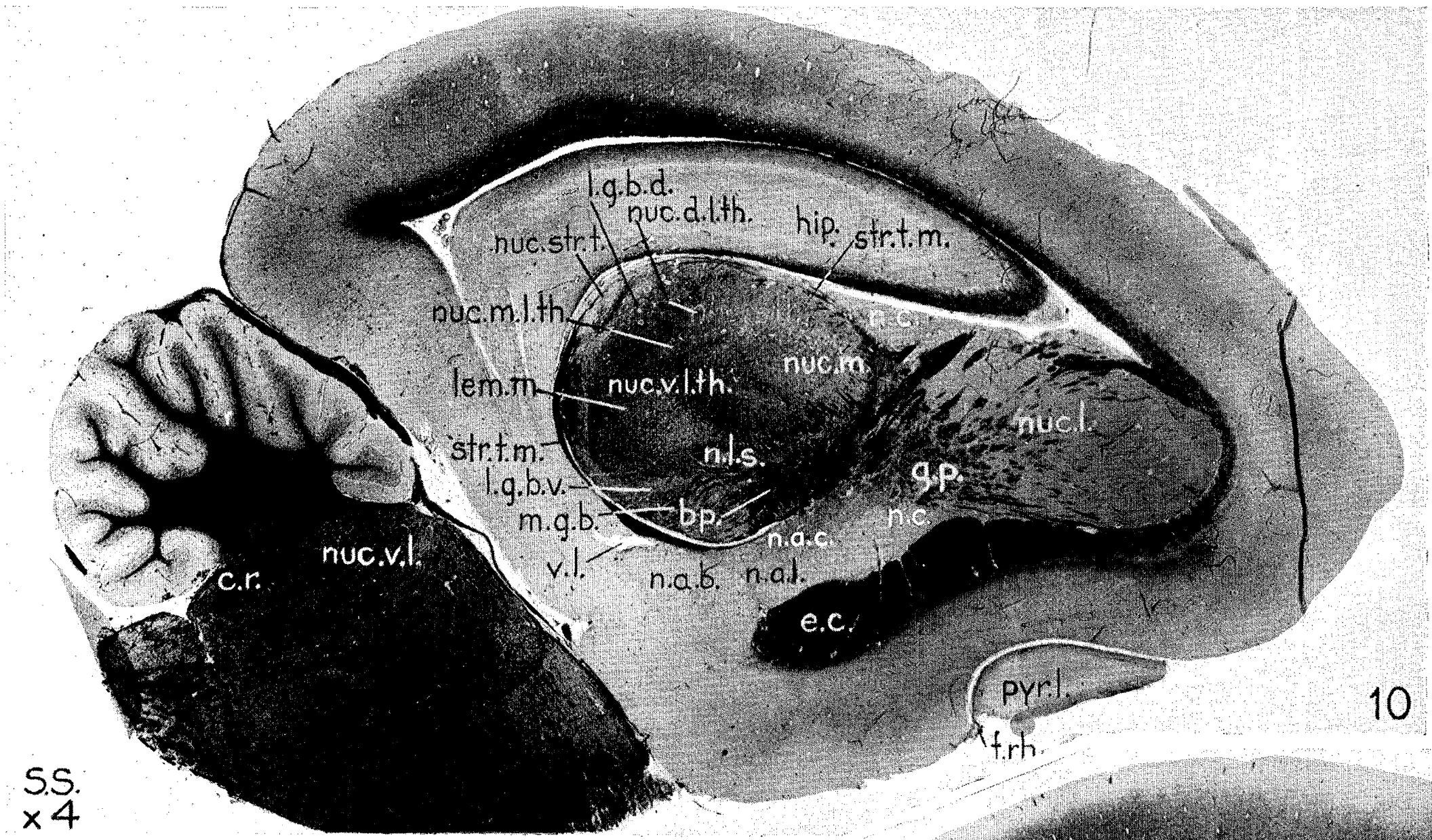
l.g.b.d.
nuc.d.l.th.
hip.
str.t.m.
nuc.str.t.
nuc.m.l.th.
n.c.
nuc.m
lem.m
nuc.v.l.th.
nuc.l.
str.t.m.
n.l.s.
g.p.
l.g.b.v.
m.g.b.
bp.
n.a.c.
n.c.
v.l.
n.a.b.
n.a.l.
c.r.
nuc.v.l.
e.c.
pyr.l.
f.rh.
S.S.
x 4

10

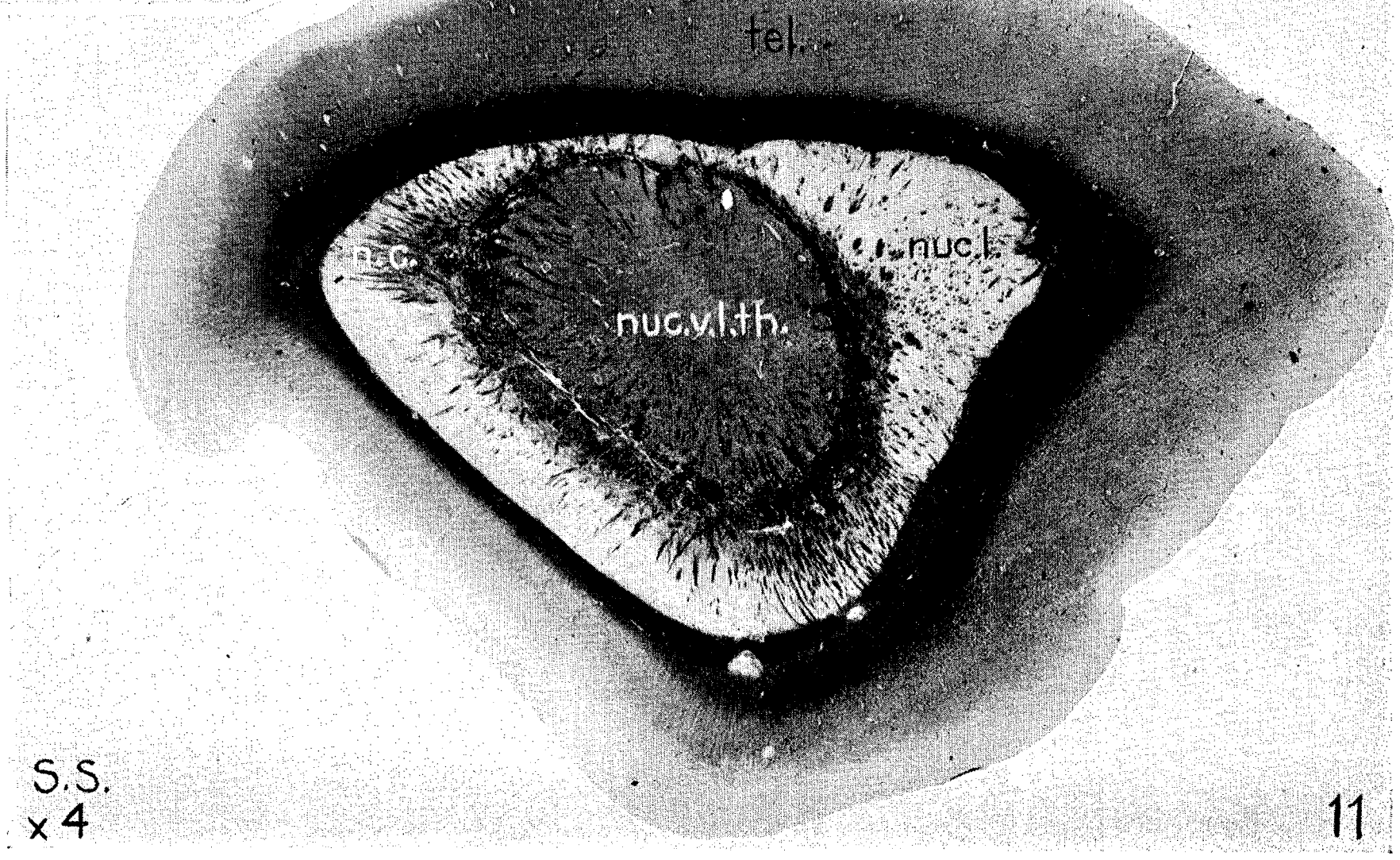
tel.
n.c.
nuc.l.
nuc.v.l.th.
S.S.
x 4

11

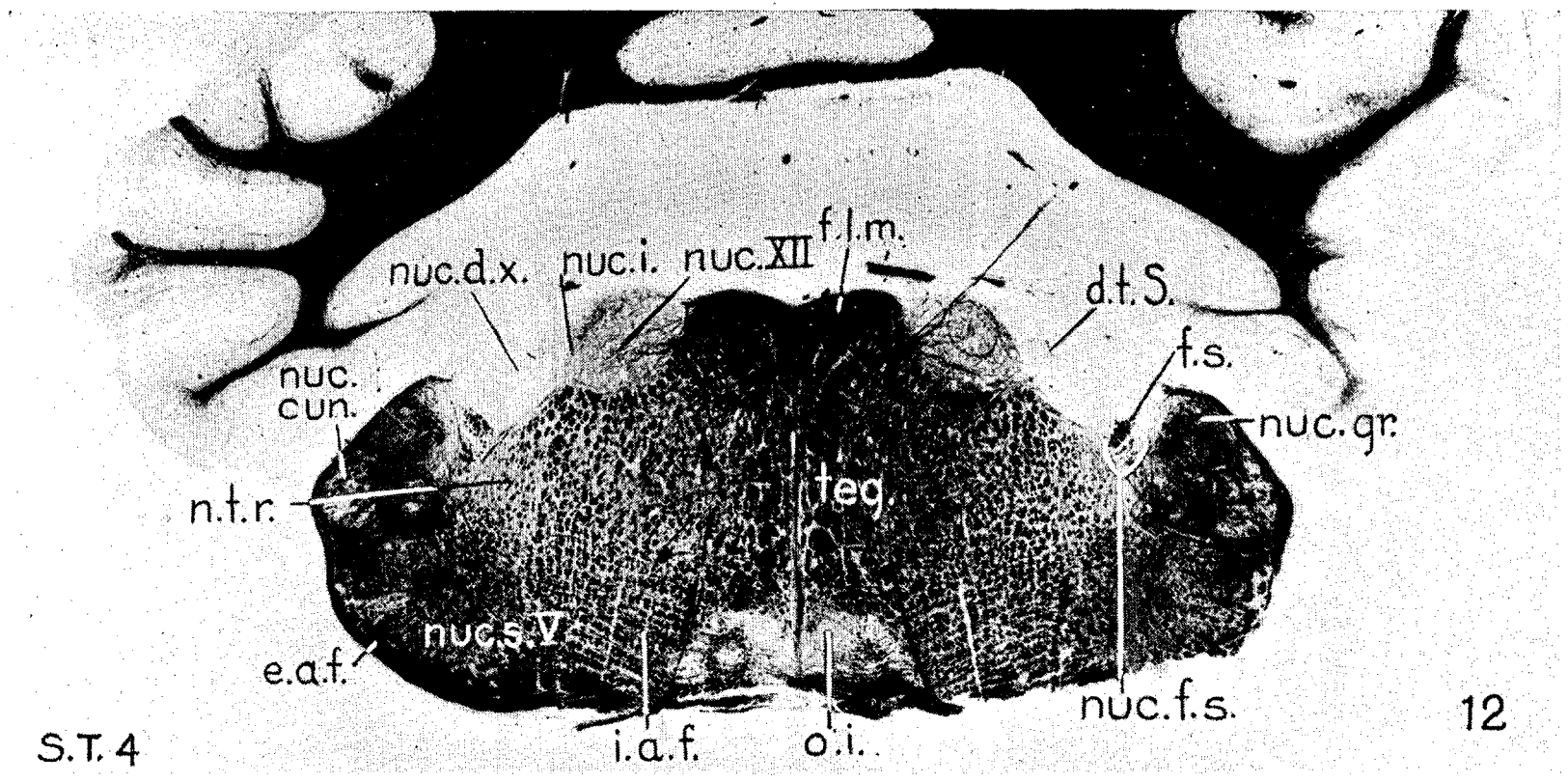
nuc.d.x.
nuc.i.
nuc.XII
f.l.m.
d.t.S.
f.s.
nuc.gr.
nuc. cun.
n.t.r.
teg.
nuc.s.V
e.a.f.
i.a.f.
o.i.
nuc.f.s.
S.T. 4

12

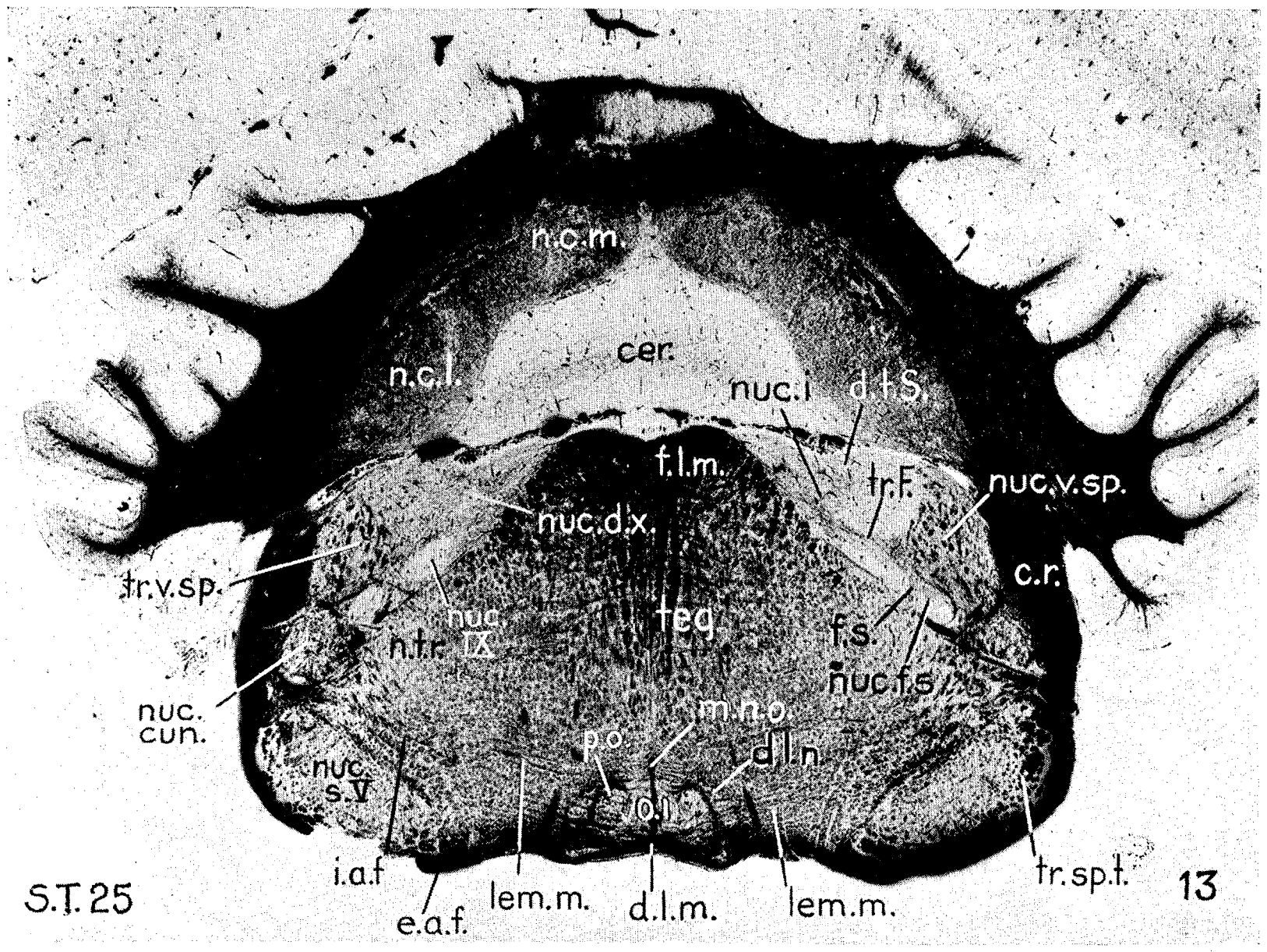
n.c.m.
cer.
n.c.l.
nuc.i
d.t.S.
f.l.m.
tr.F.
nuc.v.sp.
nuc.d.x.
c.r.
tr.v.sp.
nuc. IX
n.t.r.
teg.
f.s.
nuc.f.s.
nuc. cun.
m.n.o.
p.o.
d.l.n.
nuc. s.V
o.i.
i.a.f
e.a.f.
lem.m.
d.l.m.
lem.m.
tr.sp.t.
S.T. 25

13

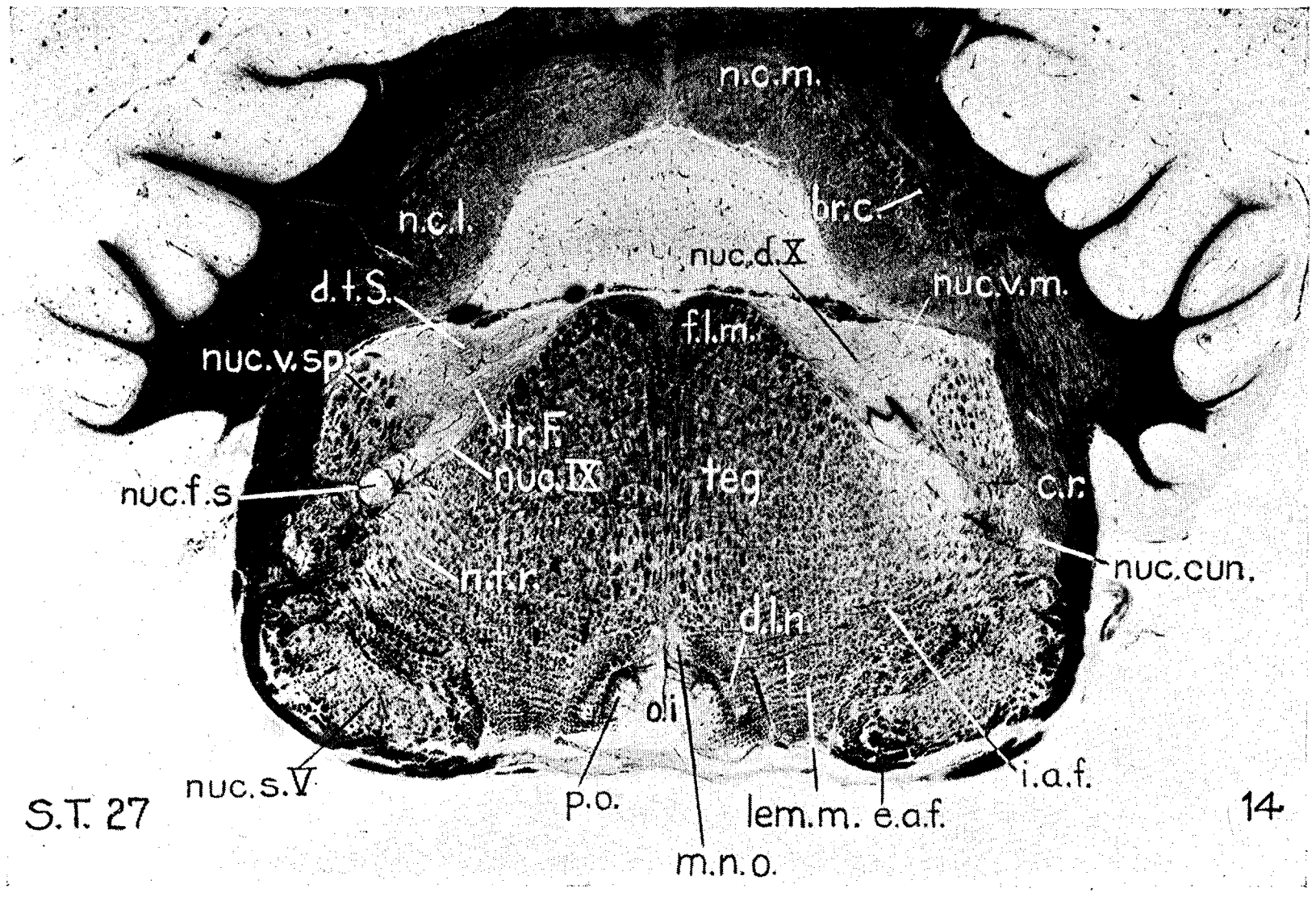
n.c.m.
br.c.
n.c.l.
nuc.d.X
d.t.S.
nuc.v.m.
f.l.m.
nuc.v.sp.
tr.F.
nuc.f.s
nuc.IX
teg.
c.r.
nuc.cun.
n.t.r.
d.l.n.
o.i
i.a.f.
nuc.s.V
p.o.
lem.m.
e.a.f.
m.n.o.
S.T. 27

14

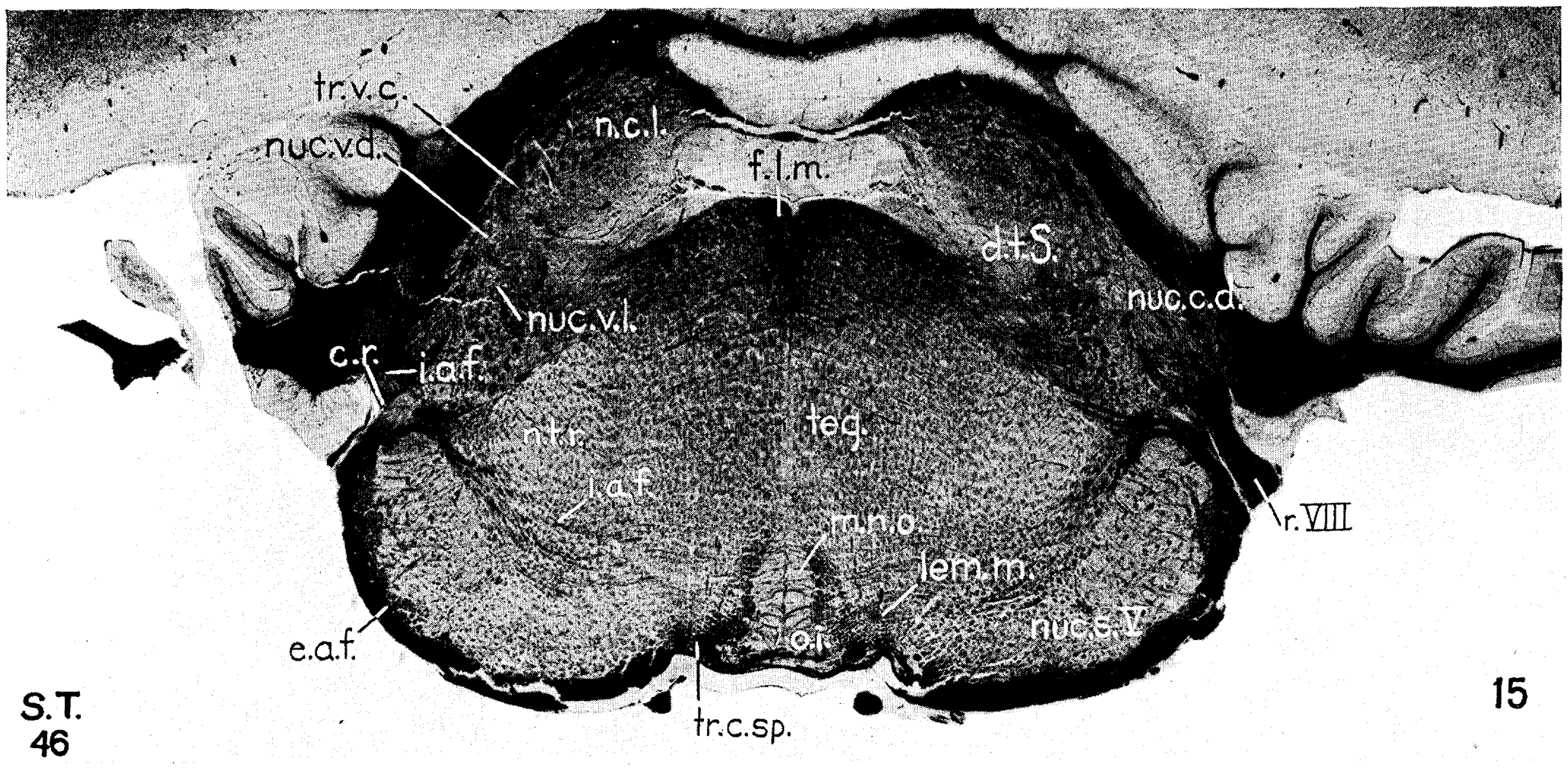
tr.v.c.
nuc.v.d.
n.c.l.
f.l.m.
d.t.S.
nuc.c.d.
nuc.v.l.
c.r.
i.a.f.
n.t.r.
teg.
i.a.f.
r.VIII
m.n.o.
lem.m.
nuc.s.V
o.i.
e.a.f.
tr.c.sp.
S.T.
46

15

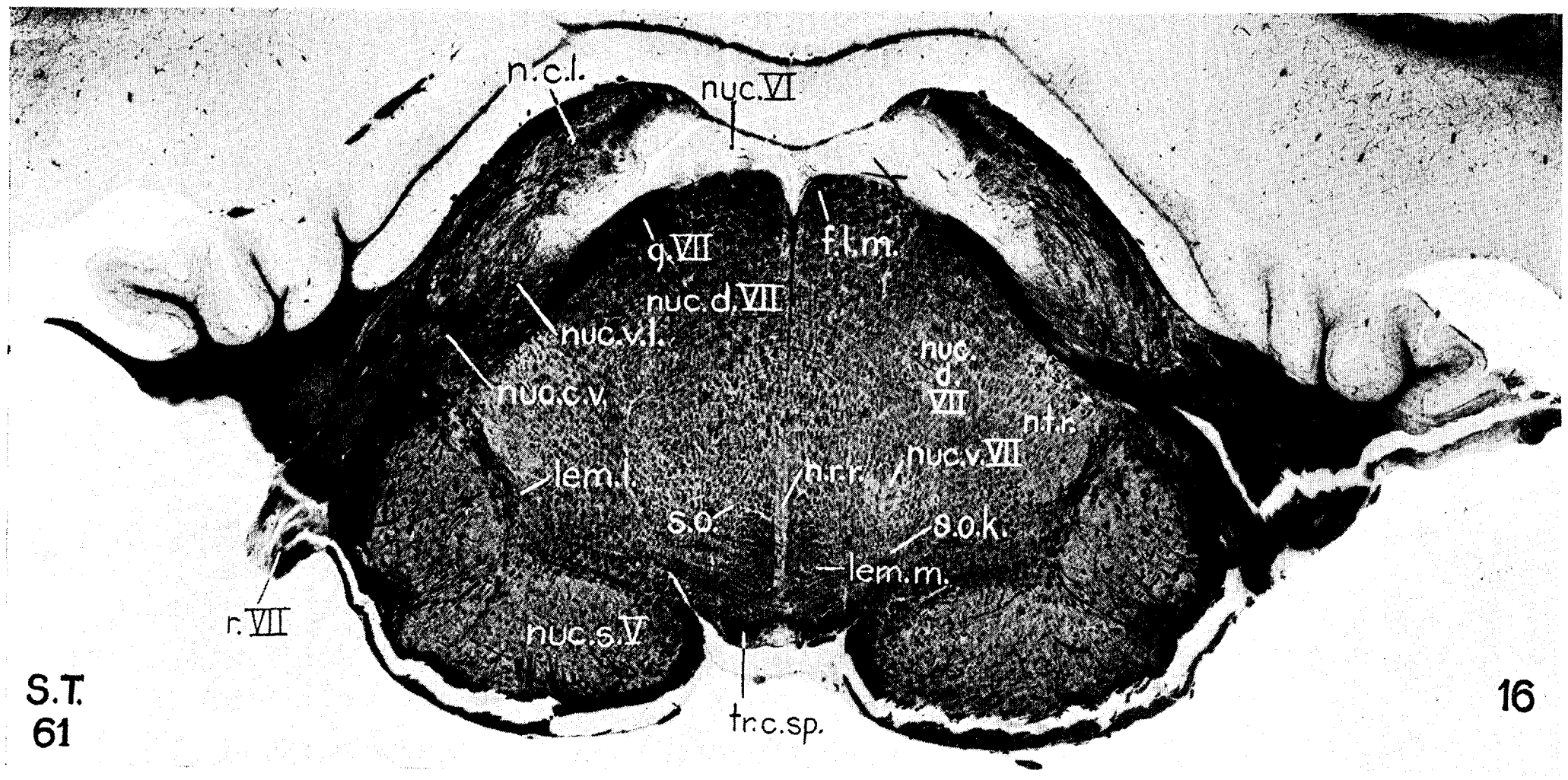
n.c.l.
nuc.VI
g.VII
f.l.m.
nuc.d.VII
nuc.v.l.
nuc.
d.
VII
nuc.c.v.
n.t.r.
h.r.r.
nuc.v.VII
lem.l.
s.o.
s.o.k.
lem.m.
r.VII
nuc.s.V
tr.c.sp.
S.T.
61

16

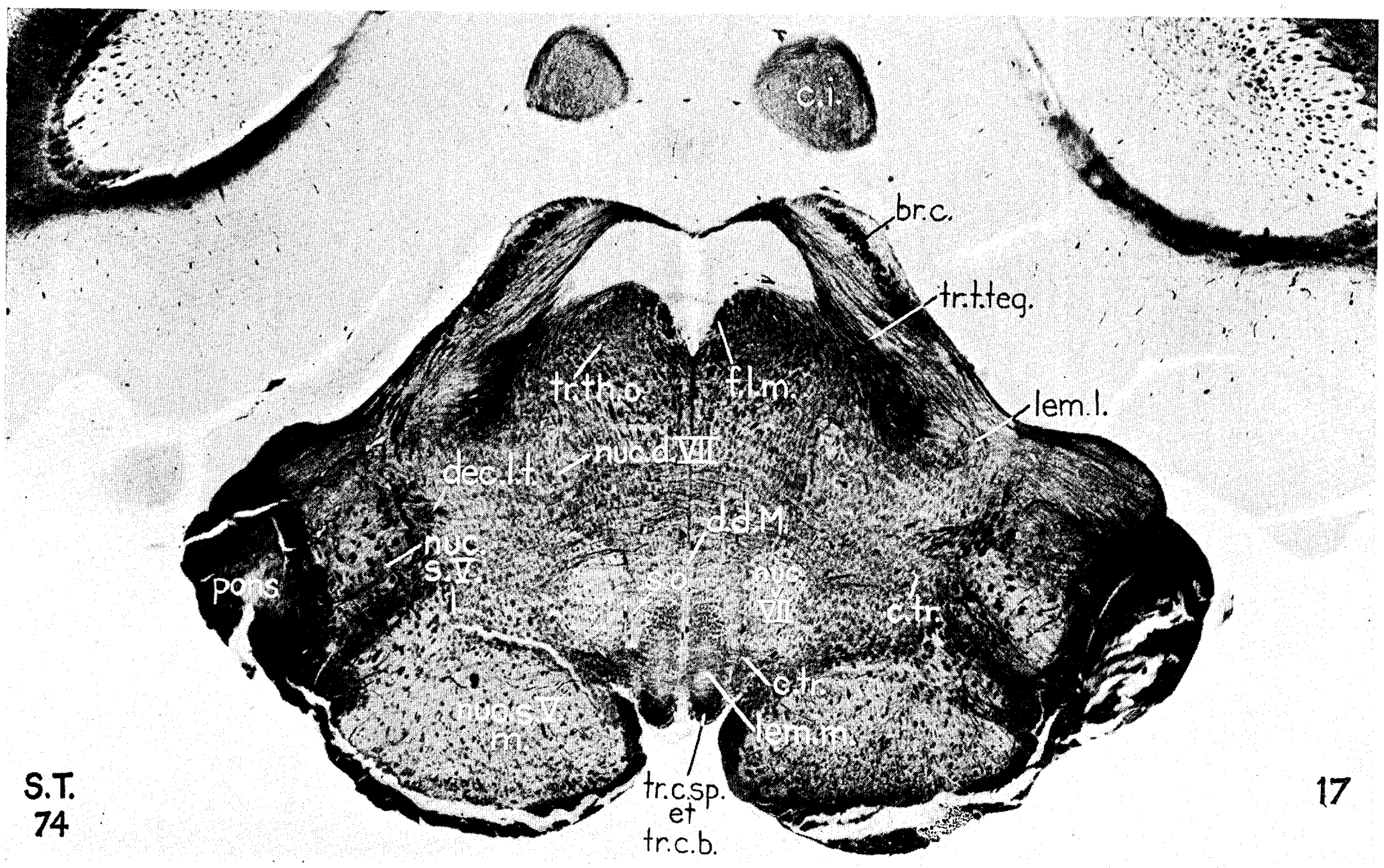
c.i.
br.c.
tr.t.teg.
tr.th.o.
f.l.m.
lem.l.
dec.l.f.
nuc.d.VII
d.d.M.
nuc.
s.V.
pons
s.o.
nuc.
VII
c.tr.
c.tr.
nuc.s.V
m
lem.m.
tr.c.sp.
et
tr.c.b.
S.T.
74

17

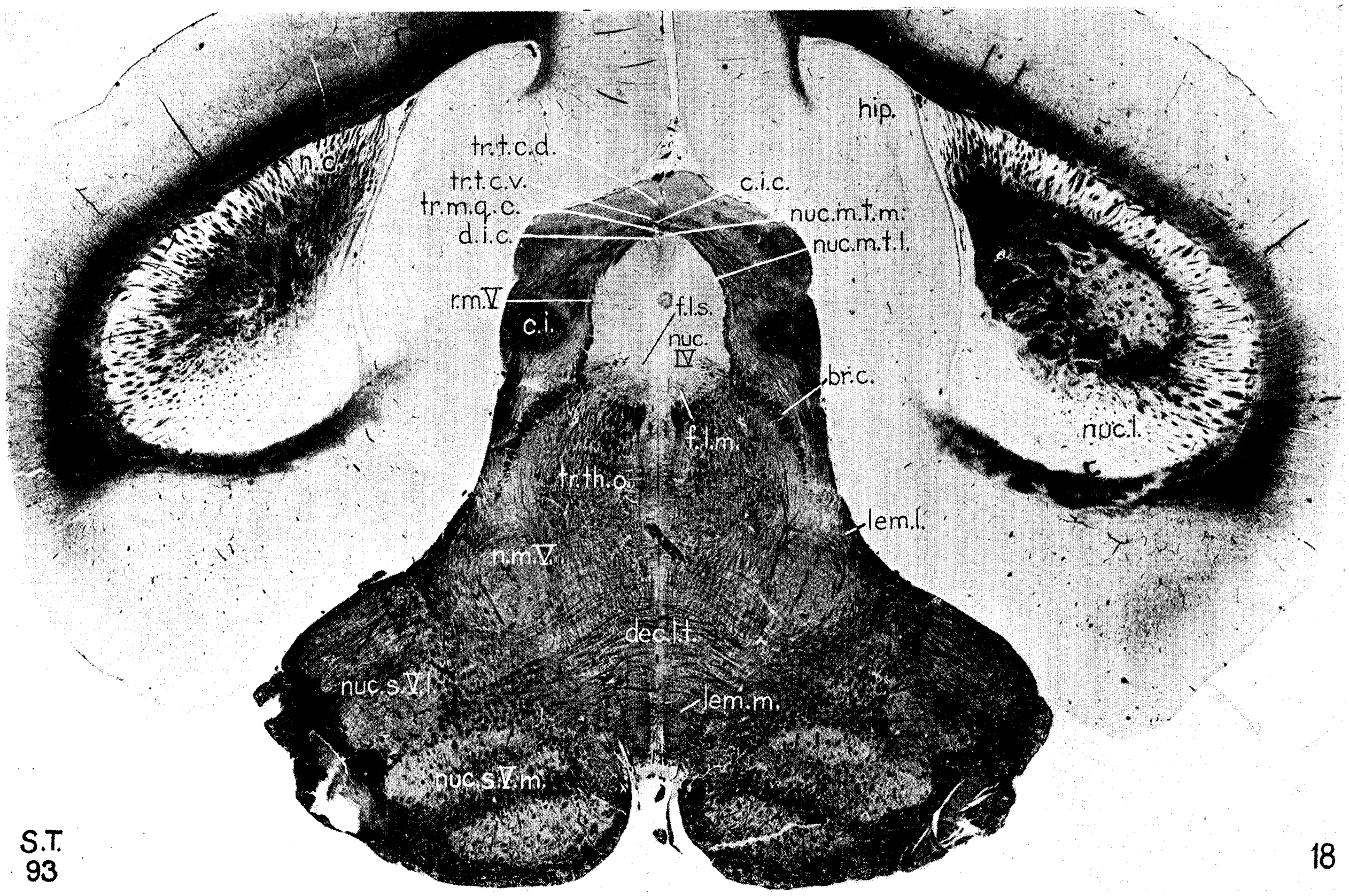
hip.
tr.t.c.d.
tr.t.c.v.
tr.m.q.c.
d.i.c.
c.i.c.
nuc.m.t.m.
nuc.m.t.l.
n.c.
r.m.V
c.i.
f.l.s.
nuc. IV
br.c.
f.l.m.
nuc.l.
tr.th.o.
lem.l.
n.m.V
dec.l.t.
nuc.s.V.l.
lem.m.
nuc.s.V.m.
S.T. 93

18

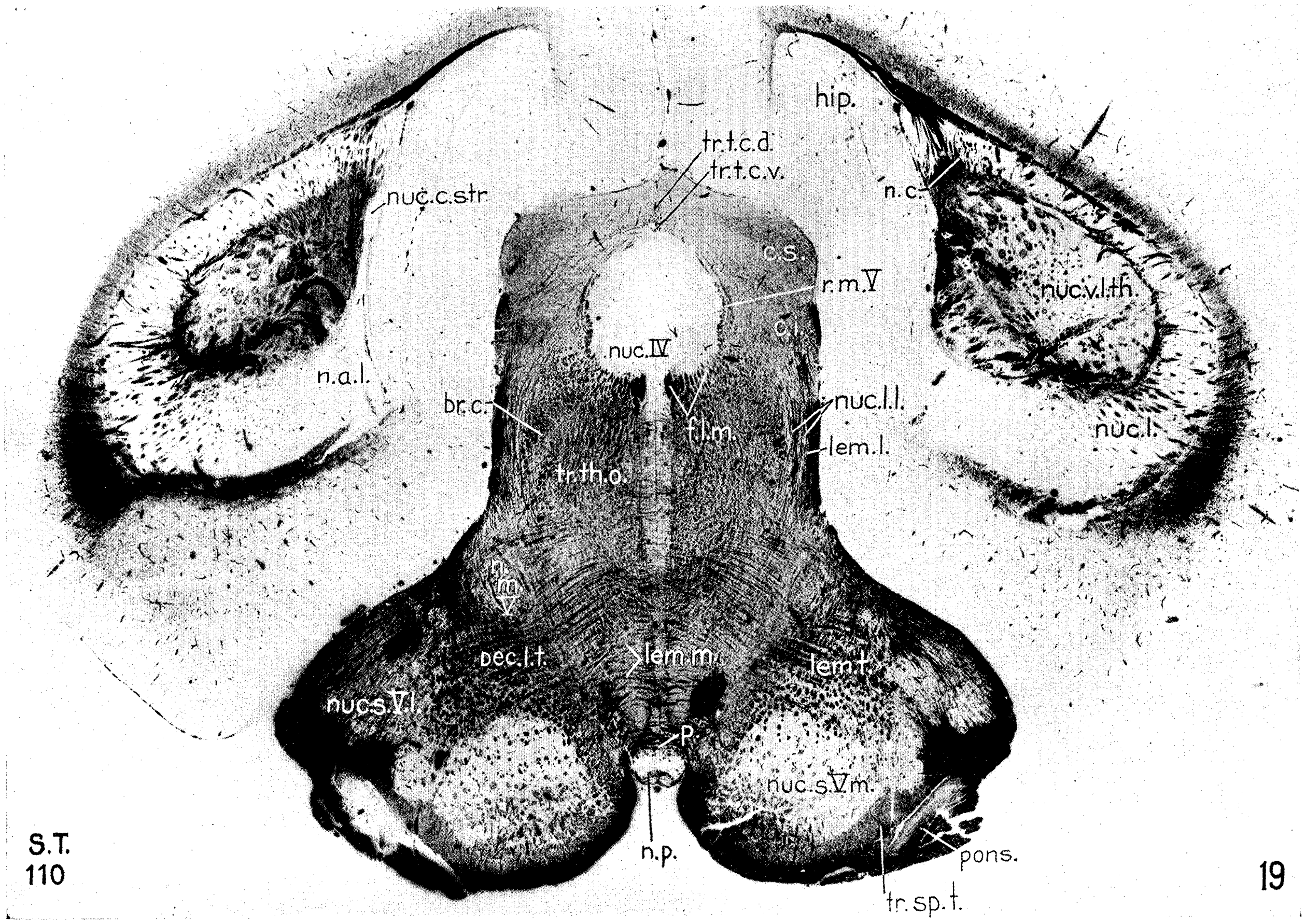
hip.
tr.t.c.d.
tr.t.c.v.
nuc.c.str.
n.c.
c.s.
r.m.V
c.i.
nuc.v.l.th.
nuc.IV
n.a.l.
br.c.
nuc.l.l.
f.l.m.
lem.l.
nuc.l.
tr.th.o.
n.m.V
dec.l.t.
lem.m.
lem.t.
nuc.s.V.l.
P.
nuc.s.V.m.
n.p.
pons.
tr.sp.t.
S.T. 110

19

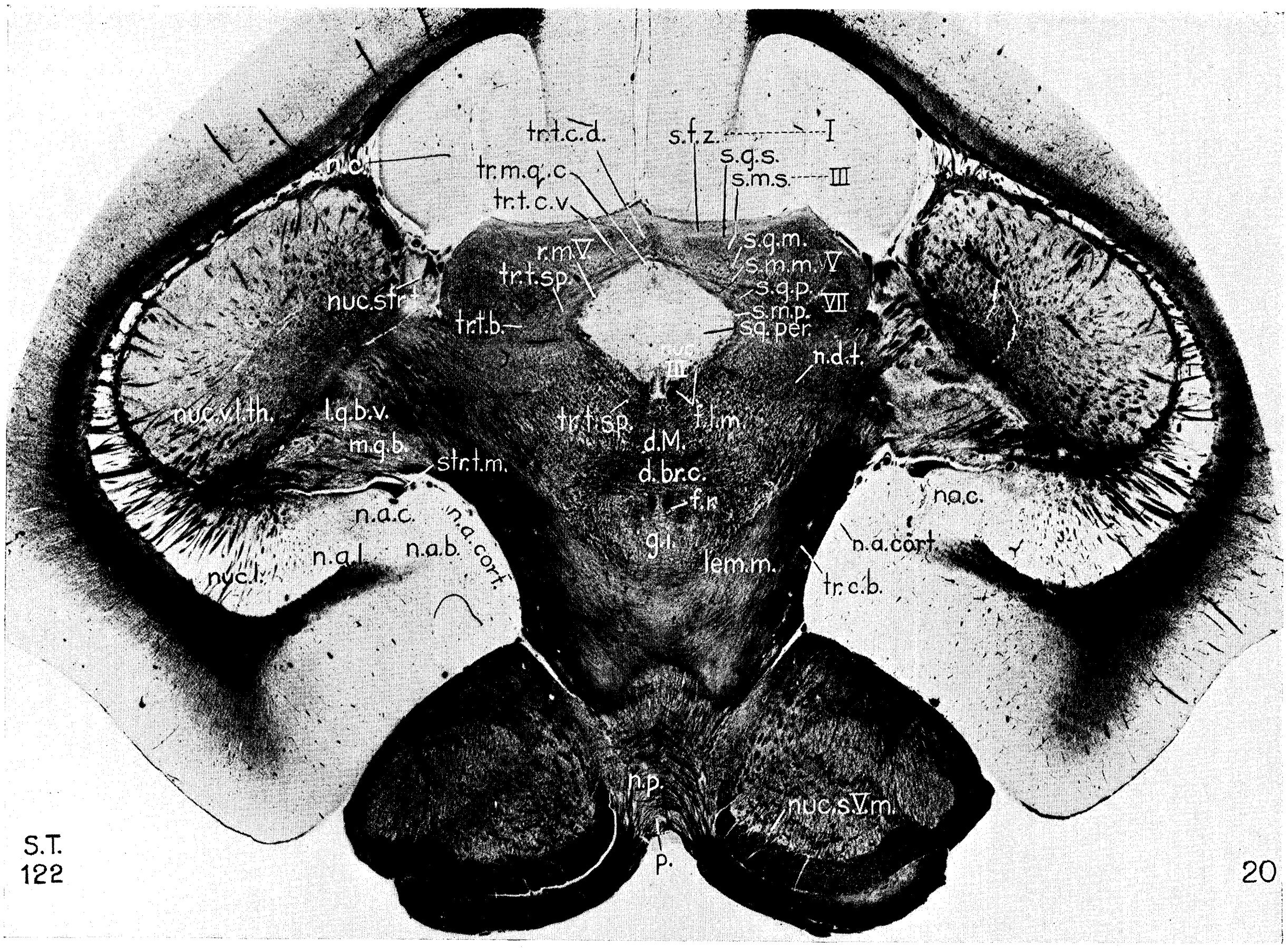
n.c.
tr.t.c.d.
tr.m.q.c.
tr.t.c.v.
s.f.z.
I
s.g.s.
s.m.s.
III
s.g.m.
s.m.m.
V
s.g.p.
VII
s.m.p.
sg.per.
r.m.V
tr.t.sp.
nuc.str.t.
tr.t.b.
nuc.III
n.d.t.
f.l.m.
nuc.v.l.th.
l.g.b.v.
m.g.b.
str.t.m.
tr.t.sp.
d.M.
d.br.c.
f.r.
g.i.
lem.m.
n.a.c.
n.a.cort.
n.a.l.
n.a.b.
nuc.l.
n.a.c.
n.a.cort.
tr.c.b.
n.p.
nuc.s.V.m.
p.
S.T.
122

20

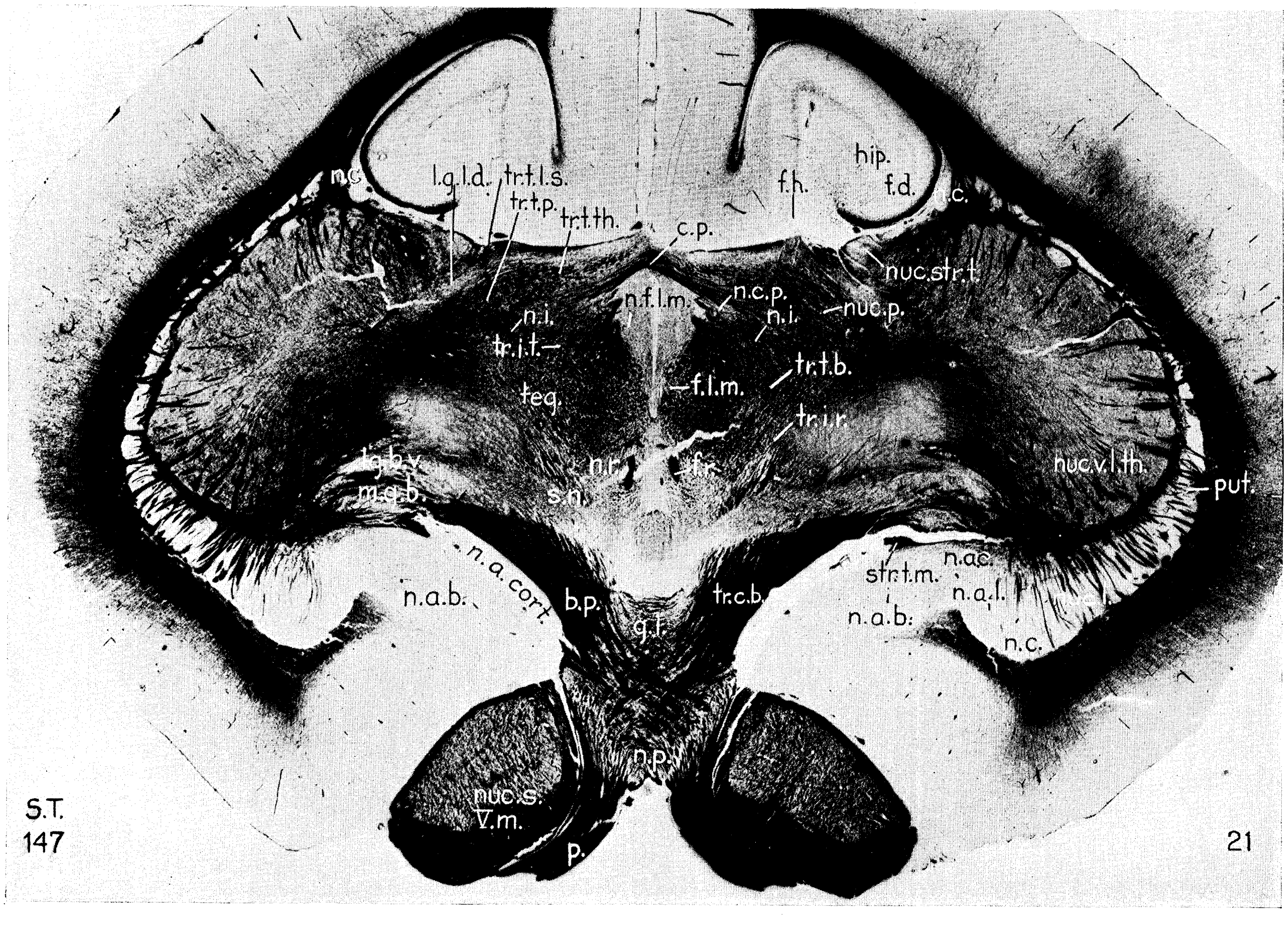
n.c.
l.g.l.d.
tr.t.l.s.
tr.t.p.
tr.t.th.
c.p.
f.h.
hip.
f.d.
n.c.
nuc.str.t.
n.f.l.m.
n.c.p.
n.i.
n.i.
nuc.p.
tr.i.t.
teg.
f.l.m.
tr.t.b.
tr.i.r.
n.r.
f.r.
s.n.
l.g.b.v.
m.g.b.
nuc.v.l.th.
put.
n.a.cort.
n.ac.
str.t.m.
n.a.l.
n.a.b.
n.a.b.
b.p.
tr.c.b.
g.i.
n.c.
n.p.
nuc.s.V.m.
p.
S.T.
147

21

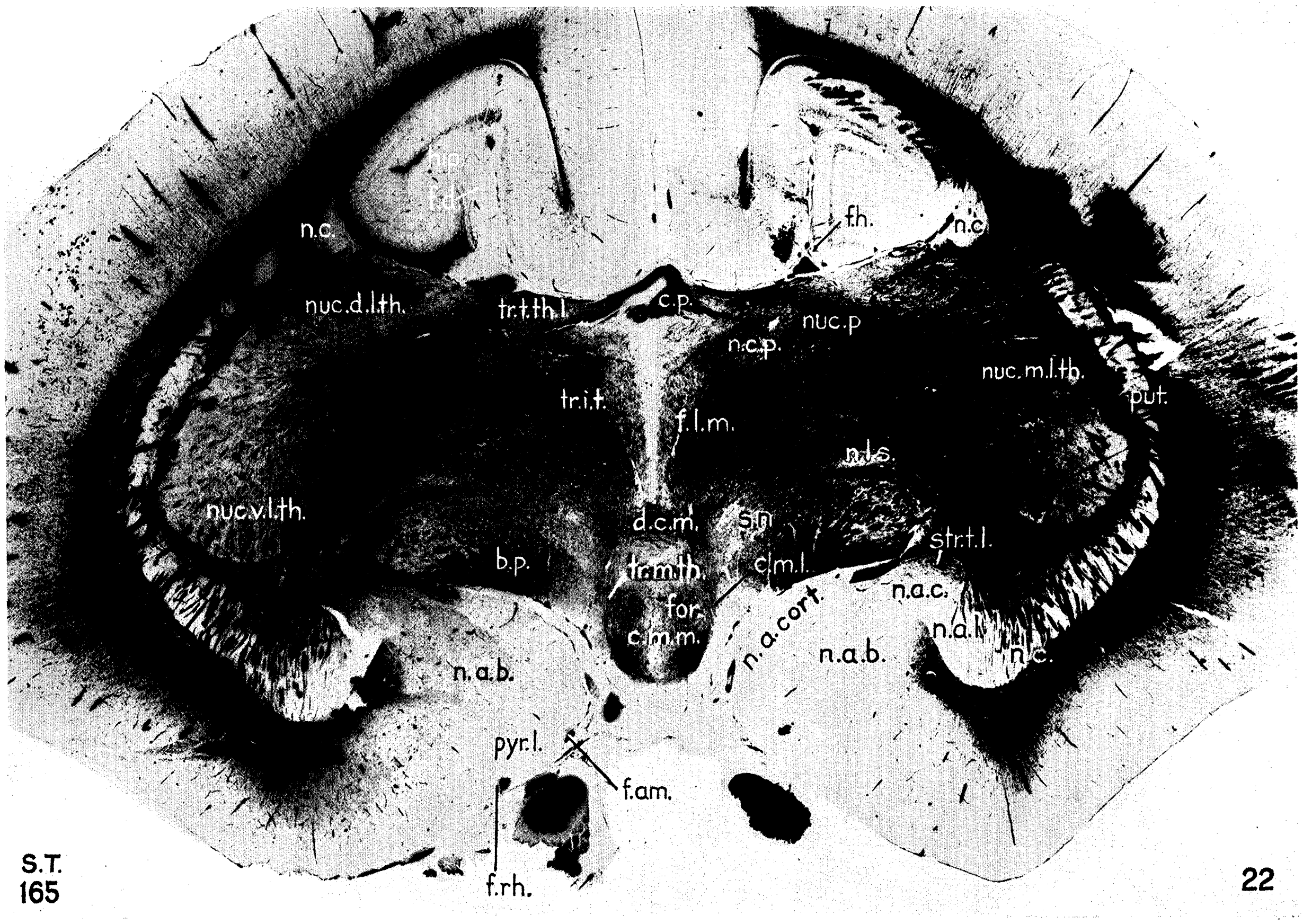

S.T. 165

22

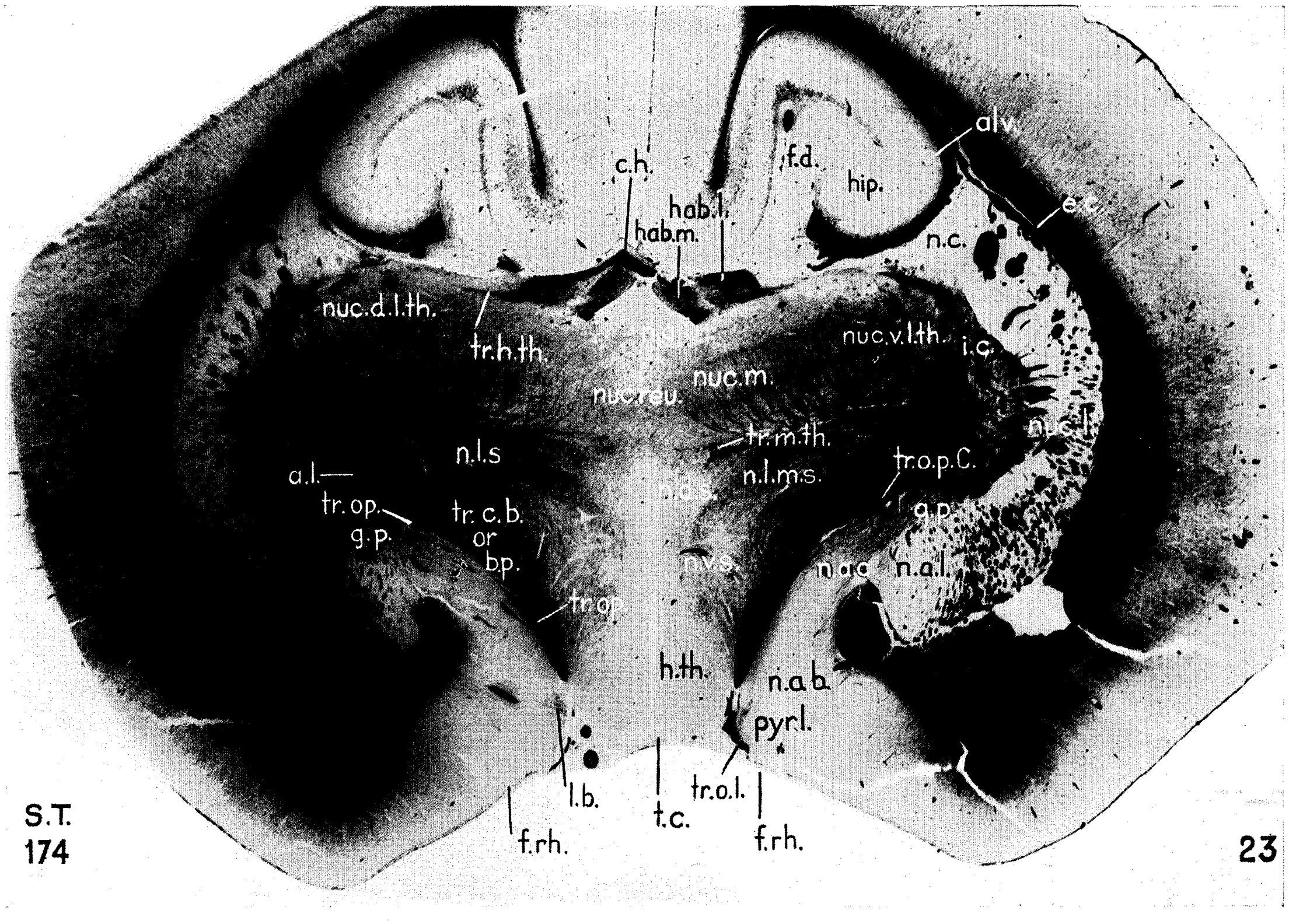

S.T. 174

23

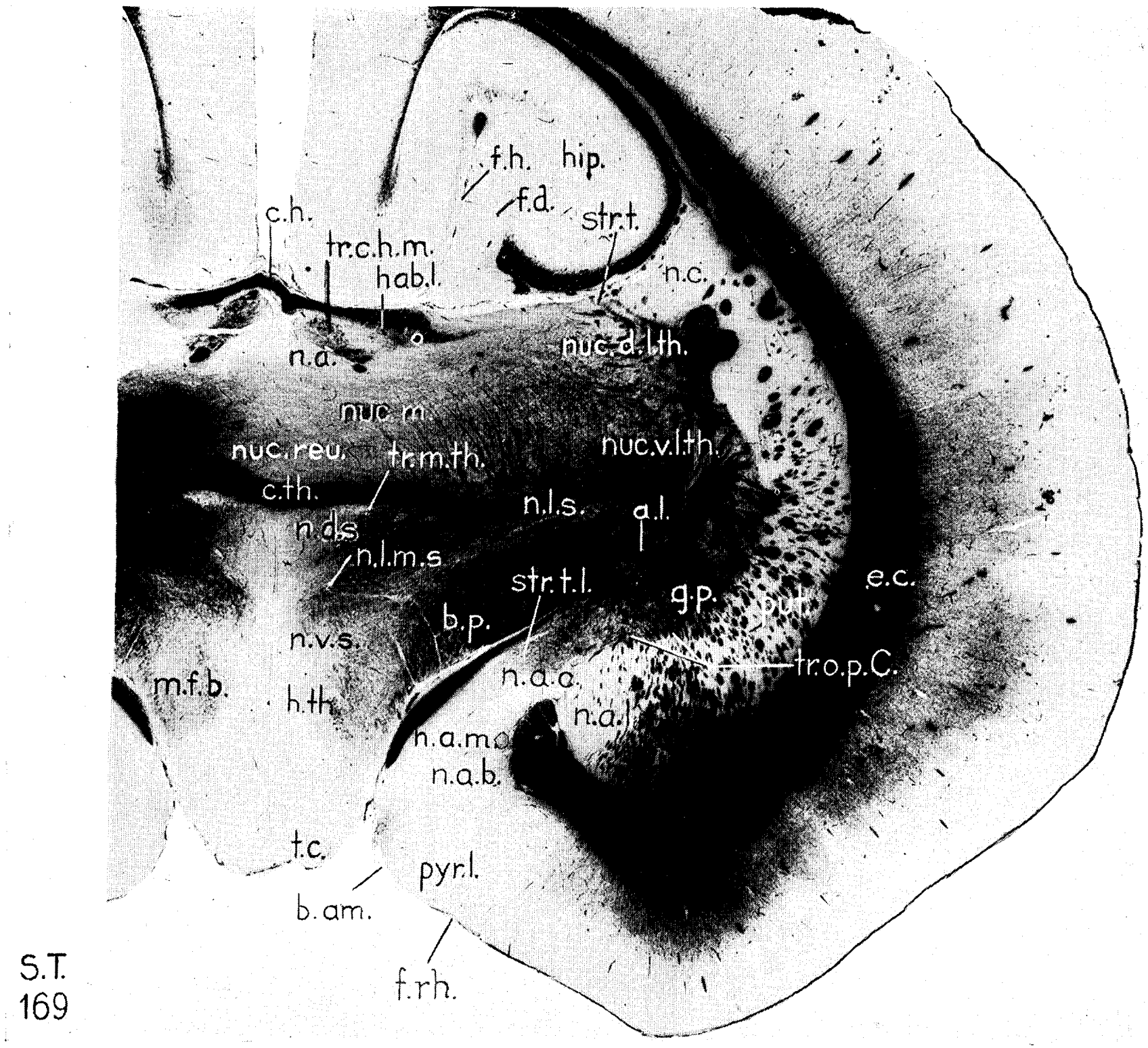
f.h.
hip.
f.d.
str.t.
c.h.
tr.c.h.m.
hab.l.
n.c.
n.a.
nuc.d.l.th.
nuc.m.
nuc.reu.
tr.m.th.
nuc.v.l.th.
c.th.
n.l.s.
a.l.
n.d.s.
n.l.m.s.
str.t.l.
g.p.
put.
e.c.
b.p.
n.v.s.
tr.o.p.C.
m.f.b.
n.a.c.
h.th.
n.a.l.
n.a.m.
n.a.b.
t.c.
pyr.l.
b.am.
f.rh.
S.T.
169

24


hip.
f.d.
str.m.th.
str.t.
n.c.
n.b.str.t.
n.c.
n.a.
nuc.m.
tr.th.str.
e.c.
i.c.
put.
e.c.
str.t.
nuc.reu.
put.
g.p.
tr.c.h.l.
tr.m.th.
g.p.
for.
tr.th.h.
n.a.l.
str.m.(preop)
n.c.
n.a.s.
m.f.b.
n.t.o.l.
pyr.l.
c.o.
tr.o.l.
f.e.rh.
f.rh.
S.T.
197

25

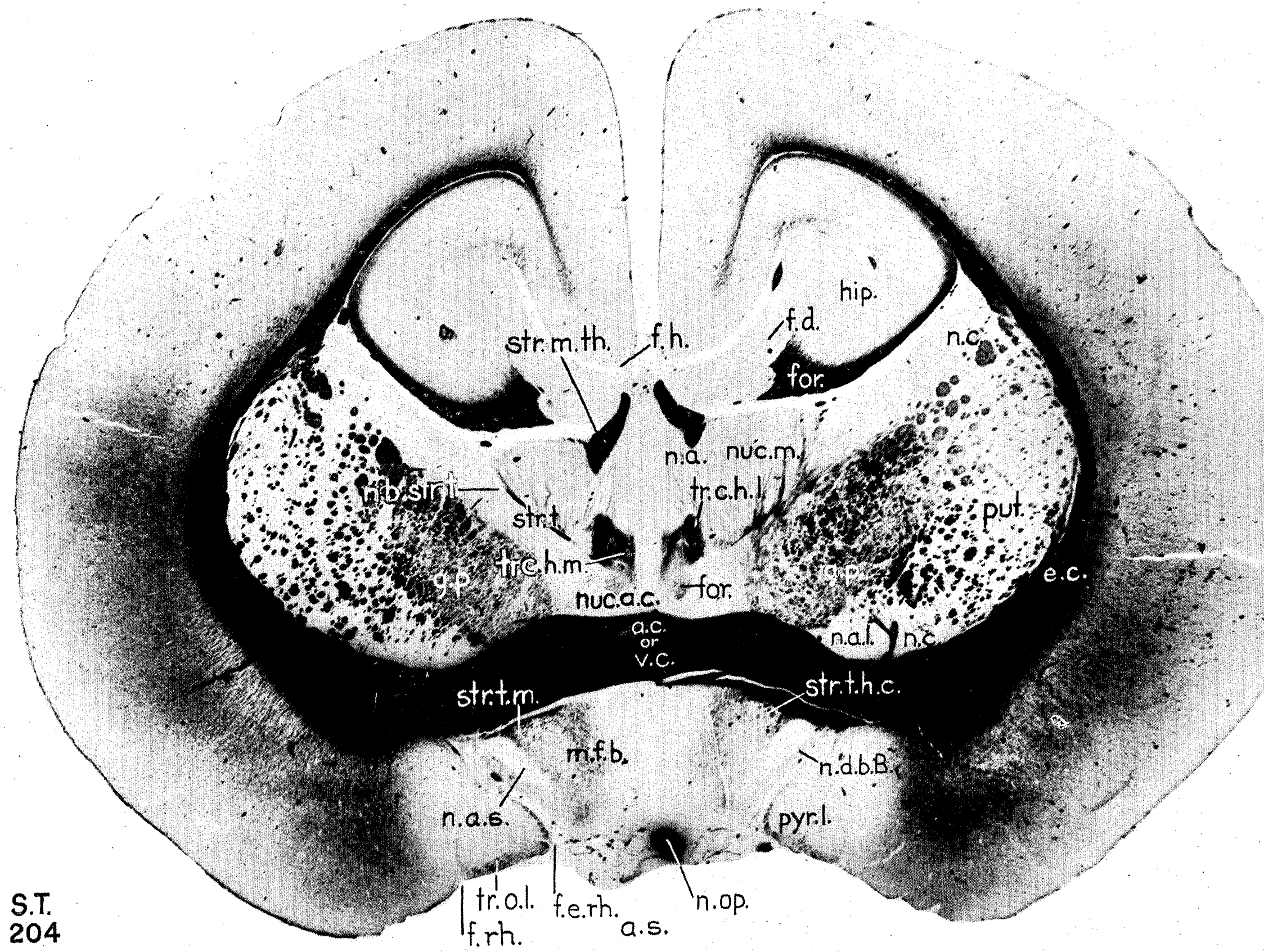
hip.
f.d.
str.m.th.
f.h.
n.c.
for.
n.a.
nuc.m.
n.b.str.t.
str.t.
tr.c.h.l.
put.
tr.c.h.m.
g.p.
g.p.
e.c.
nuc.a.c.
for.
a.c. or v.c.
n.a.l.
n.c.
str.t.m.
str.t.h.c.
m.f.b.
n.d.b.B.
n.a.s.
pyr.l.
tr.o.l.
f.e.rh.
n.op.
f.rh.
a.s.
S.T. 204

26

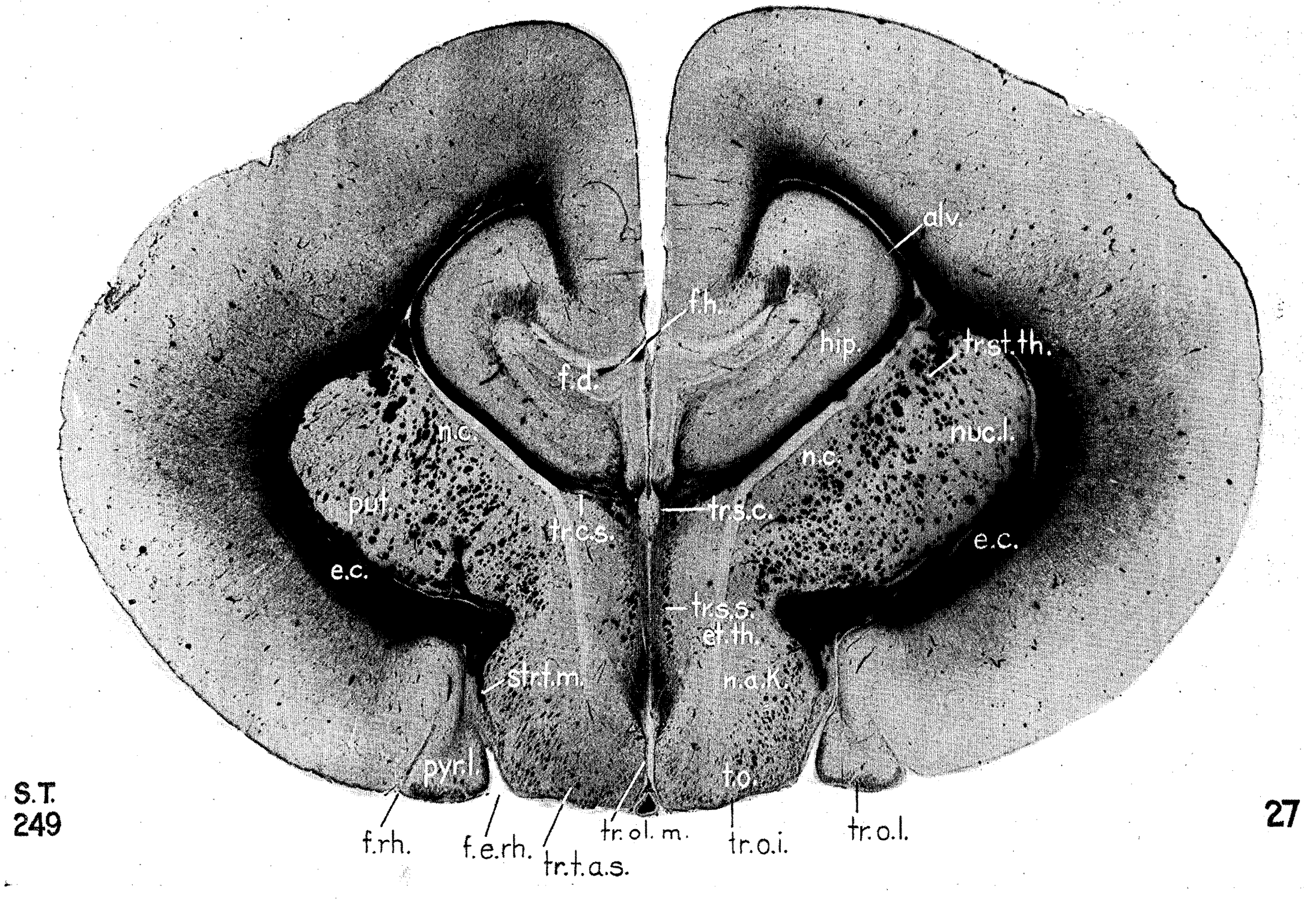
alv.
f.h.
hip.
tr.st.th.
f.d.
n.c.
nuc.l.
n.c.
put.
tr.s.c.
tr.c.s.
e.c.
e.c.
tr.s.s. et th.
str.t.m.
n.a.K.
pyr.l.
t.o.
f.rh.
f.e.rh.
tr.t.a.s.
tr.ol.m.
tr.o.i.
tr.o.l.
S.T. 249

27

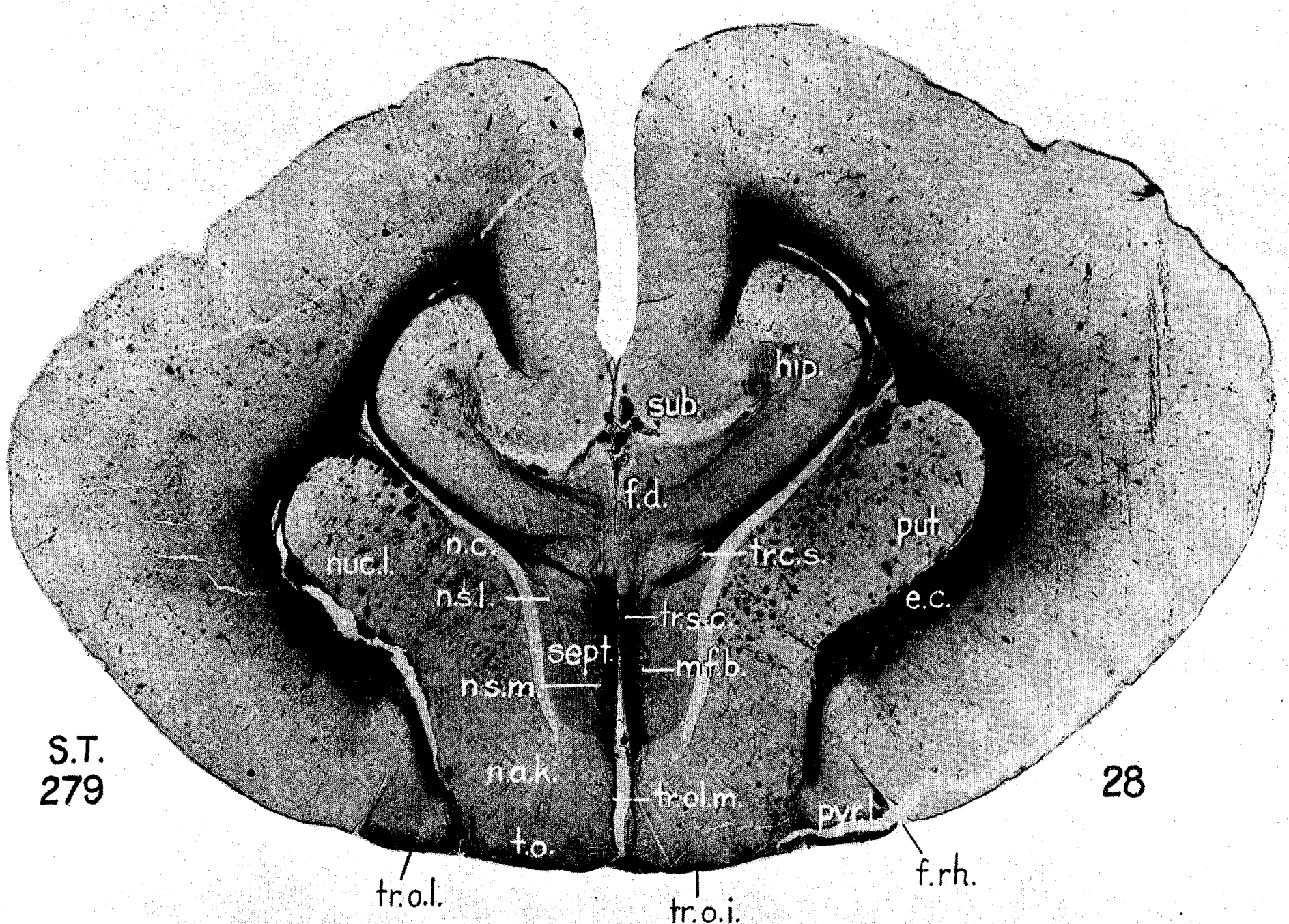
S.T.
279
hip.
sub.
f.d.
put.
n.c.
nuc.l.
tr.c.s.
n.s.l.
e.c.
tr.s.c.
sept.
m.f.b.
n.s.m.
n.a.k.
tr.ol.m.
pyr.l.
t.o.
tr.o.l.
tr.o.i.
f.rh.

28

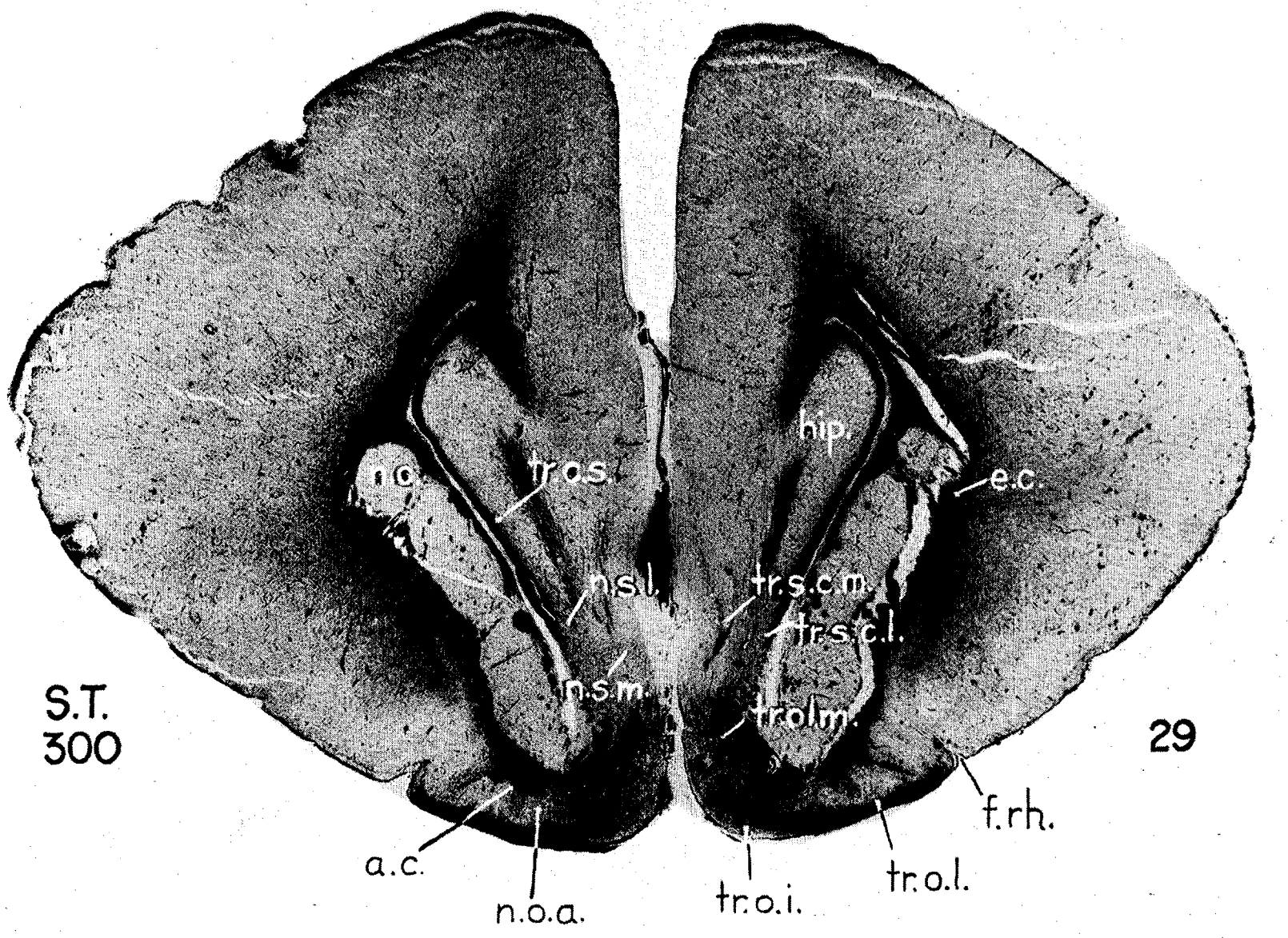
hip.
n.c.
tr.o.s.
e.c.
n.s.l.
tr.s.c.m.
tr.s.c.l.
n.s.m.
S.T.
300
tr.ol.m.
f.rh.
a.c.
tr.o.l.
n.o.a.
tr.o.i.

29

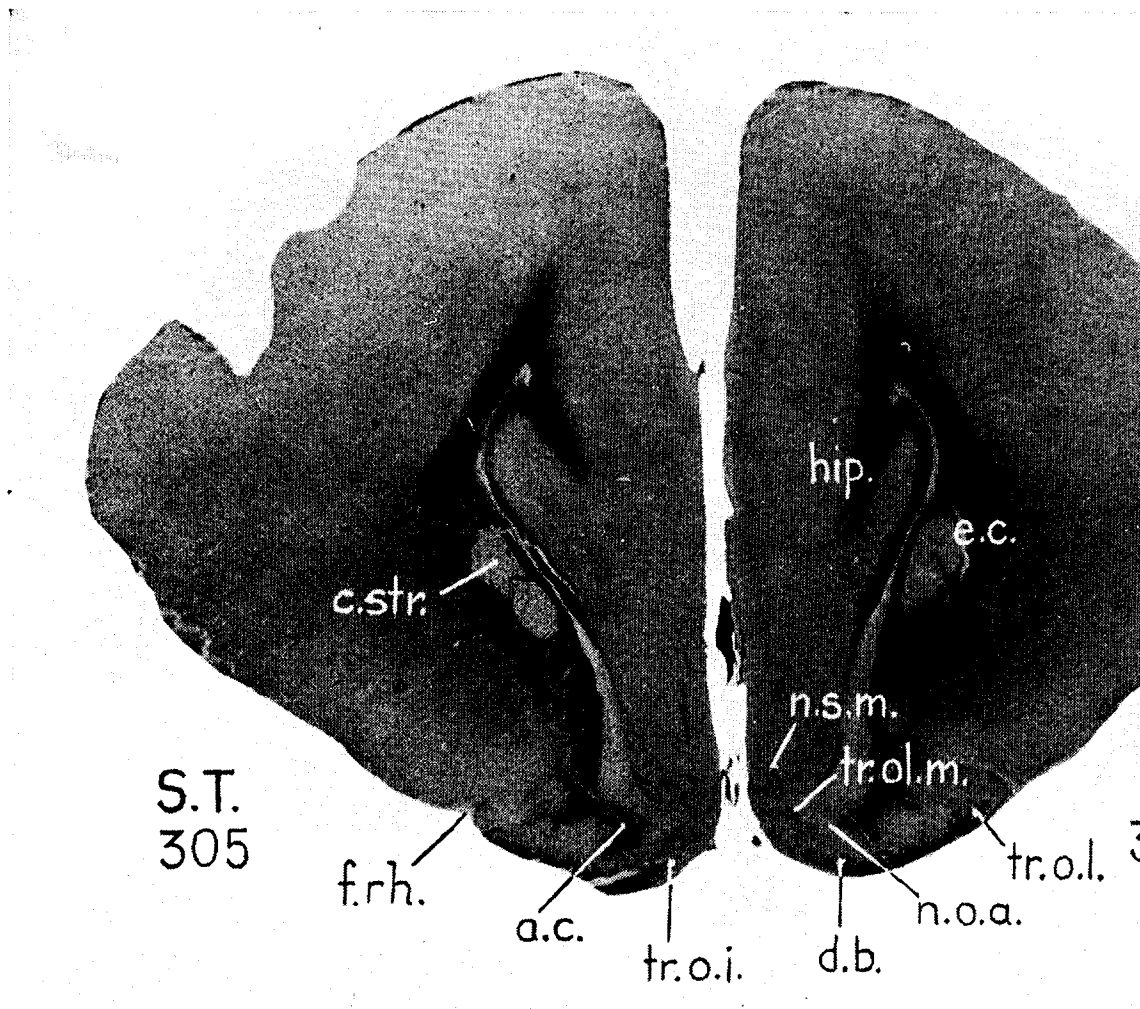
hip.
e.c.
c.str.
n.s.m.
tr.ol.m.
S.T.
305
f.rh.
a.c.
tr.o.i.
d.b.
n.o.a.
tr.o.l.

30

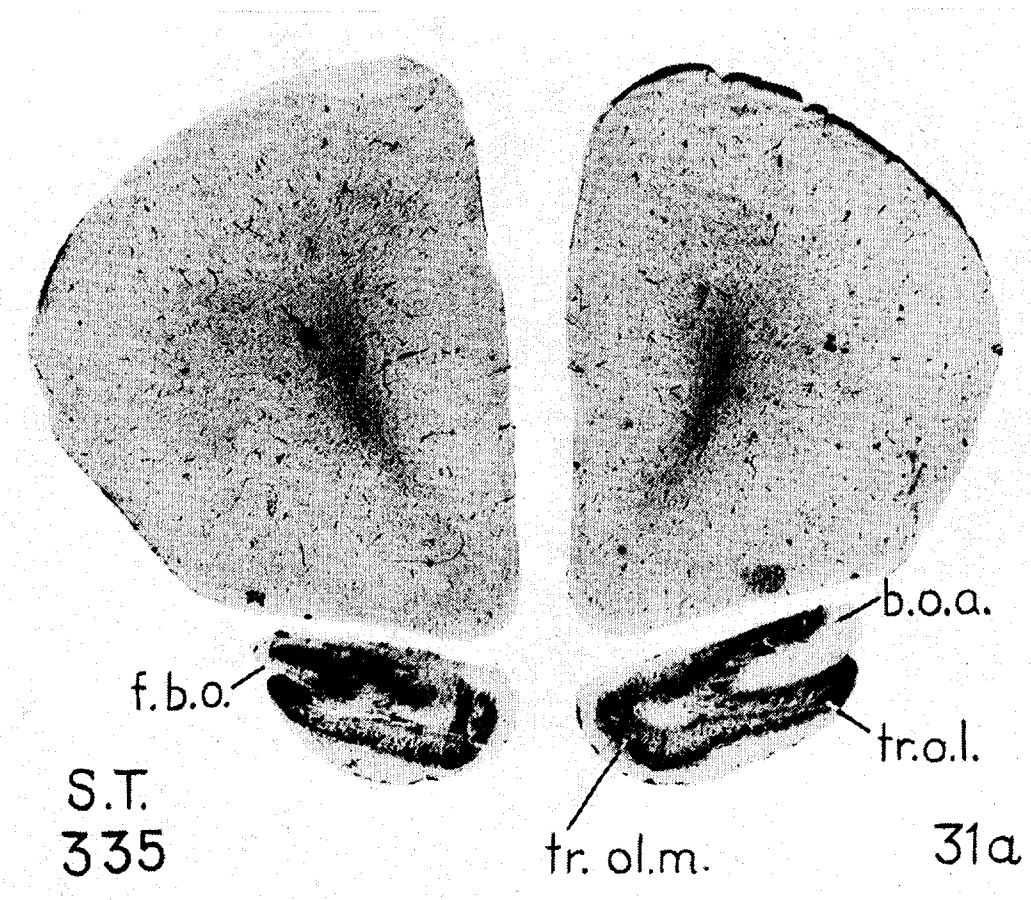
b.o.a.
f.b.o.
tr.o.l.
S.T.
335
tr. ol.m.

31a

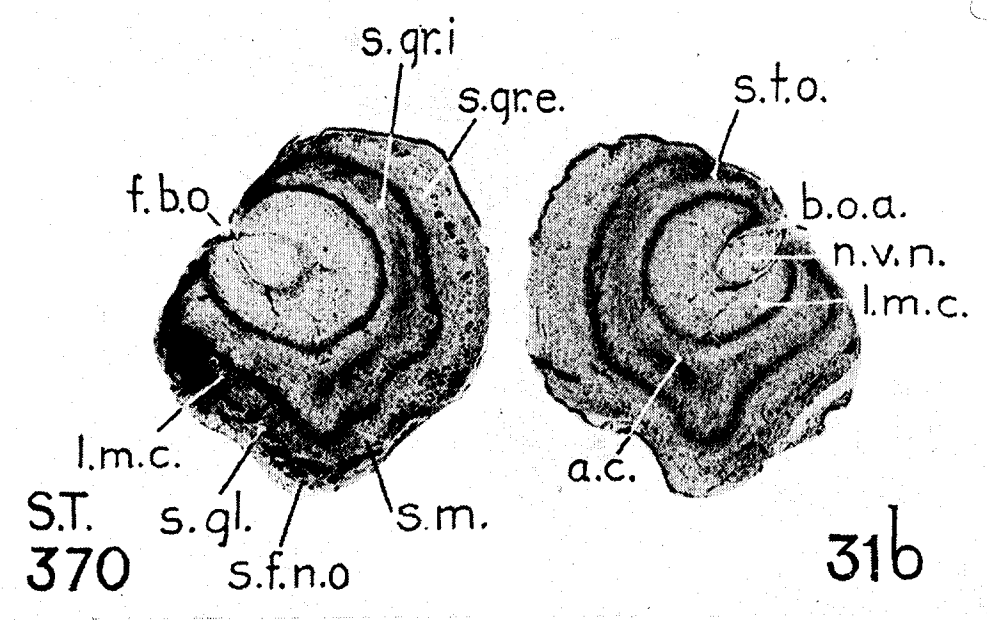
s.gr.i
s.gr.e.
s.t.o.
f.b.o.
b.o.a.
n.v.n.
l.m.c.
l.m.c.
a.c.
S.T.
370
s.gl.
s.m.
s.f.n.o

31b

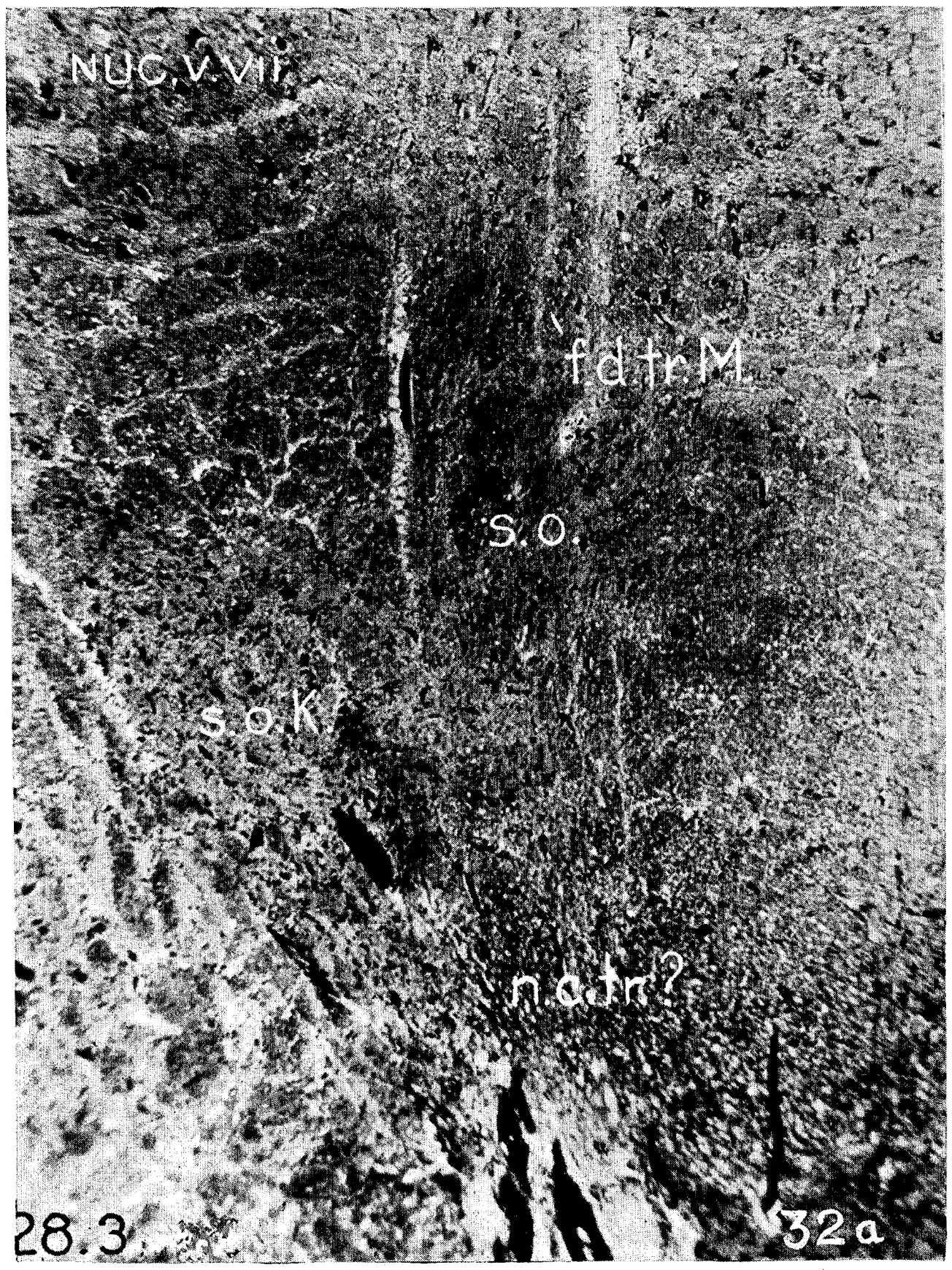
nuc.v.vii
f.d.tr.M.
s.o.
s.o.K
n.c.tr?
28.3
32a

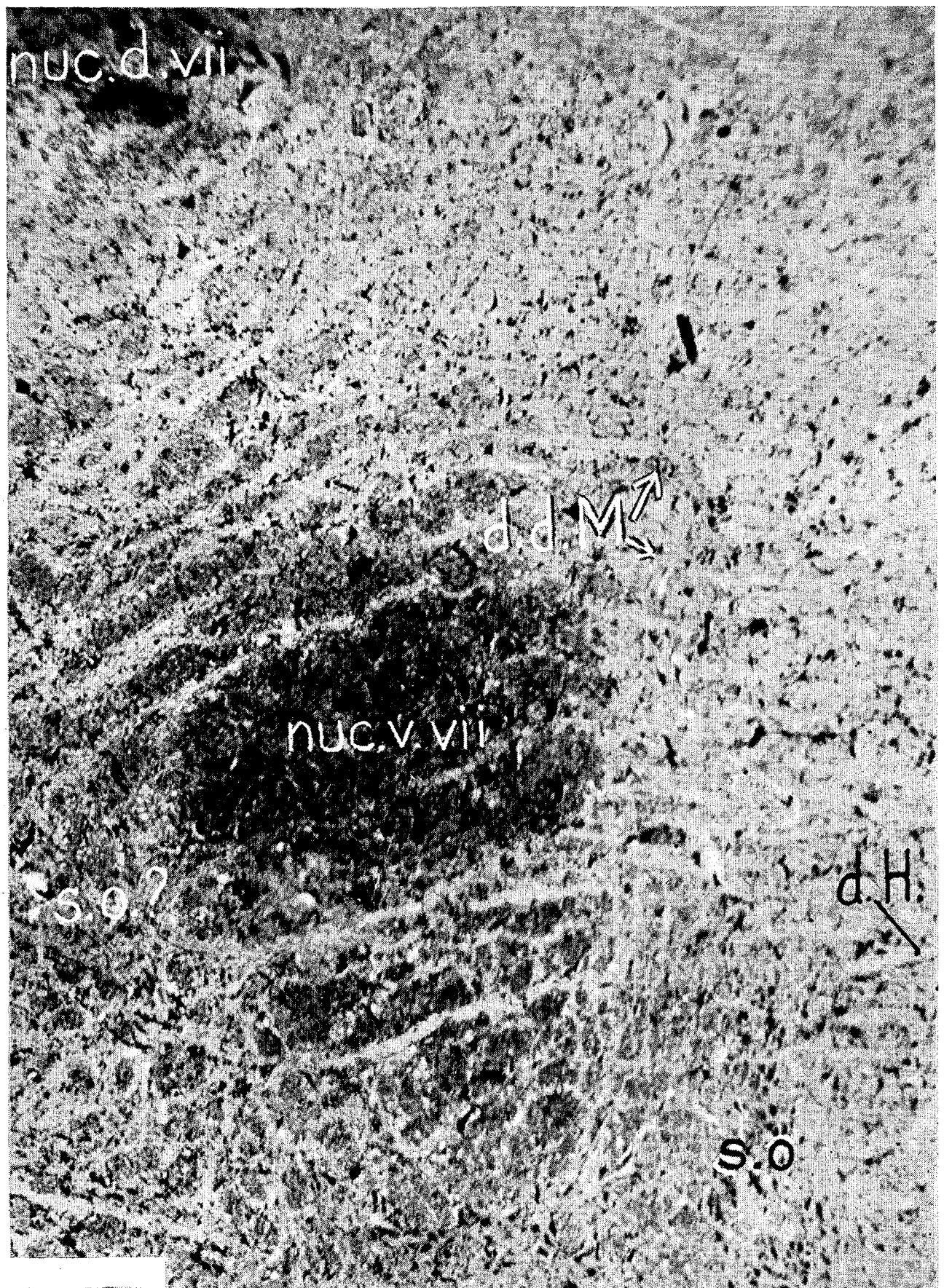
nuc.d.vii
d.d.M.
nuc.v.vii
s.o?
d.H.
s.o
s.o.K
31.3
32b


NUC.V.VII
s.o.
s.o.K
n.c.tr?
c.tr?
32c

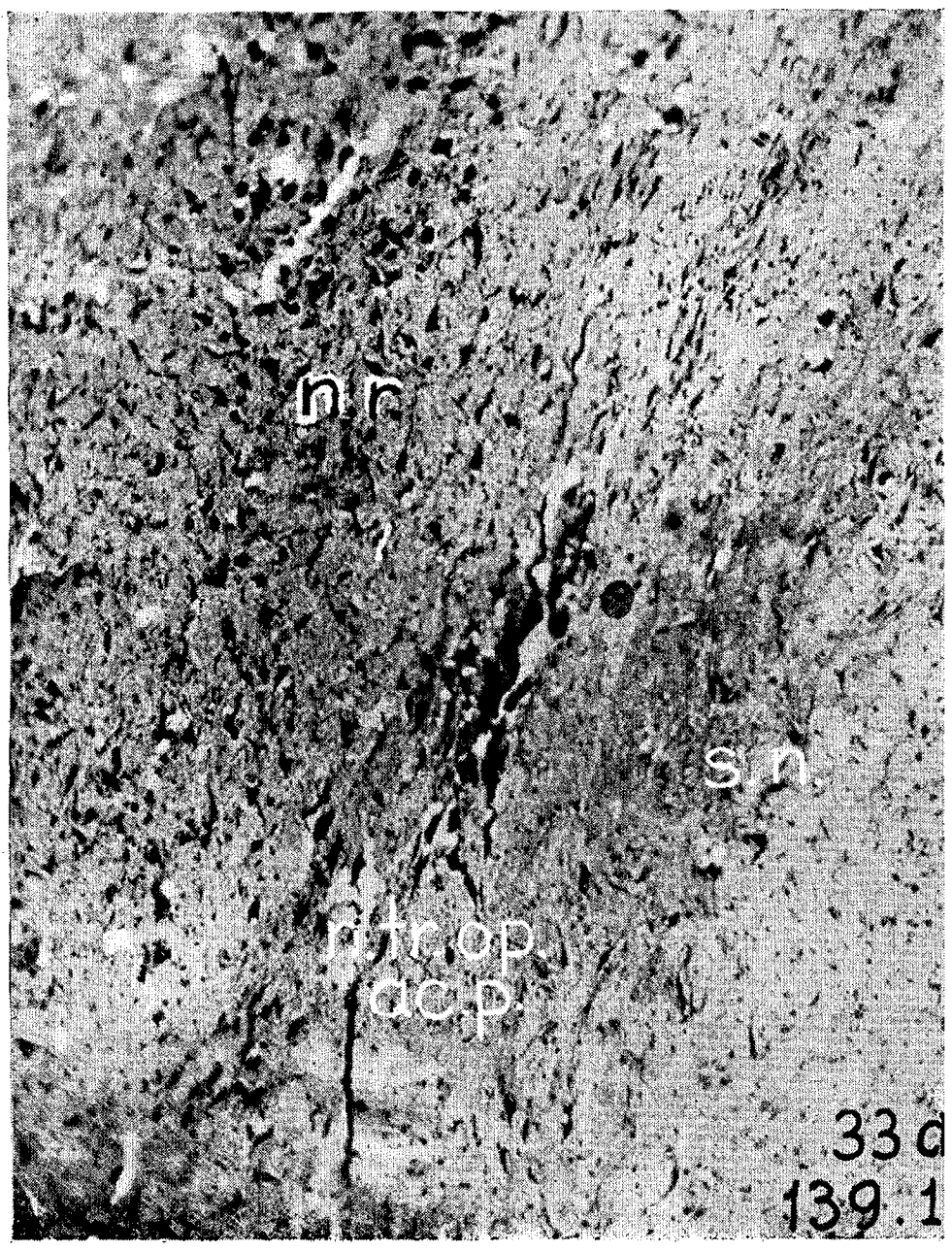
n.r.
s.n.
n.tr.op.
ac.p.
33d
139.1



33 b.

33 d

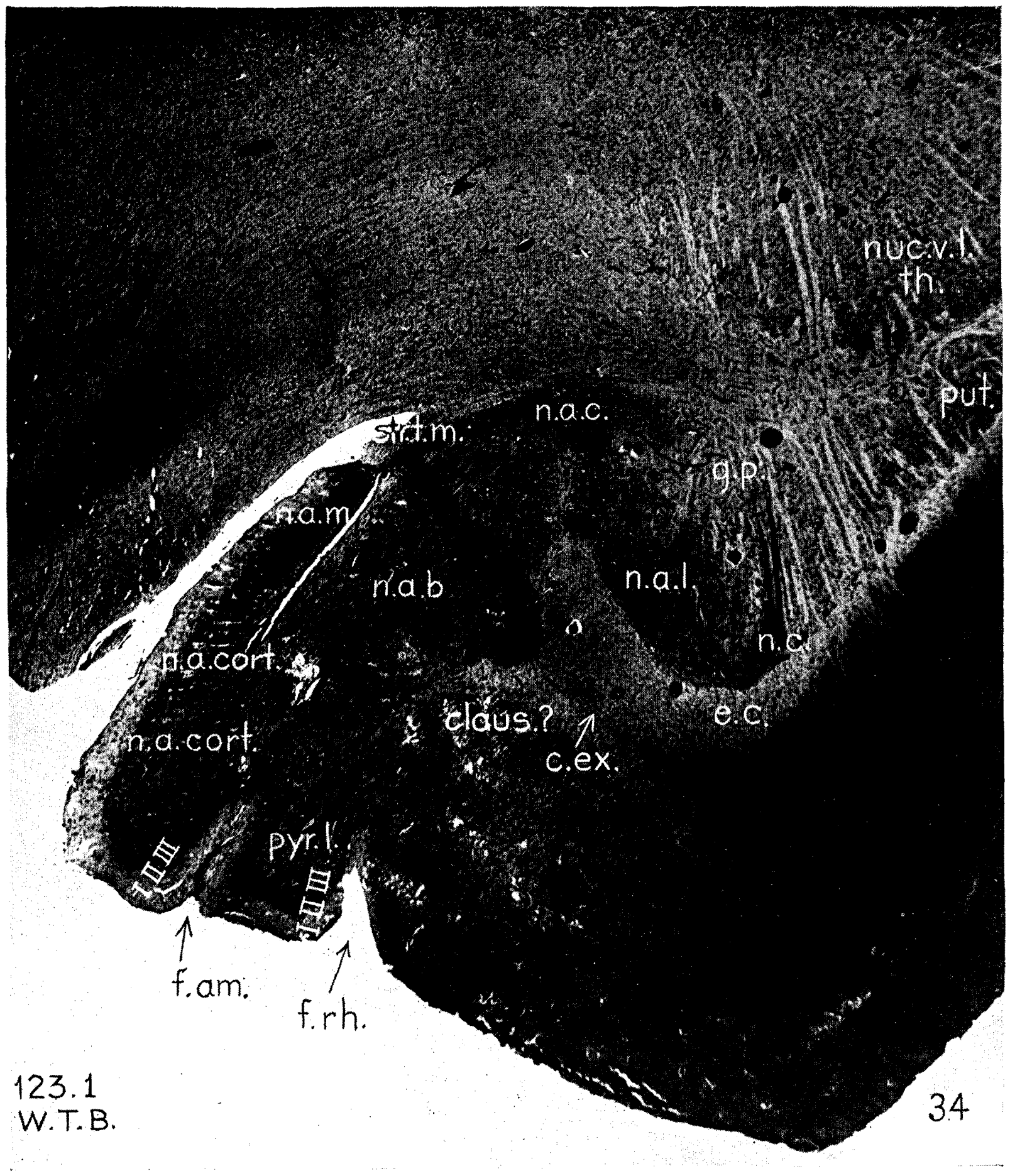

34

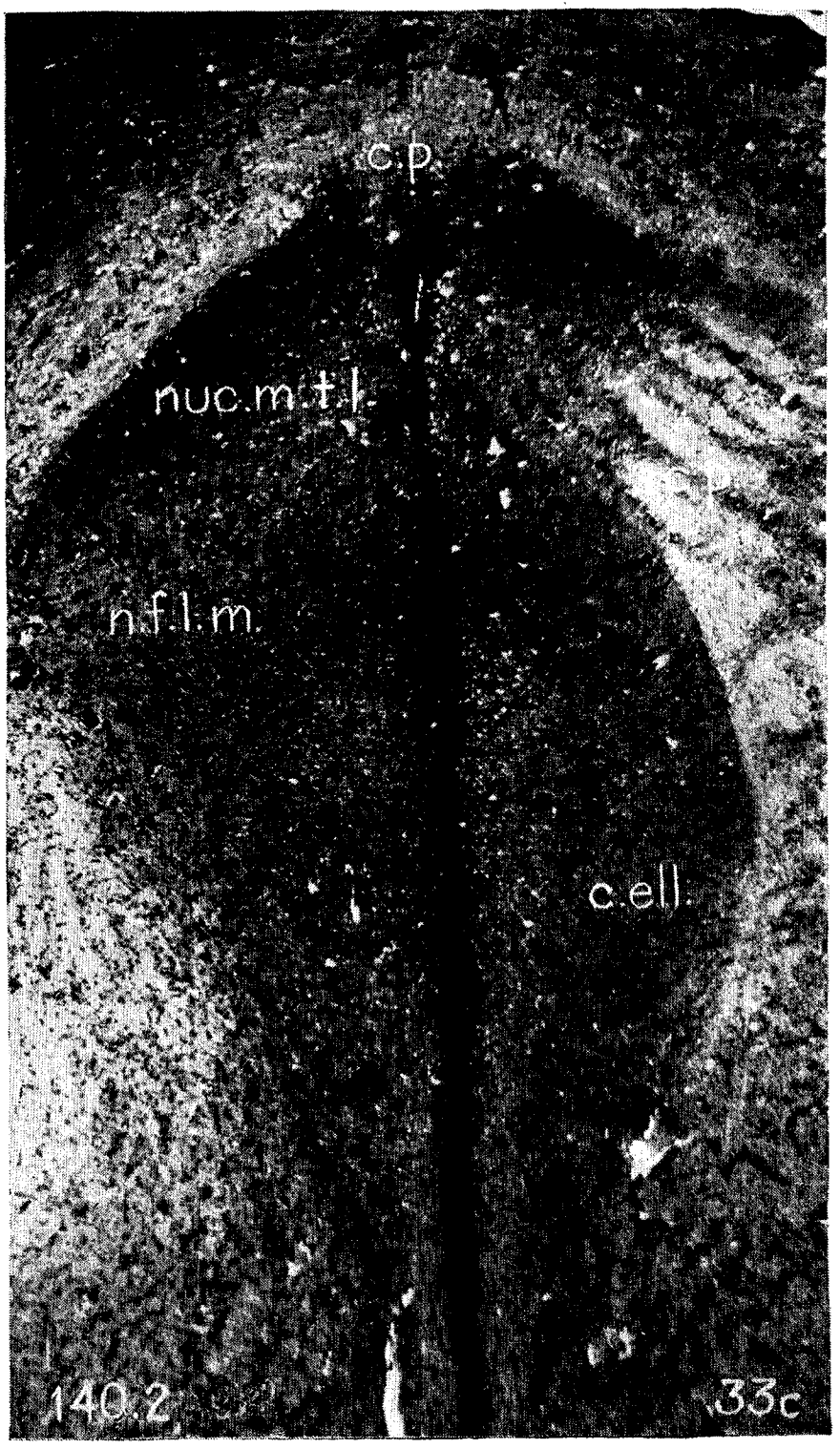

33c

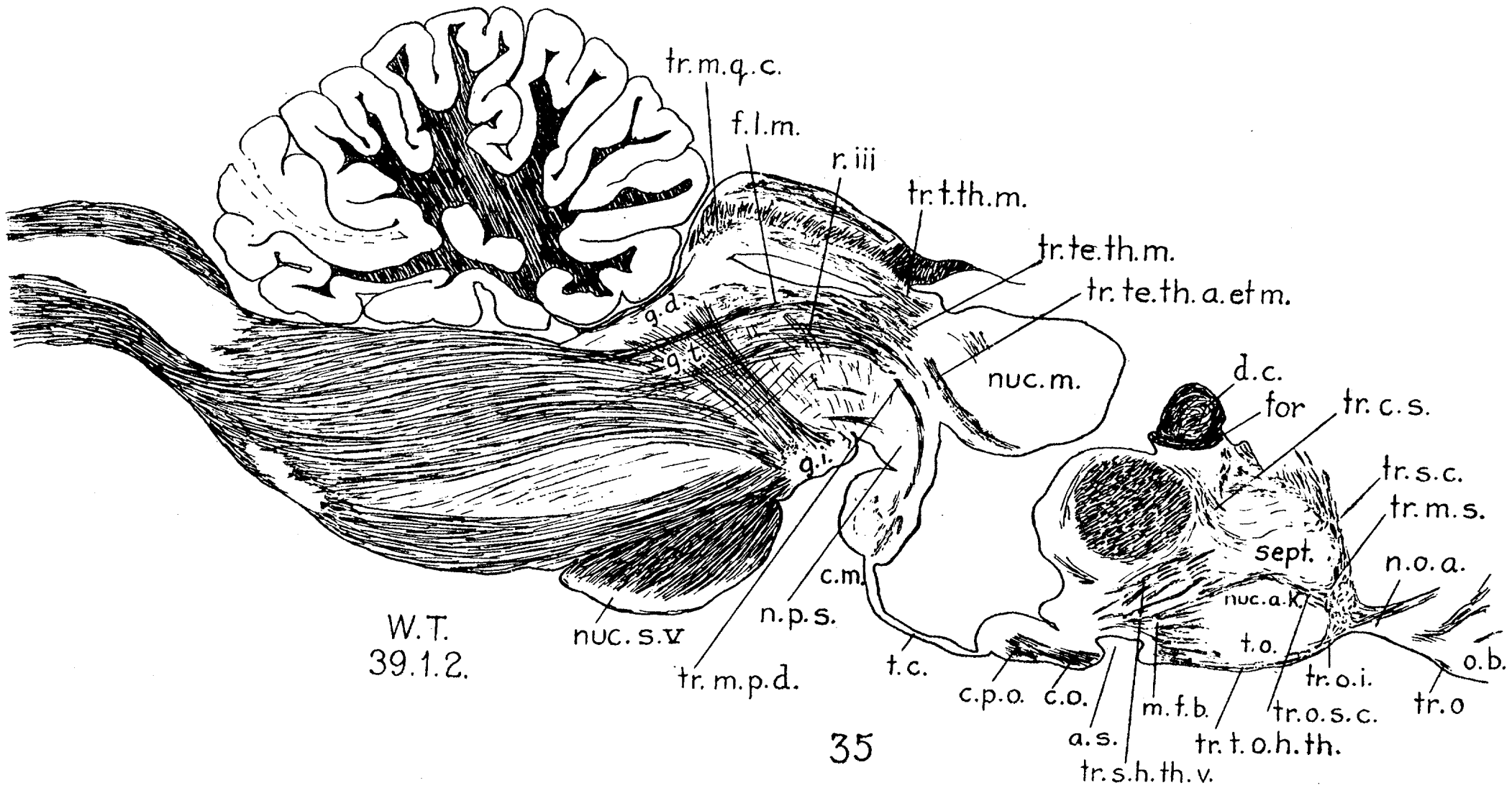
tr. m. q. c.
f. l. m.
r. iii
tr. t. th. m.
tr. te. th. m.
tr. te. th. a. et m.
q. d.
q. t.
nuc. m.
d. c.
for
tr. c. s.
tr. s. c.
tr. m. s.
sept.
n. o. a.
nuc. a. K.
q. i.
c. m.
n. p. s.
W.T.
39.1.2.
nuc. s. V
tr. m. p. d.
t. c.
c. p. o.
c. o.
a. s.
tr. s. h. th. v.
m. f. b.
t. o.
tr. o. i.
tr. o. s. c.
tr. t. o. h. th.
tr. o
o. b.

35

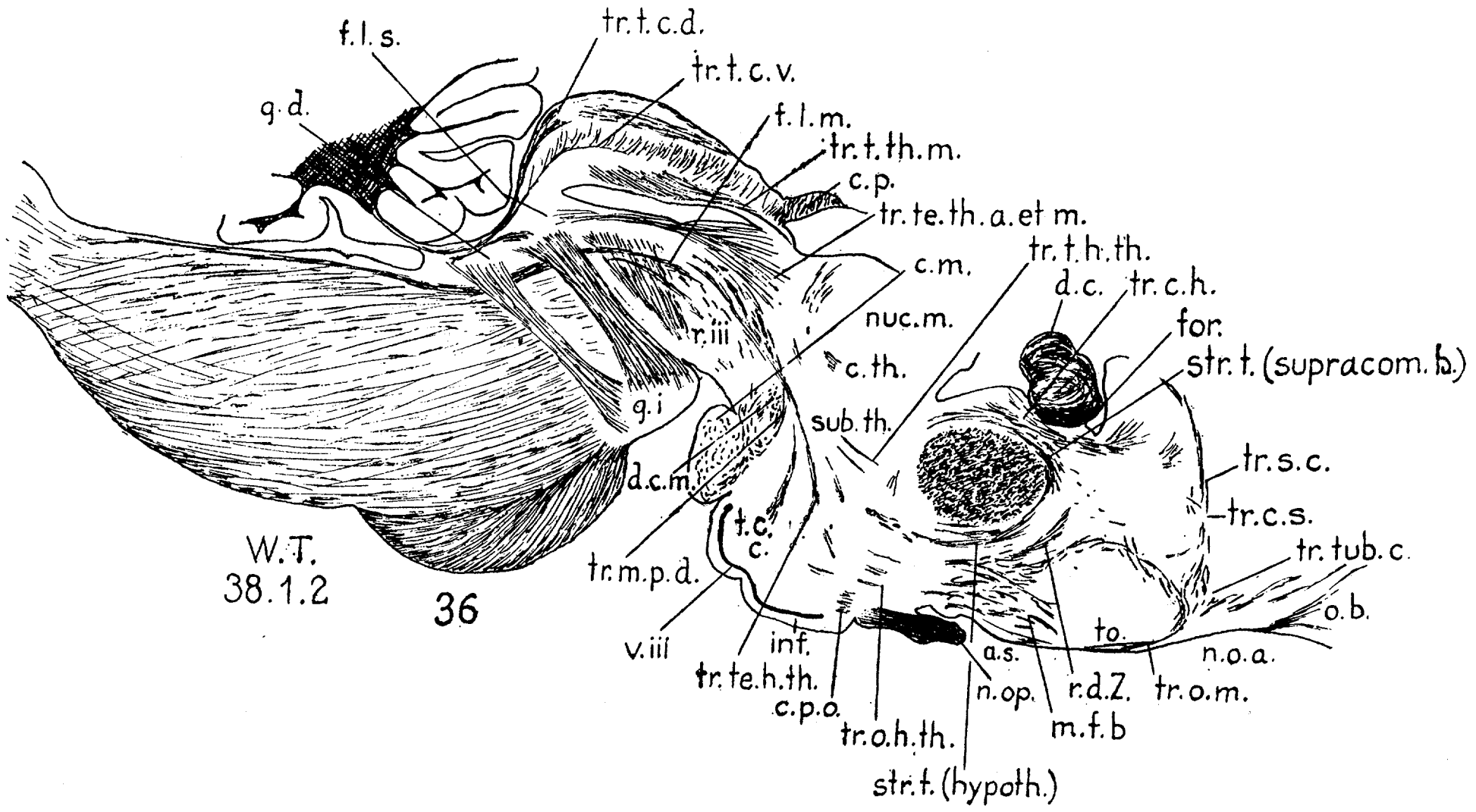
f. l. s.
tr. t. c. d.
tr. t. c. v.
q. d.
f. l. m.
tr. t. th. m.
c. p.
tr. te. th. a. et m.
c. m.
tr. t. h. th.
d. c.
tr. c. h.
nuc. m.
for.
r. iii
c. th.
str. t. (supracom. b.)
q. i
sub. th.
tr. s. c.
d. c. m.
tr. c. s.
t. c.
c.
tr. tub. c.
W.T.
38.1.2
tr. m. p. d.
o. b.
t. o.
n. o. a.
v. iii
inf.
a. s.
tr. te. h. th.
c. p. o.
n. op.
r. d. Z.
tr. o. m.
tr. o. h. th.
m. f. b
str. t. (hypoth.)

36

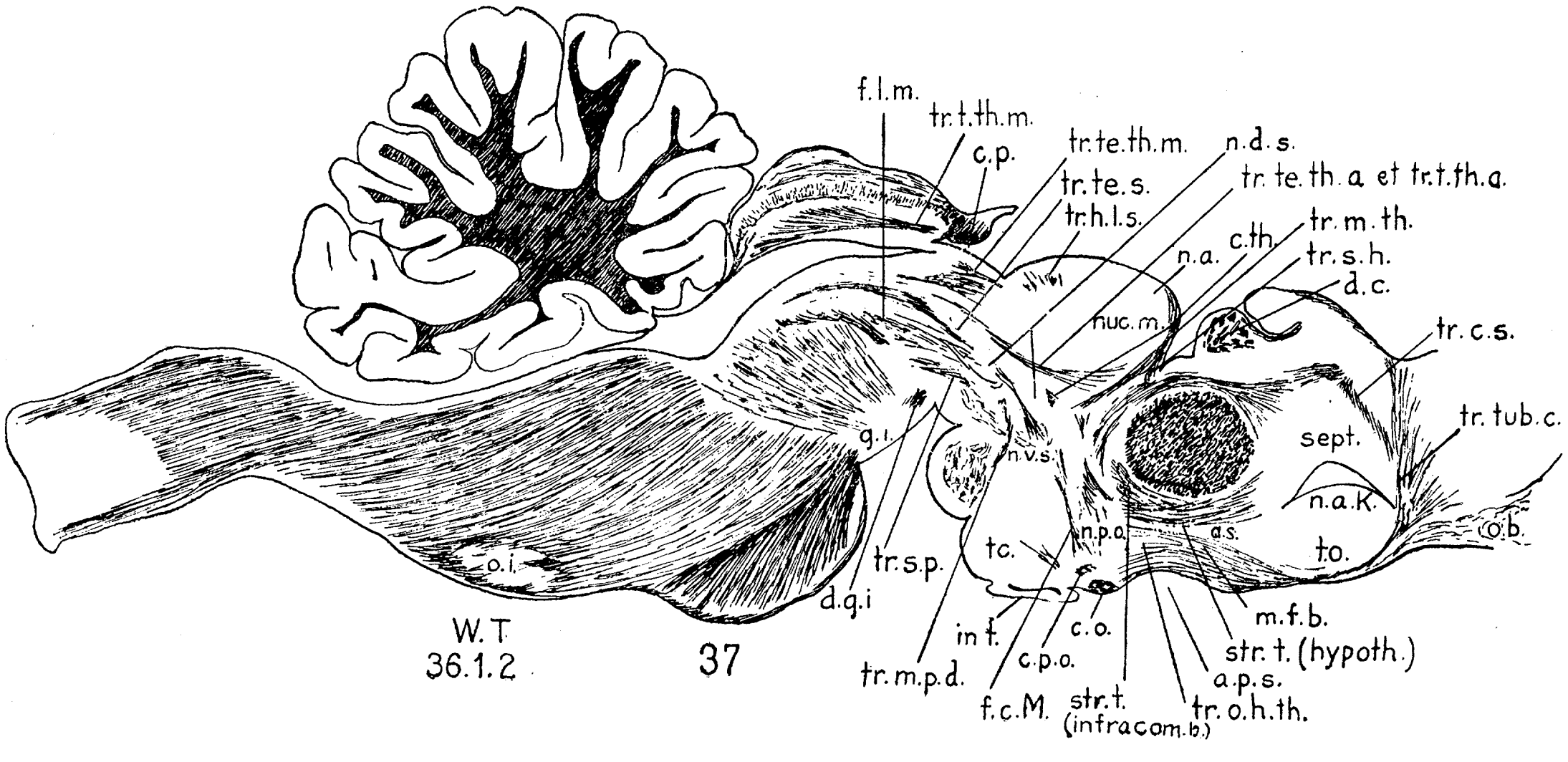
f. l. m.
tr. t. th. m.
c. p.
tr. te. th. m.
n. d. s.
tr. te. s.
tr. te. th. a. et tr. t. th. a.
tr. h. l. s.
c. th.
tr. m. th.
n. a.
tr. s. h.
d. c.
nuc. m.
tr. c. s.
sept.
tr. tub. c.
q. i.
n. v. s.
n. a. K.
o. b.
n. p. o.
a. s.
t. o.
o. i.
tr. s. p.
t c.
d. q. i
in f.
c. o.
m. f. b.
str. t. (hypoth.)
W.T
36.1.2
tr. m. p. d.
c. p. o.
a. p. s.
f. c. M.
str. t. (infracom. b.)
tr. o. h. th.

37

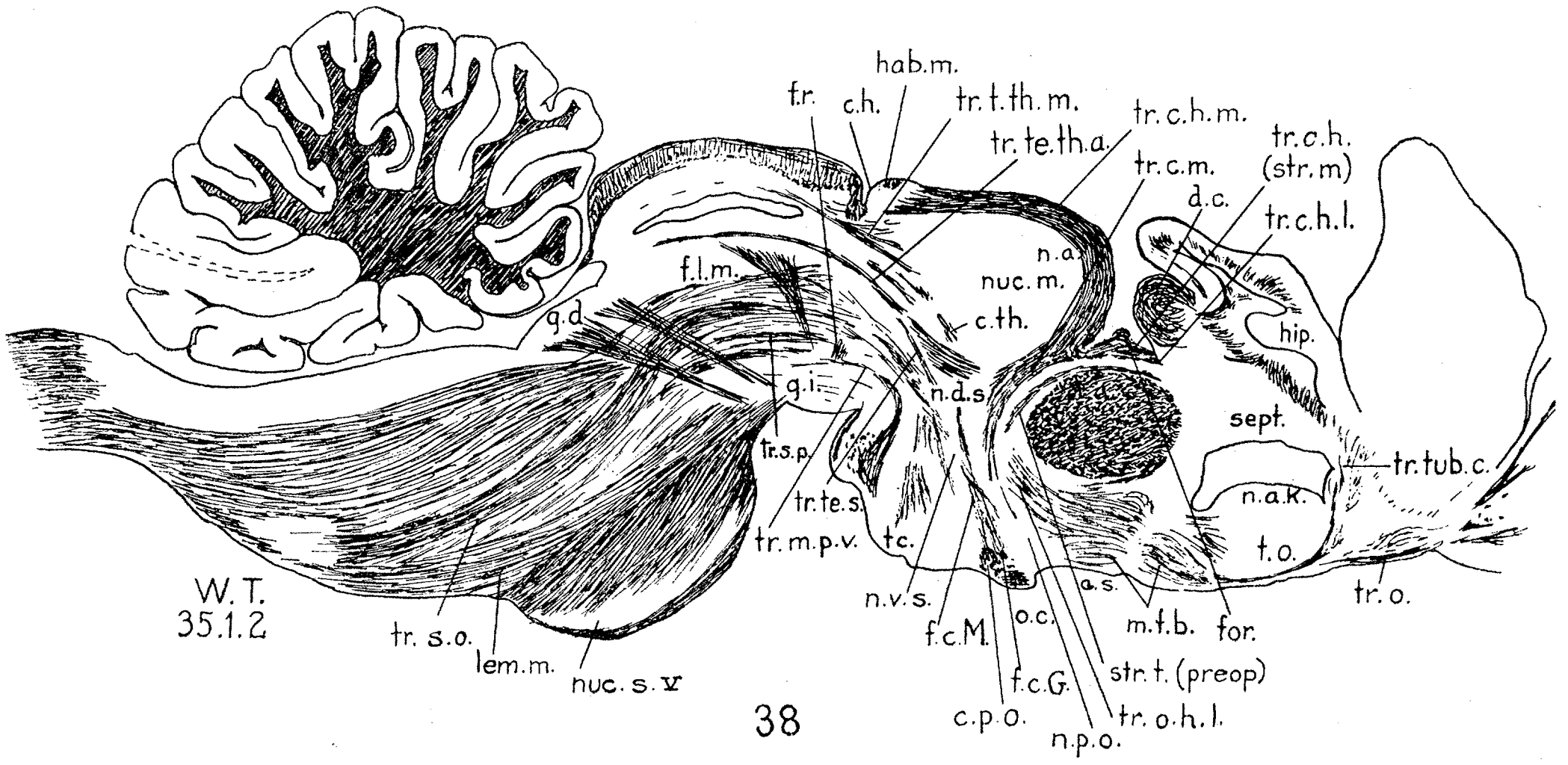
hab.m.
f.r.
c.h.
tr.t.th.m.
tr.c.h.m.
tr.te.th.a.
tr.c.m.
tr.c.h.
(str.m)
d.c.
tr.c.h.l.
n.a.
nuc.m.
c.th.
f.l.m.
g.d.
q.i.
tr.s.p.
n.d.s.
hip.
sept.
tr.tub.c.
n.a.K.
t.o.
tr.o.
tr.te.s.
tr.m.p.v.
t.c.
n.v.s.
a.s.
m.f.b.
for.
f.c.M.
o.c.
f.c.G.
str.t. (preop)
tr.o.h.l.
c.p.o.
n.p.o.
W.T.
35.1.2
tr.s.o.
lem.m.
nuc.s.V

38

39

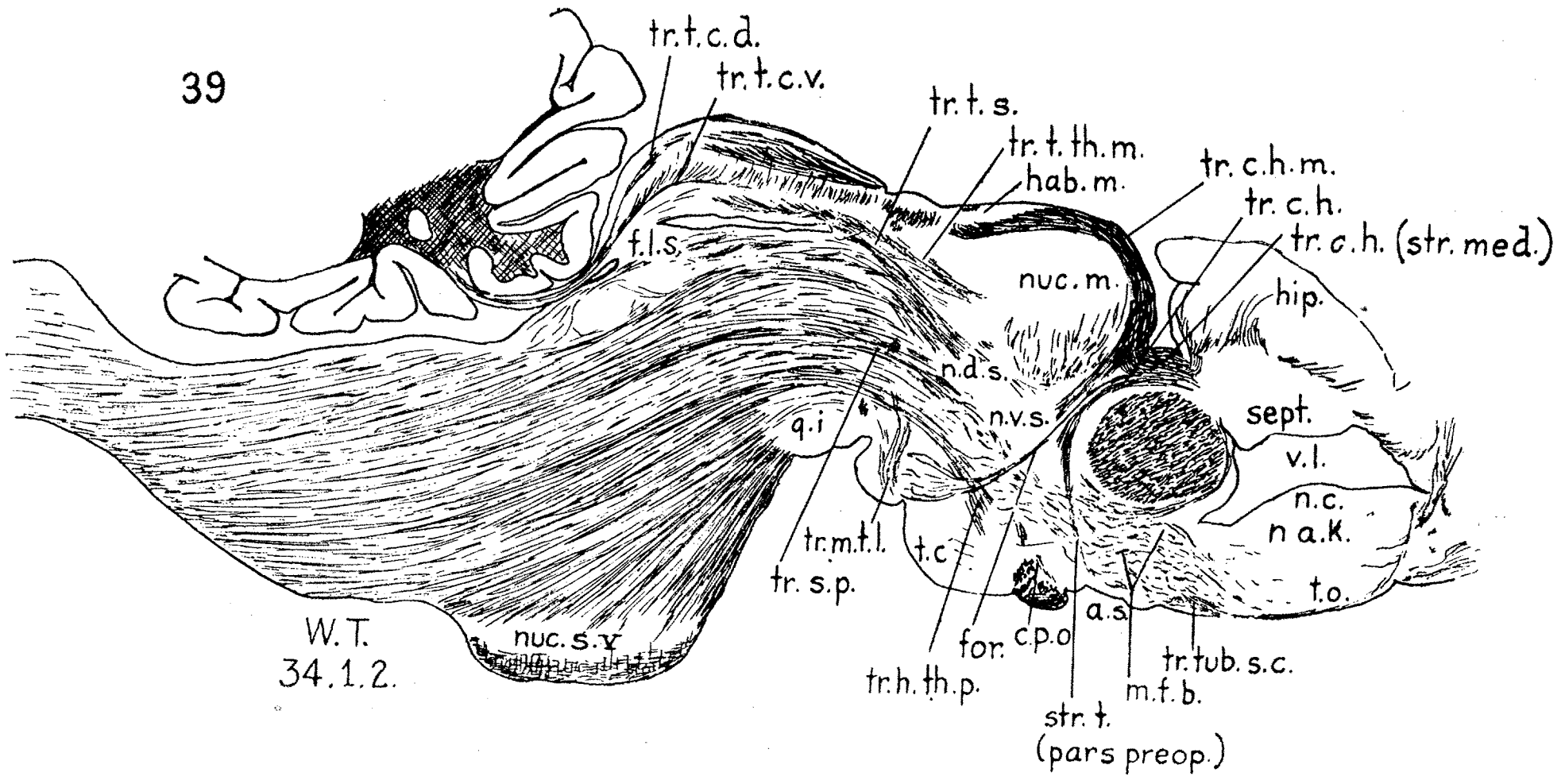
tr.t.c.d.
tr.t.c.v.
tr.t.s.
tr.t.th.m.
hab.m.
tr.c.h.m.
tr.c.h.
tr.c.h. (str.med.)
f.l.s.
nuc.m.
hip.
n.d.s.
n.v.s.
sept.
v.l.
q.i.
n.c.
n.a.K.
tr.m.t.l.
t.c.
tr.s.p.
t.o.
a.s.
c.p.o.
for.
tr.tub.s.c.
m.f.b.
tr.h.th.p.
str.t.
(pars preop.)
W.T.
34.1.2.
nuc.s.V

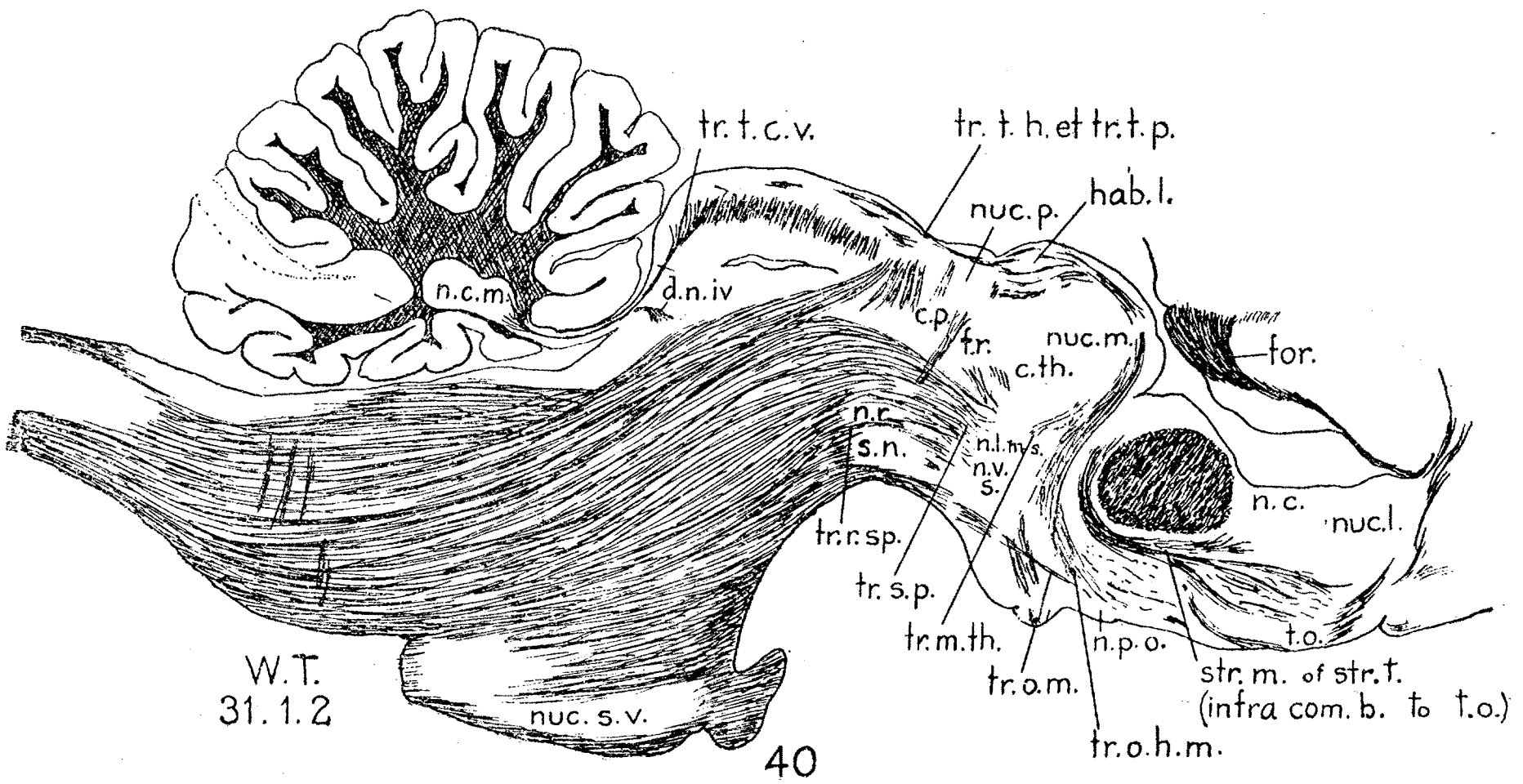
tr.t.c.v.
tr.t.h. et tr.t.p.
nuc.p.
hab.l.
n.c.m.
d.n.iv
c.p.
f.r.
nuc.m.
c.th.
for.
n.r.
s.n.
n.l.m.s.
n.v.s.
tr.r.sp.
n.c.
nuc.l.
tr.s.p.
tr.m.th.
t.o.
n.p.o.
tr.o.m.
str.m. of str.t.
(infra com.b. to t.o.)
tr.o.h.m.
W.T.
31.1.2
nuc.s.v.

40

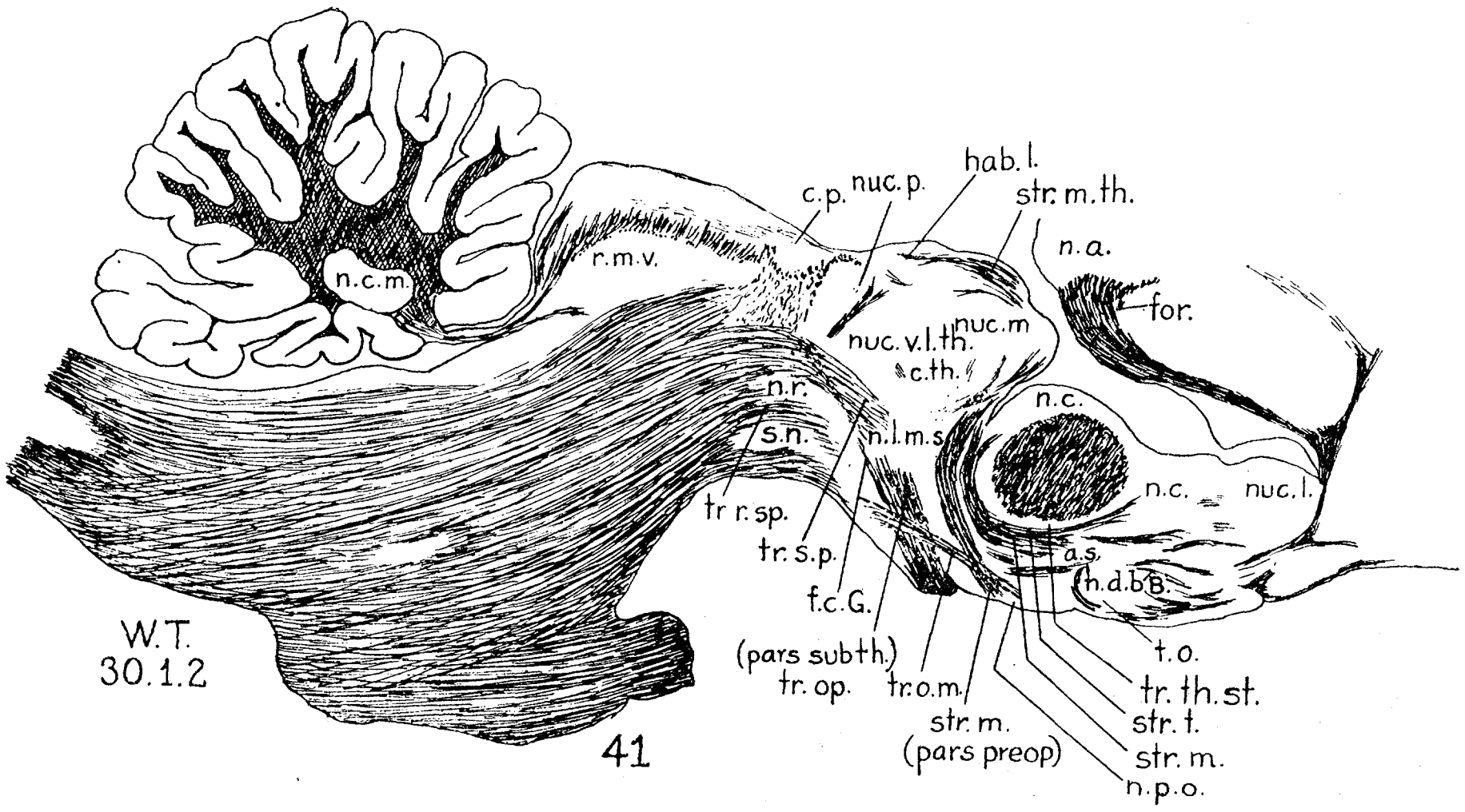
n.c.m.
r.m.v.
c.p.
nuc.p.
hab.l.
str. m.th.
n.a.
for.
nuc.v.l.th.
nuc.m
c.th.
n.r.
s.n.
n.l.m.s.
n.c.
n.c.
nuc.l.
tr r.sp.
tr. s.p.
f.c.G.
a.s.
h.d.b.B.
t.o.
(pars subth.)
tr. op.
tr.o.m.
str. m.
(pars preop)
tr. th. st.
str. t.
str. m.
n.p.o.
W.T.
30.1.2

41

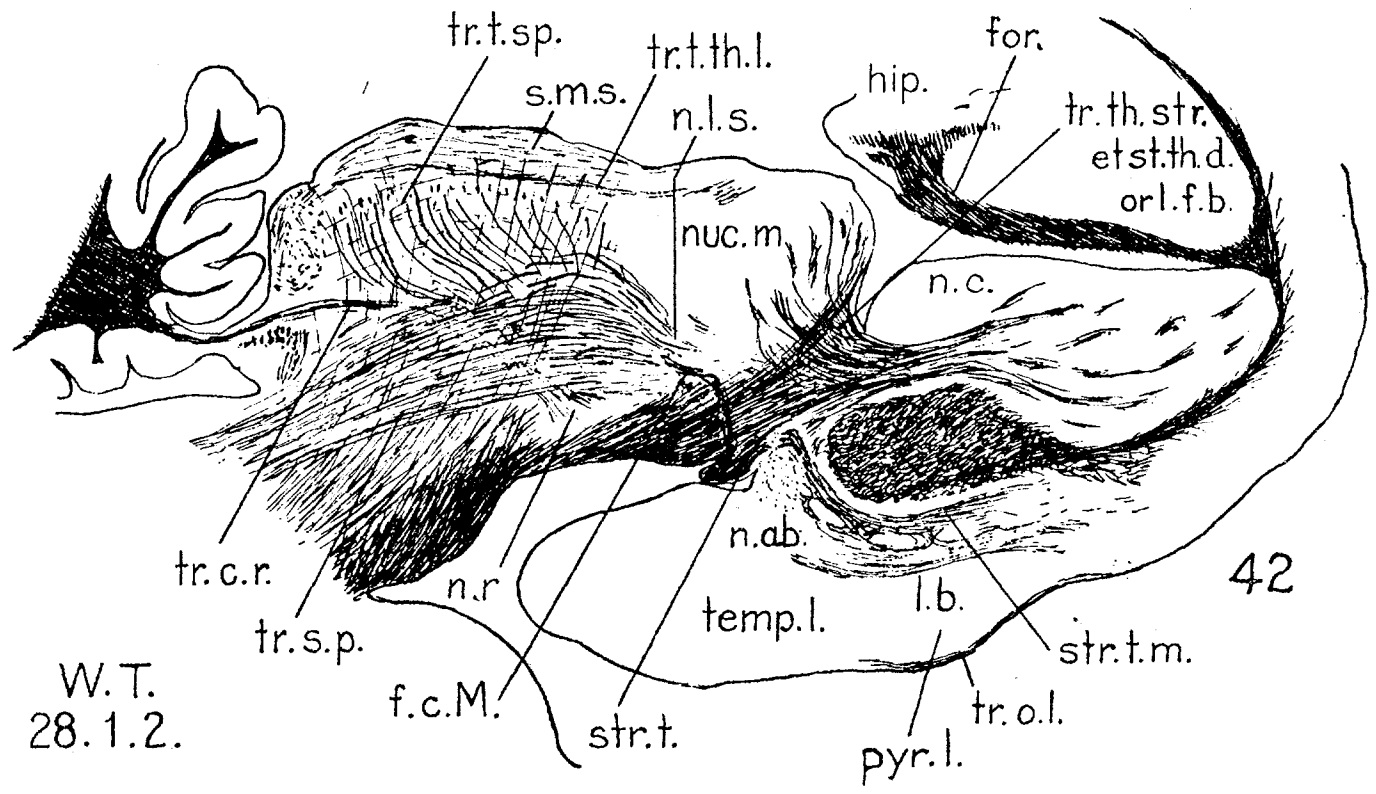
tr.t.sp.
tr.t.th.l.
s.m.s.
n.l.s.
hip.
for.
tr. th. str.
et st.th.d.
or l.f.b.
nuc.m.
n.c.
n.ab.
tr. c.r.
tr. s.p.
n.r
f.c.M.
str. t.
temp. l.
l.b.
str. t.m.
tr. o.l.
pyr. l.
W.T.
28.1.2.

42

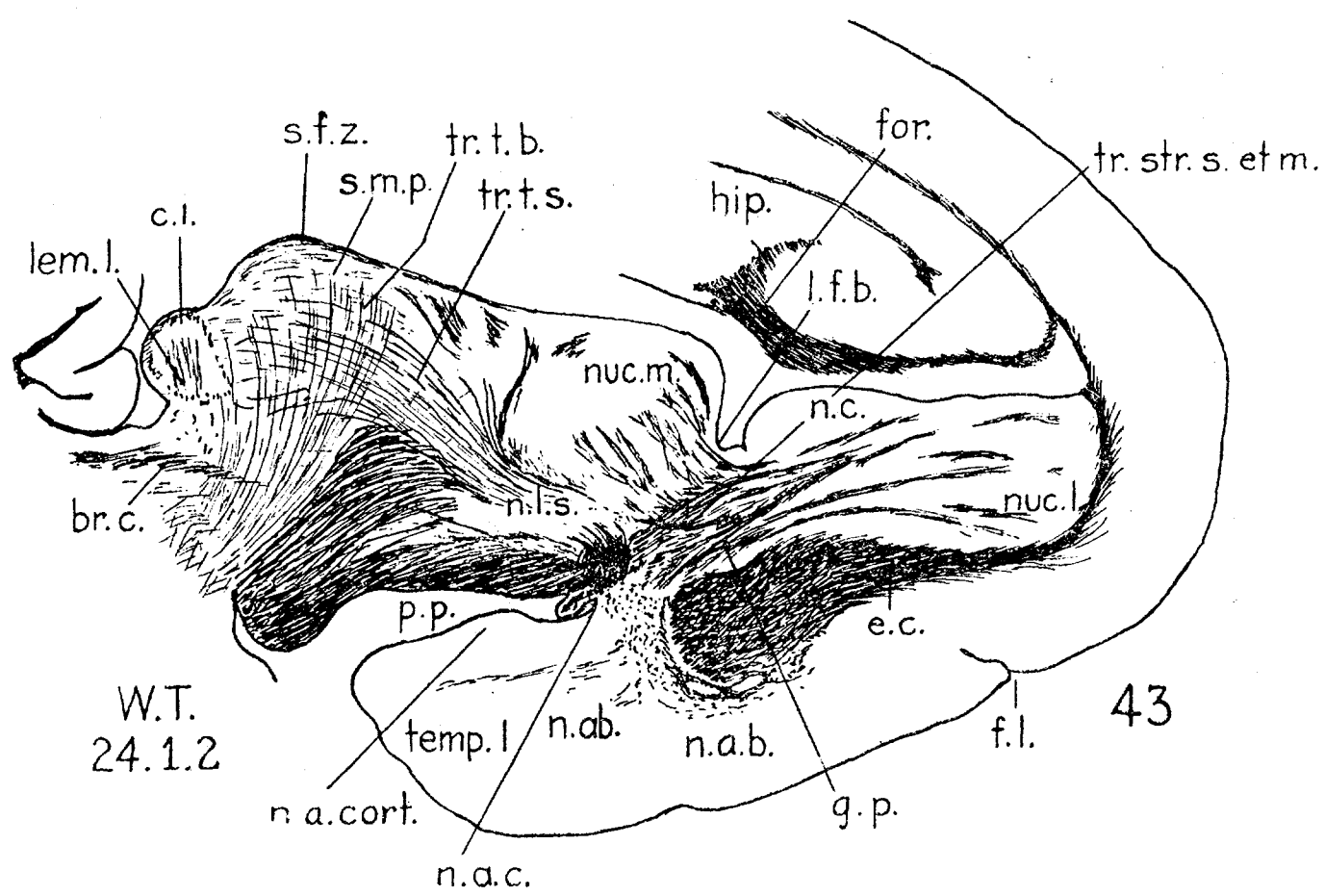
s.f.z.
tr. t.b.
s.m.p.
tr. t.s.
c.l.
lem.l.
hip.
for.
tr. str. s. et m.
l.f.b.
nuc.m
n.c.
nuc.l.
br.c.
n.l.s.
p.p.
e.c.
W.T.
24.1.2
temp. l
n.ab.
n.a.b.
f.l.
n a.cort.
n.a.c.
g.p.

43

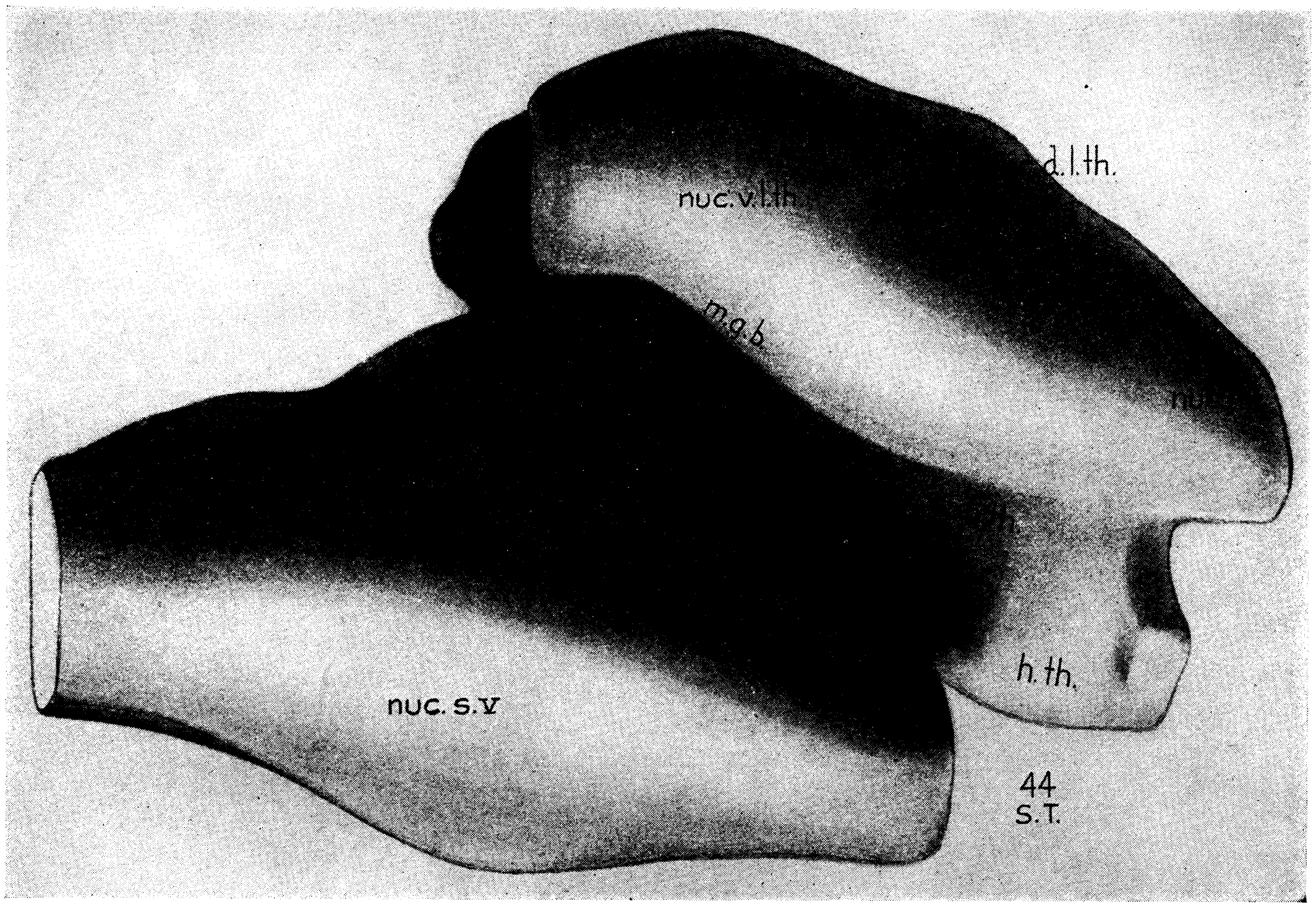
d.l.th.
nuc.v.l.th.
m.a.b.
h.th.
nuc. s.V
44
S.T.

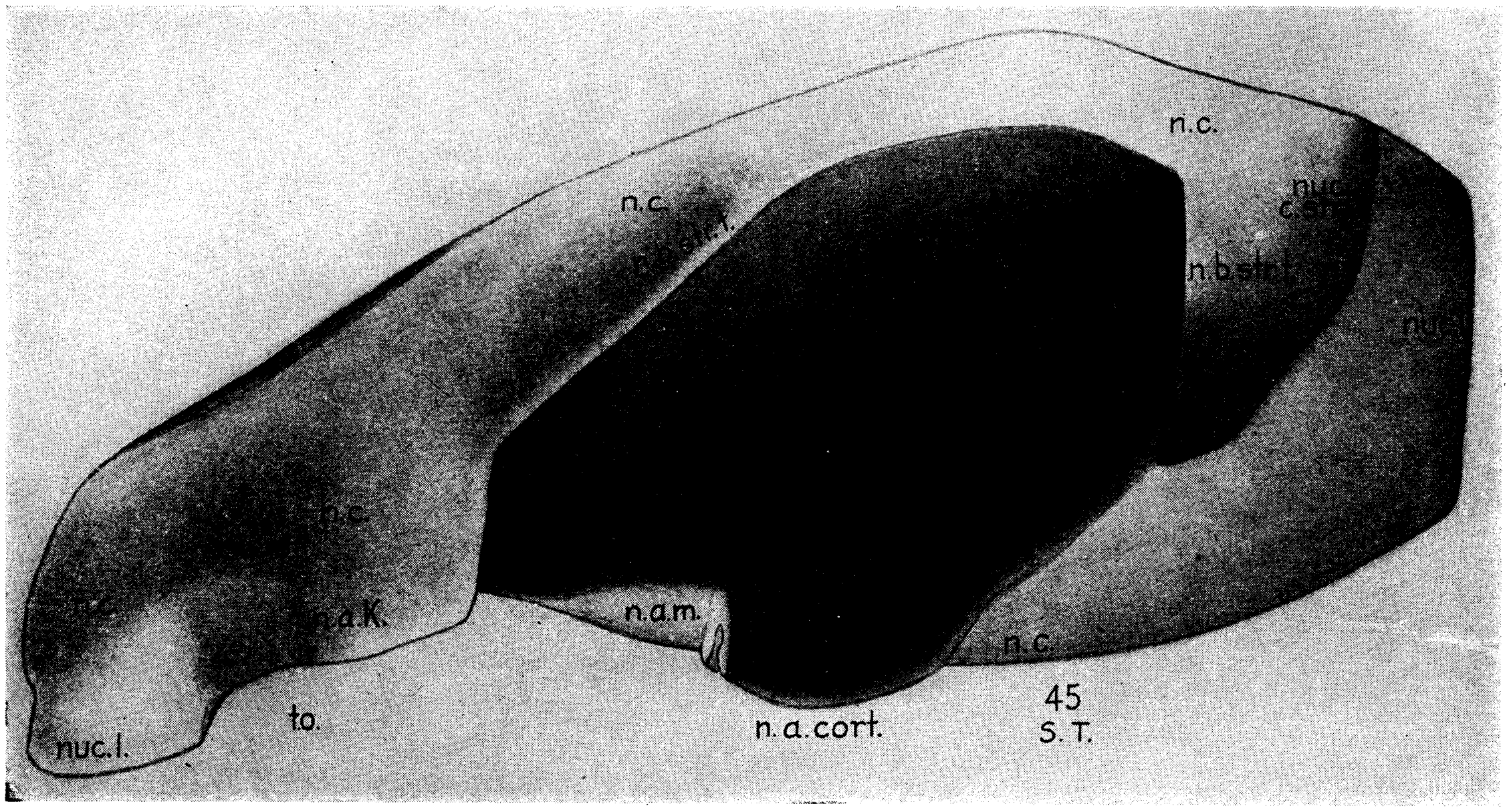
n.c.
n.c.
nuc.
c.st.
n.b.st.t.
nuc.
n.c.
n.a.K.
n.a.m.
n.c.
45
S.T.
nuc.l.
to.
n.a.cort.

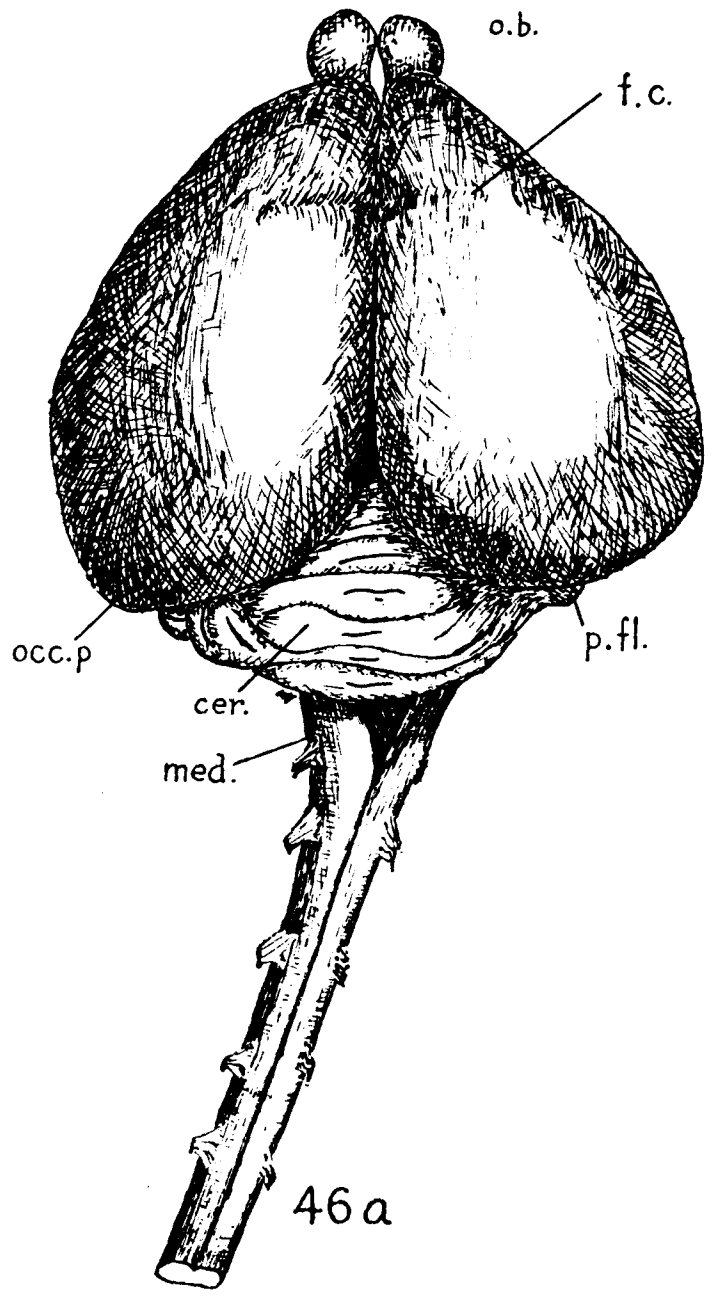

46*a*

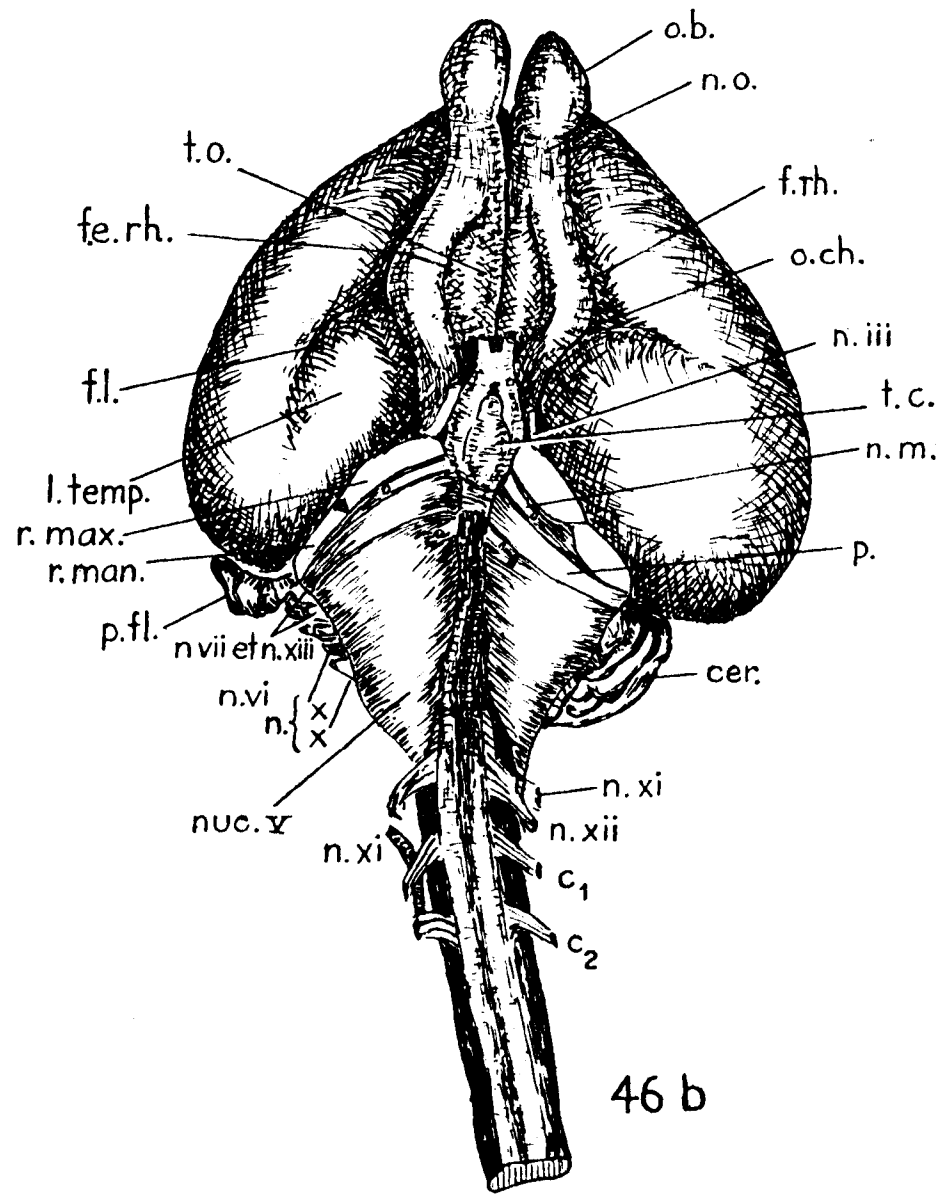

46 b

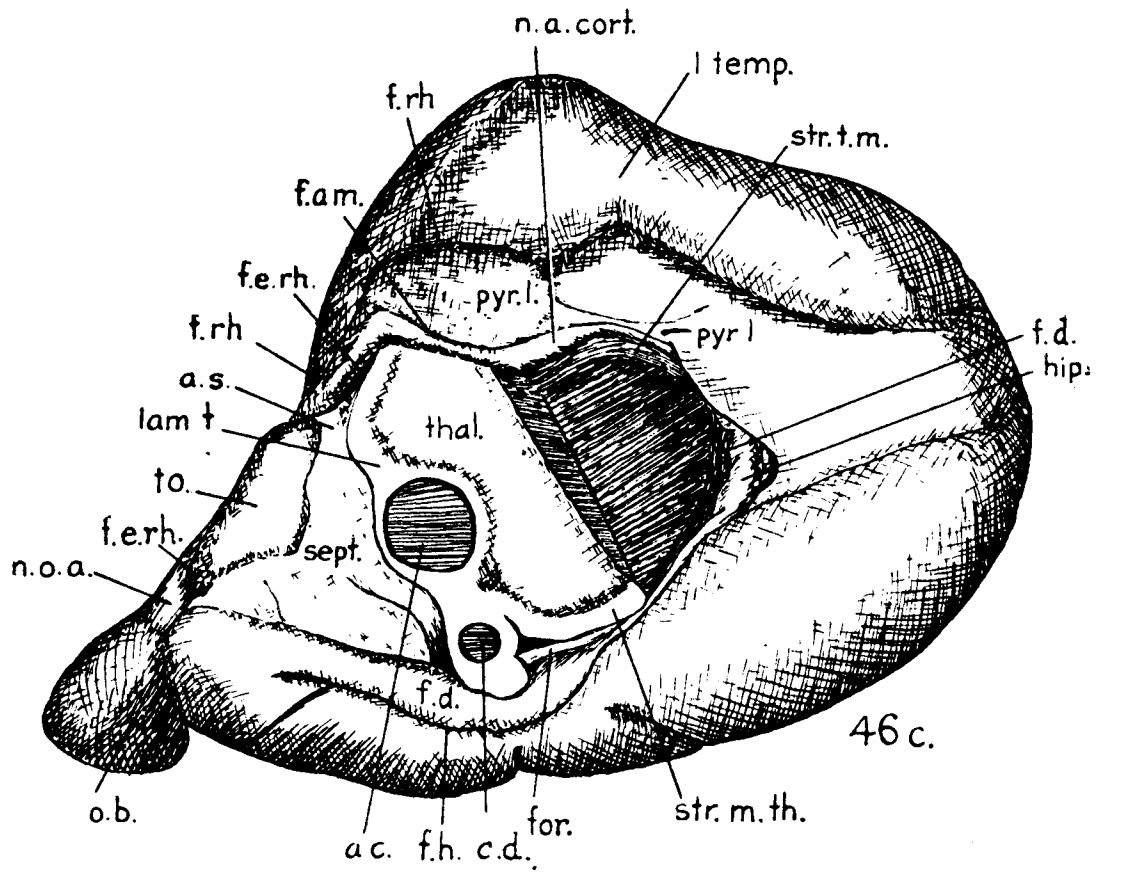

46 c.

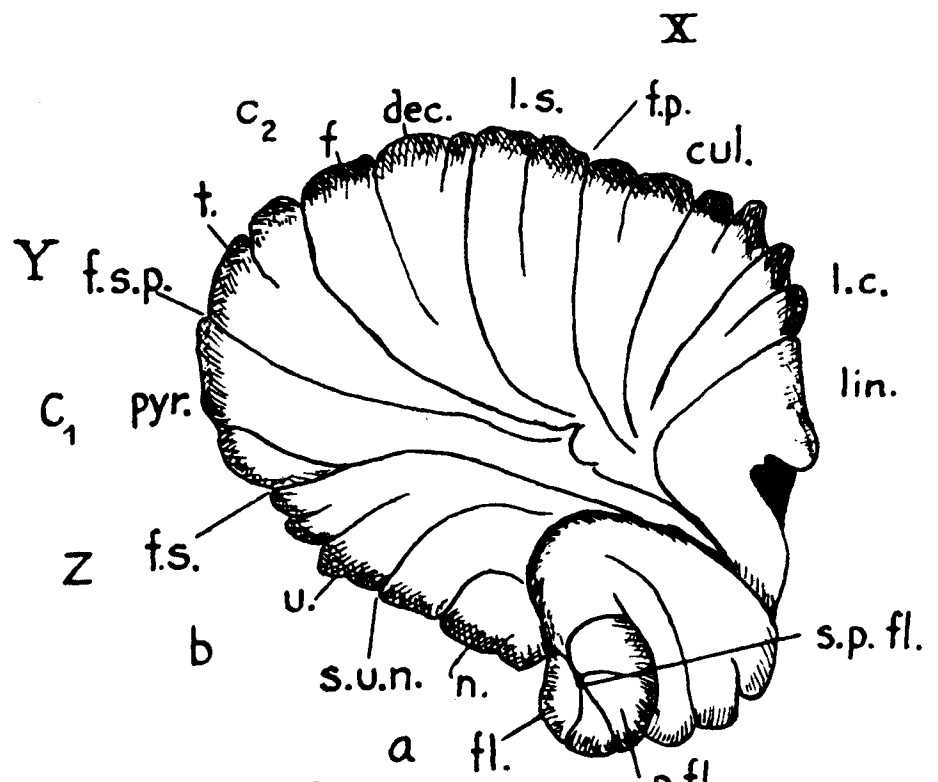

47 *a*.

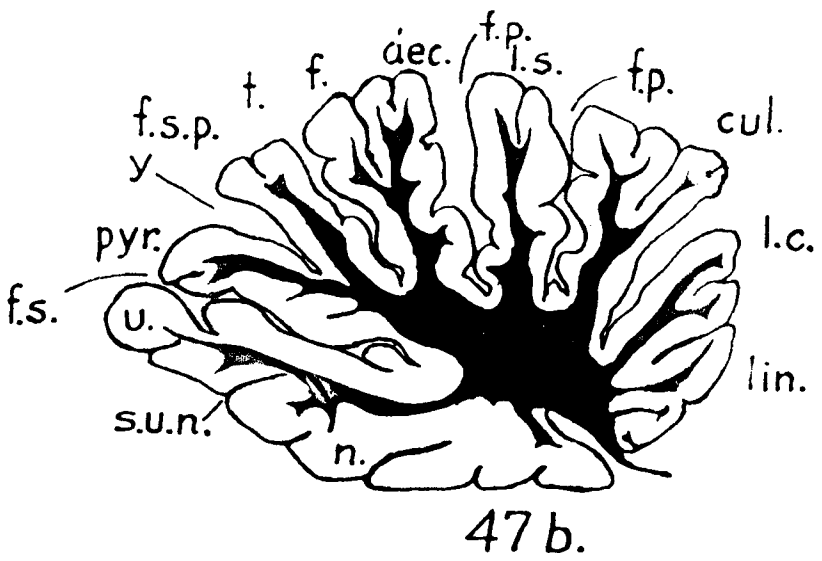

47 *b*.

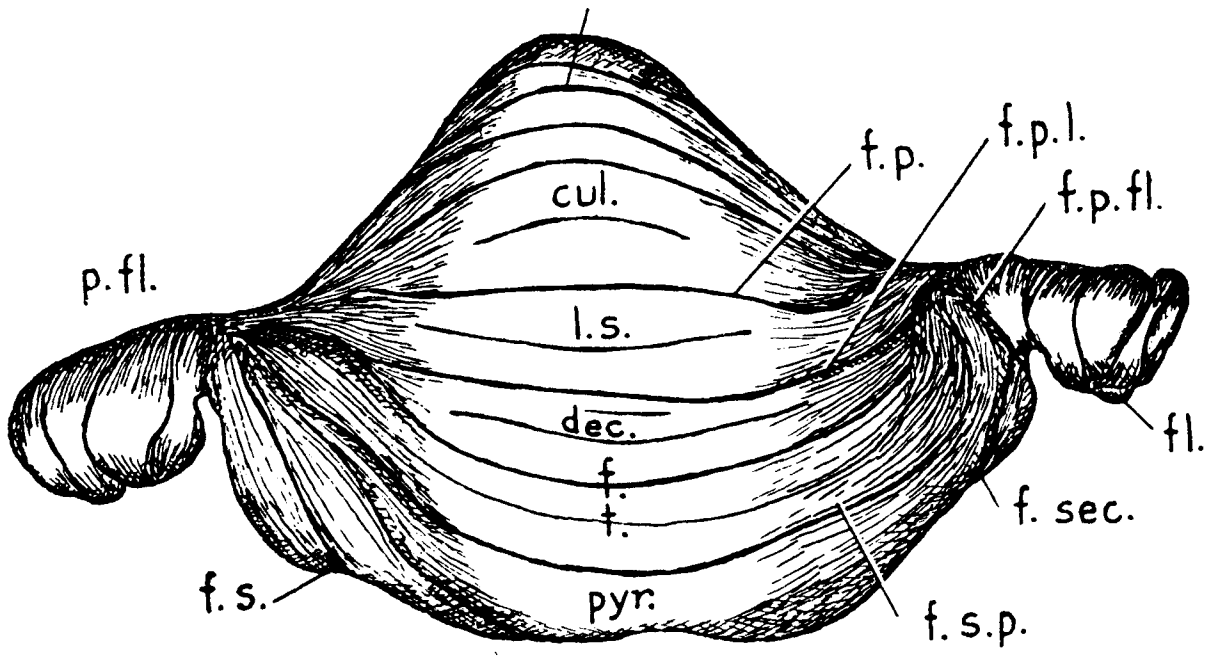

47 c.

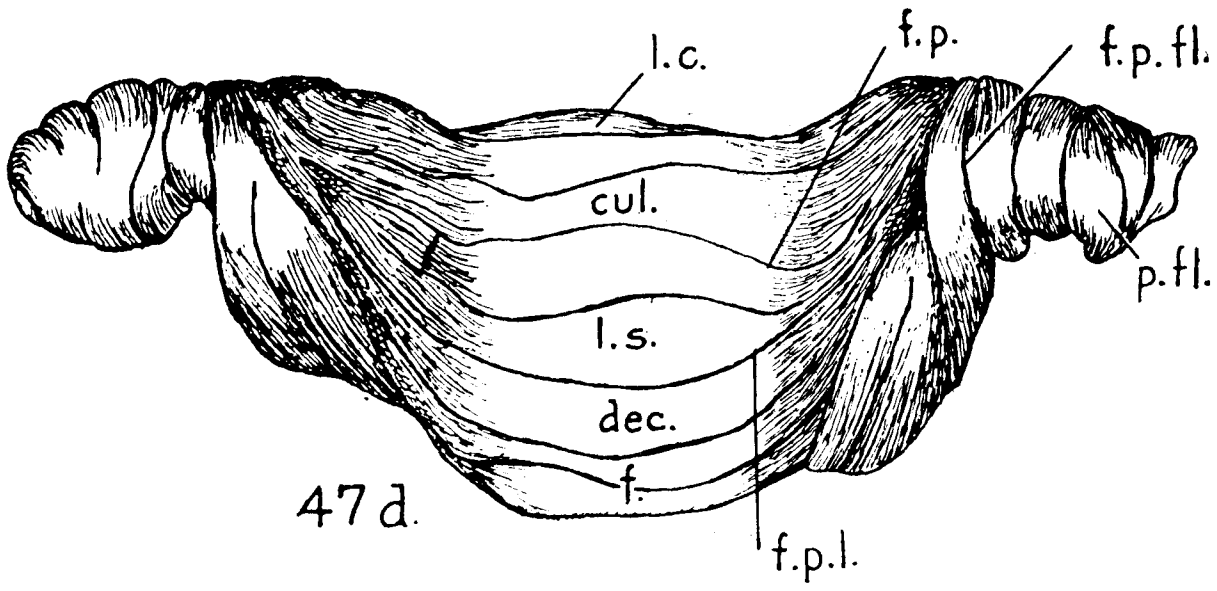

47 d.

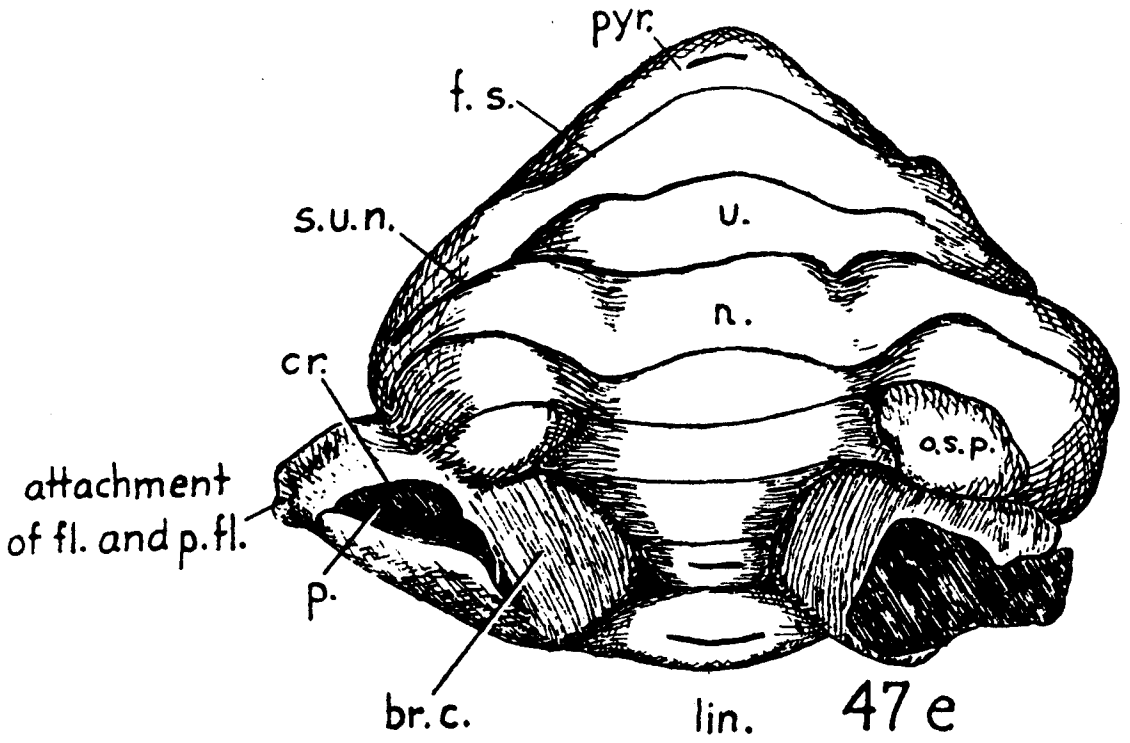

47 e

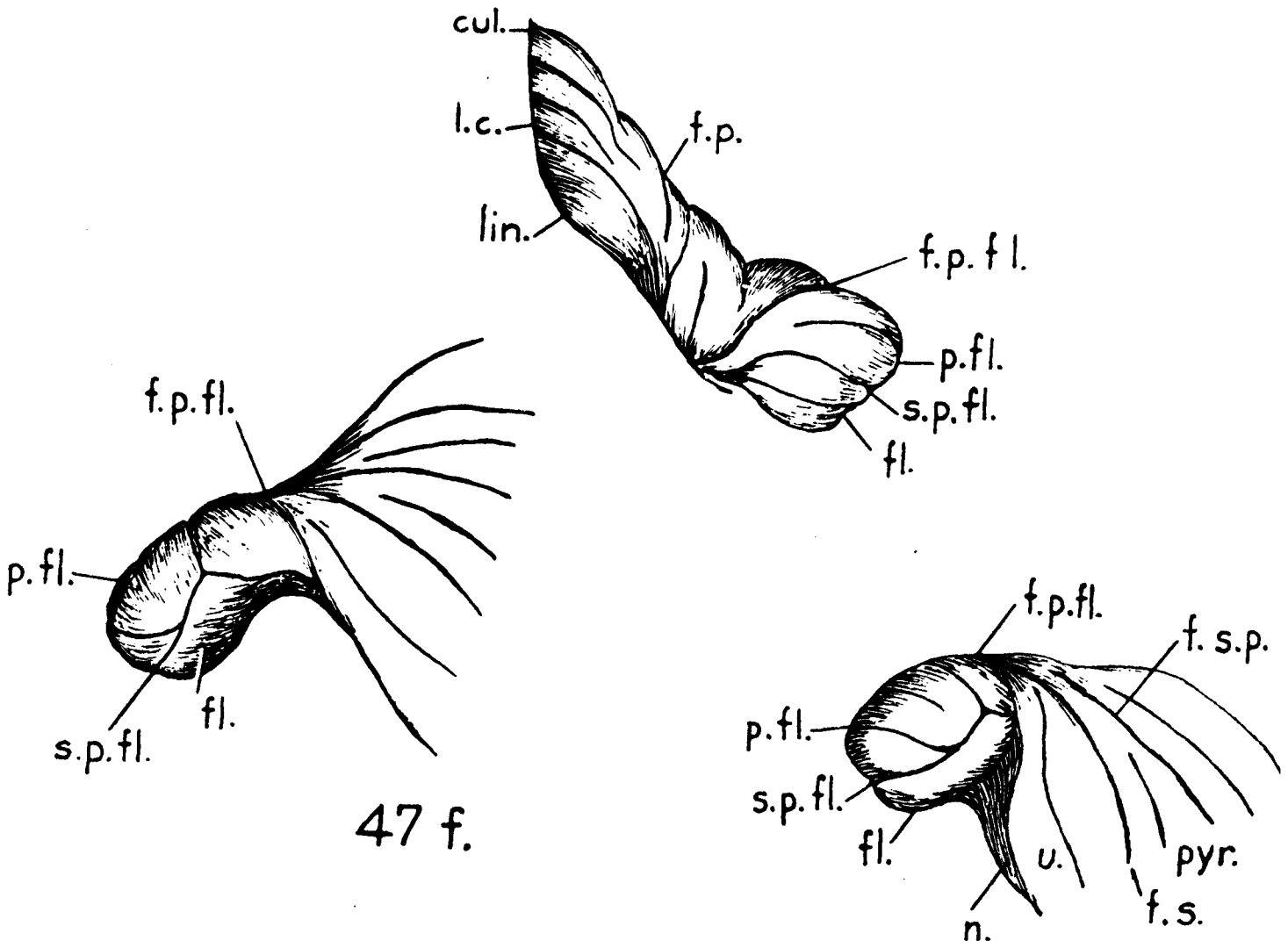

47 f.

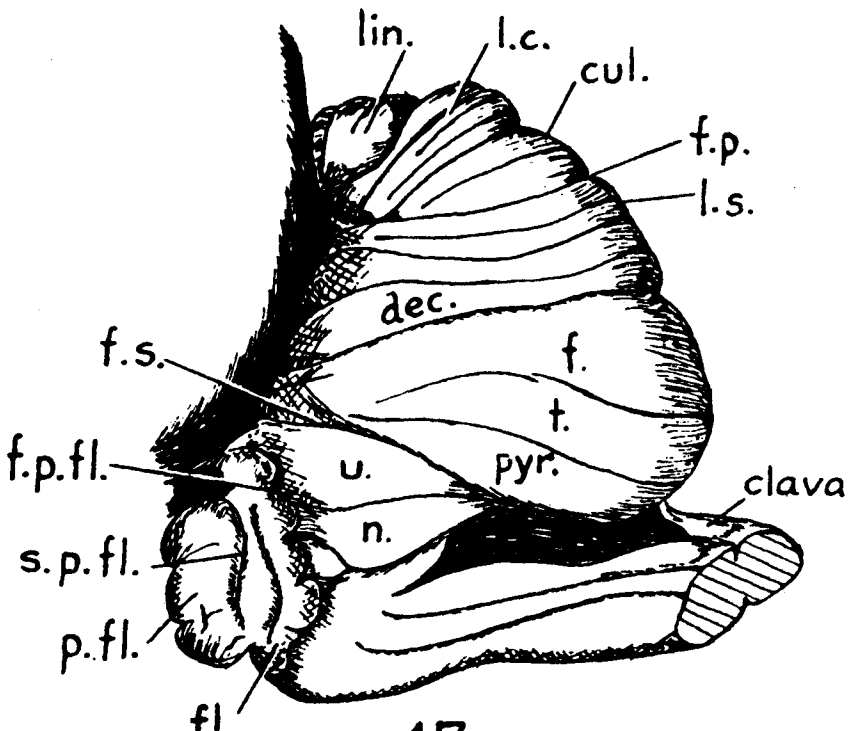

47g.

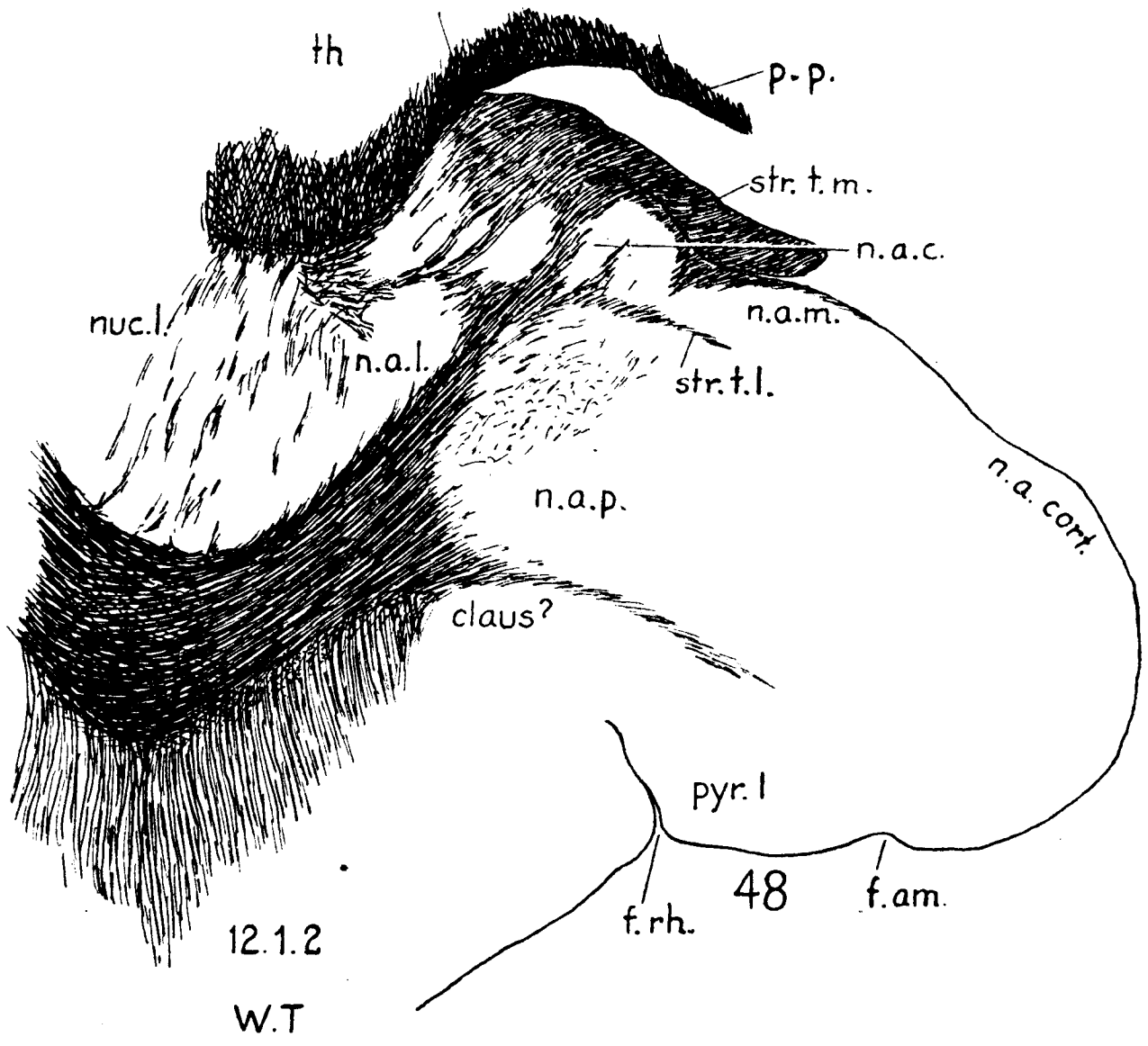
48

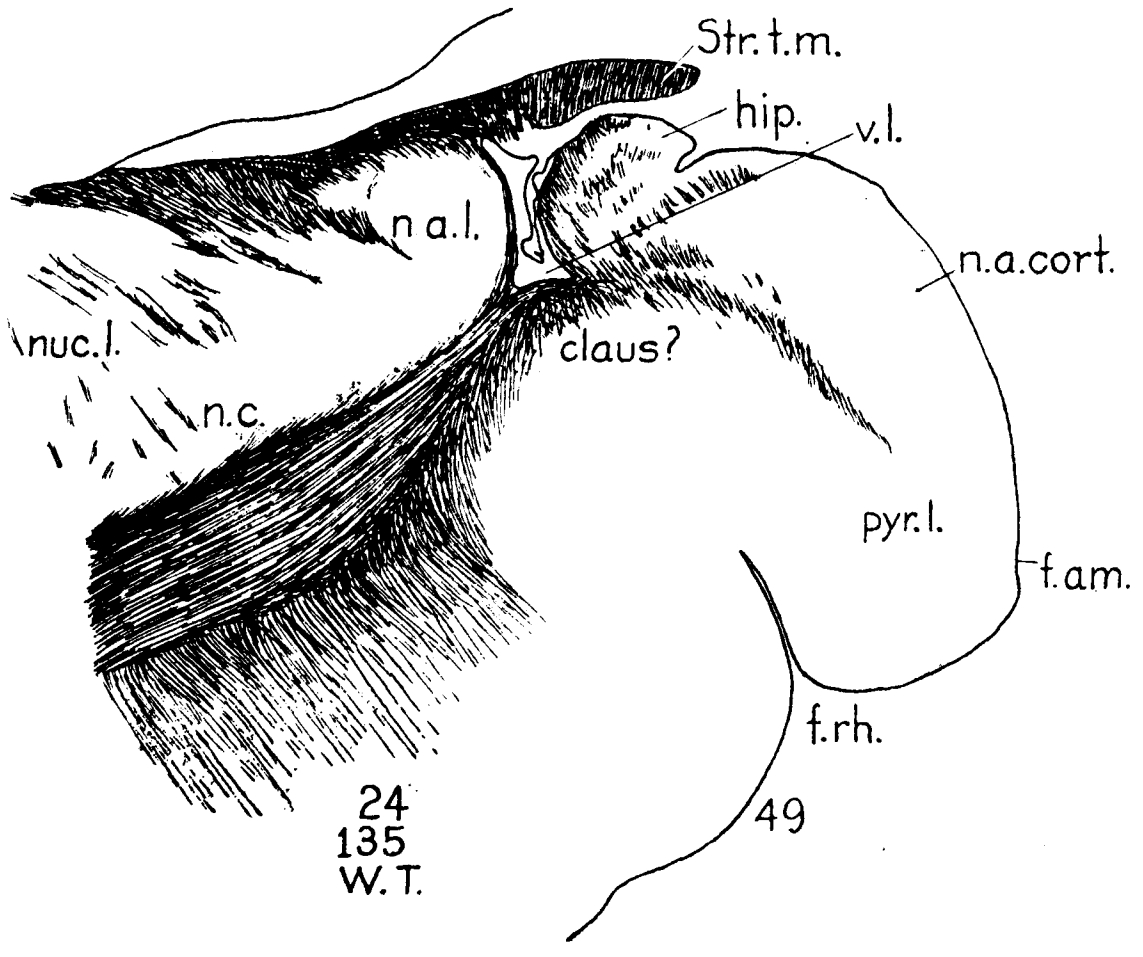
49

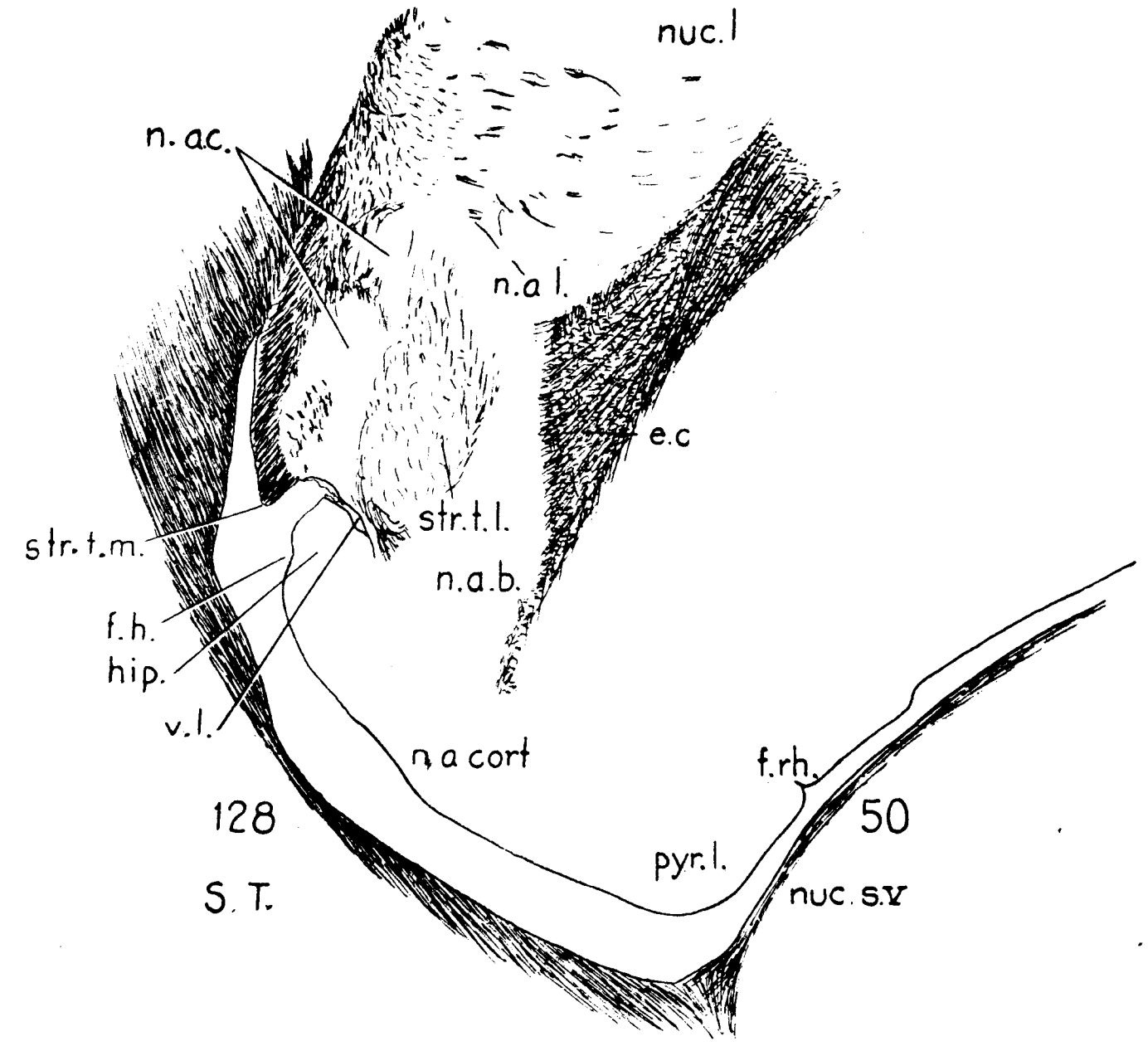
50

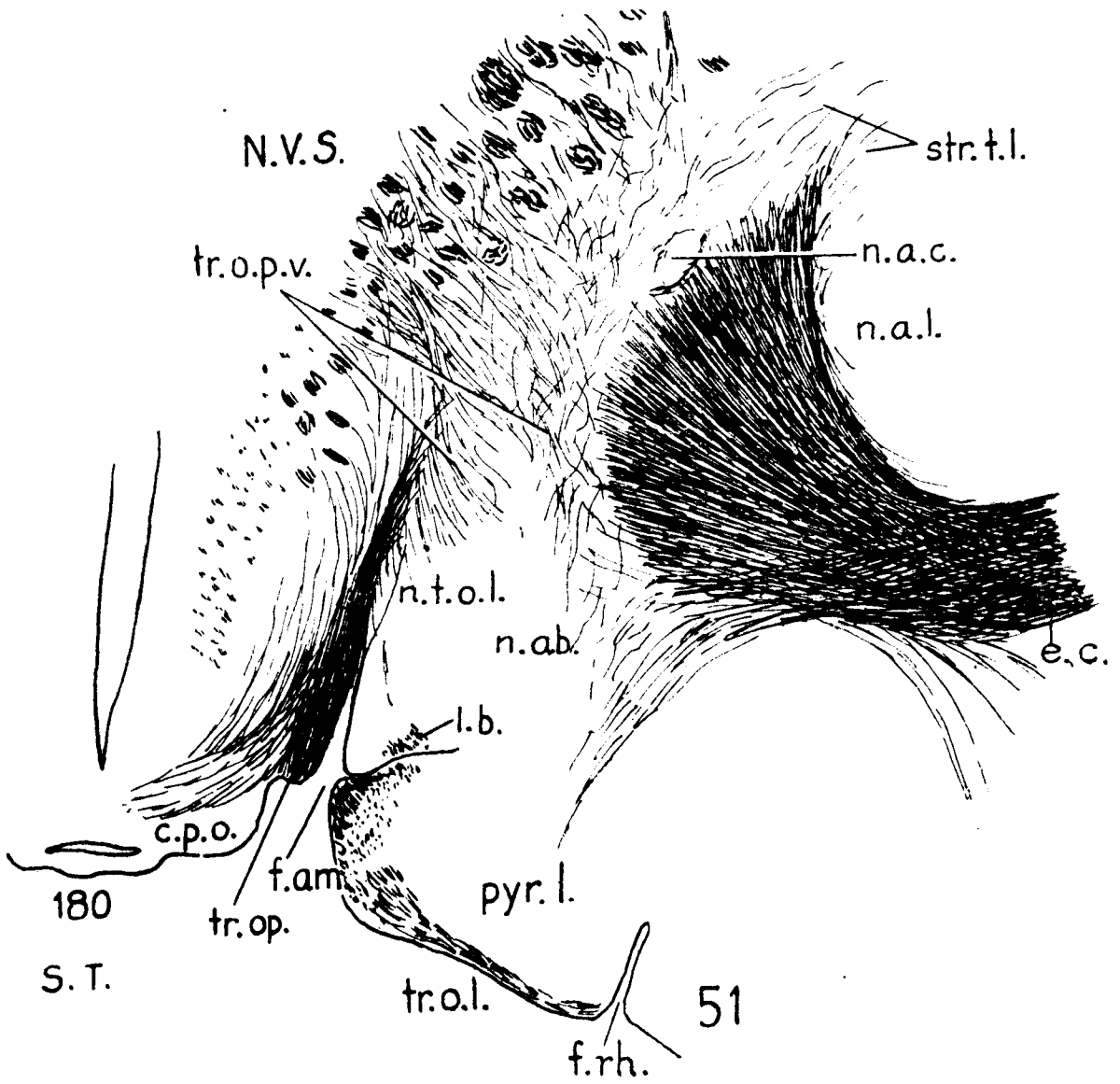
51

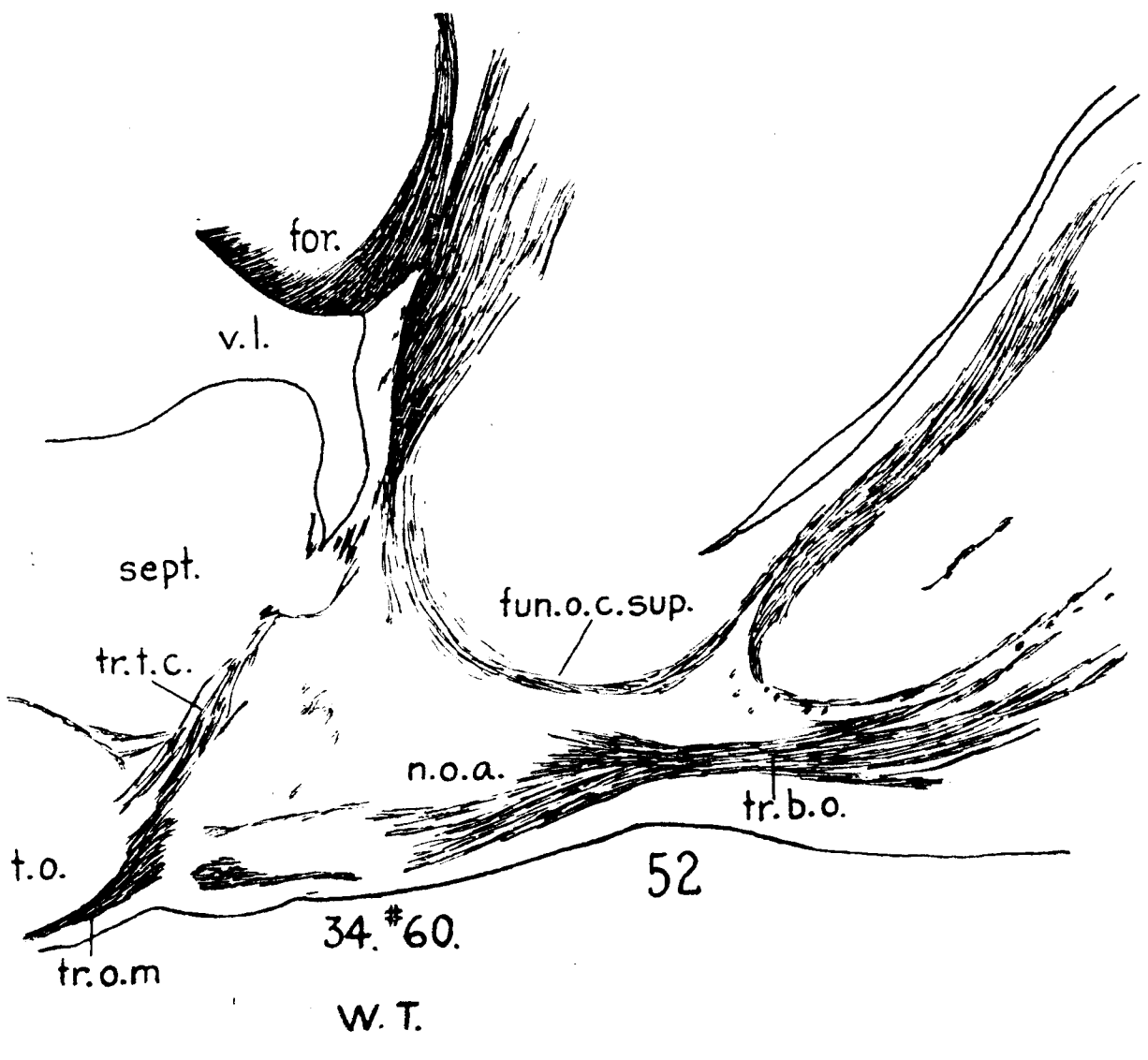
52

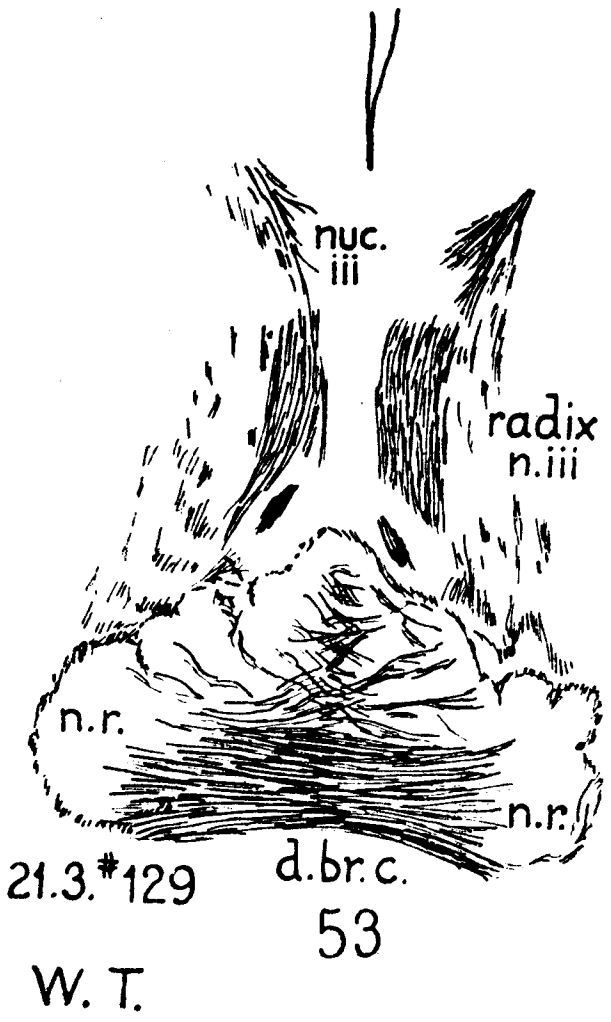
53

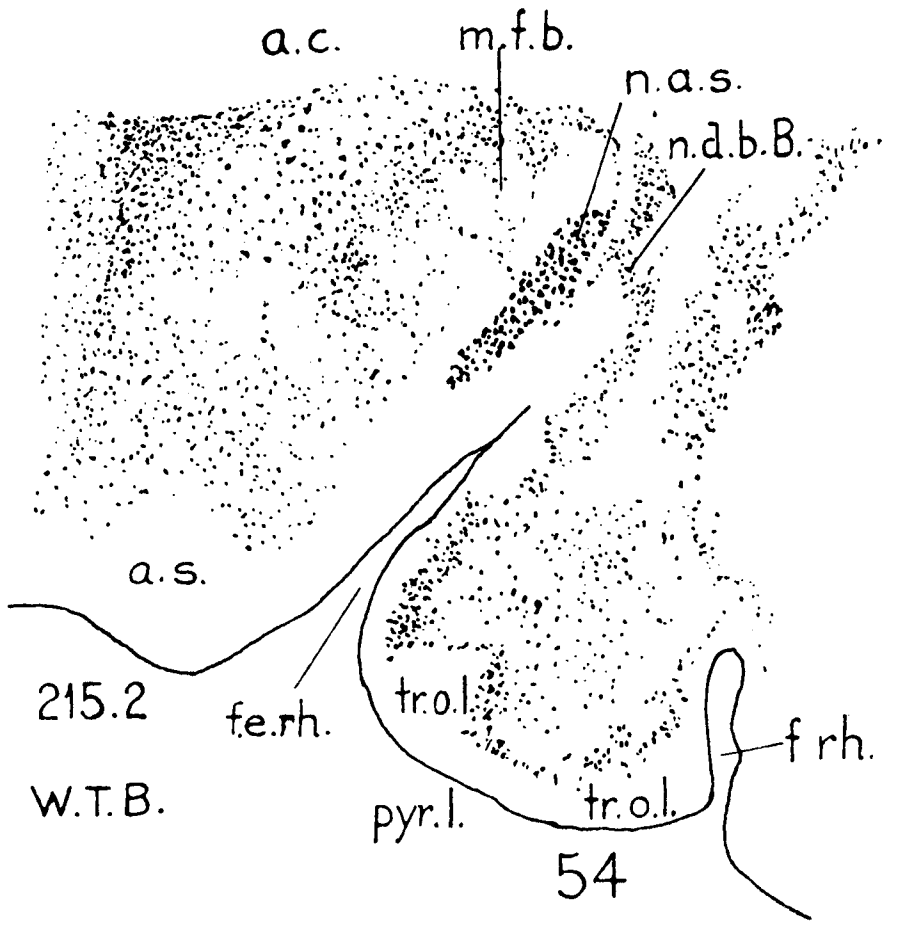
a.c.
m.f.b.
n.a.s.
n.d.b.B.
a.s.
215.2
W.T.B.
f.e.rh.
tr.o.l.
pyr.l.
tr.o.l.
f.rh.

54

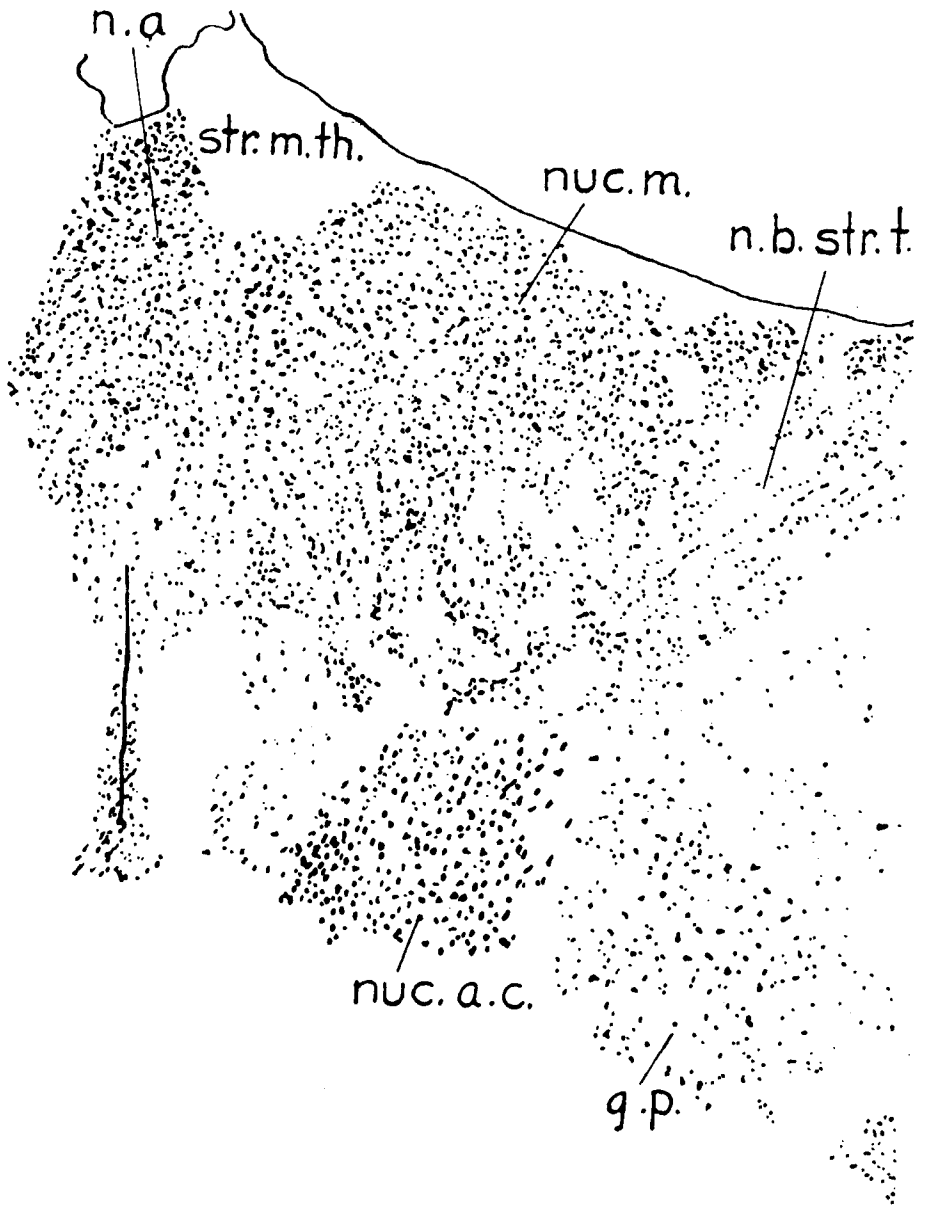
n.a
str.m.th.
nuc.m.
n.b.str.t.
nuc.a.c.
g.p.

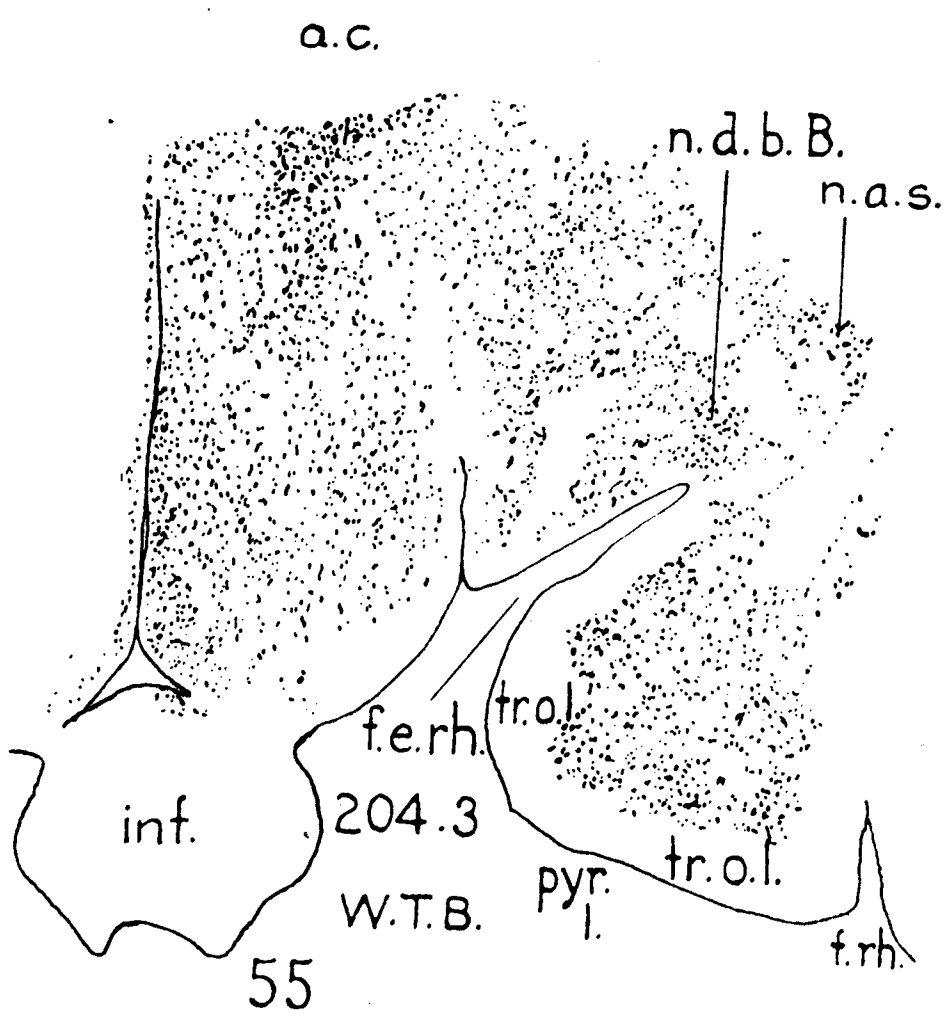
a.c.
n.d.b.B.
n.a.s.
f.e.rh.
tr.o.l.
inf.
204.3
W.T.B.
pyr.l.
tr.o.l.
f.rh.

55

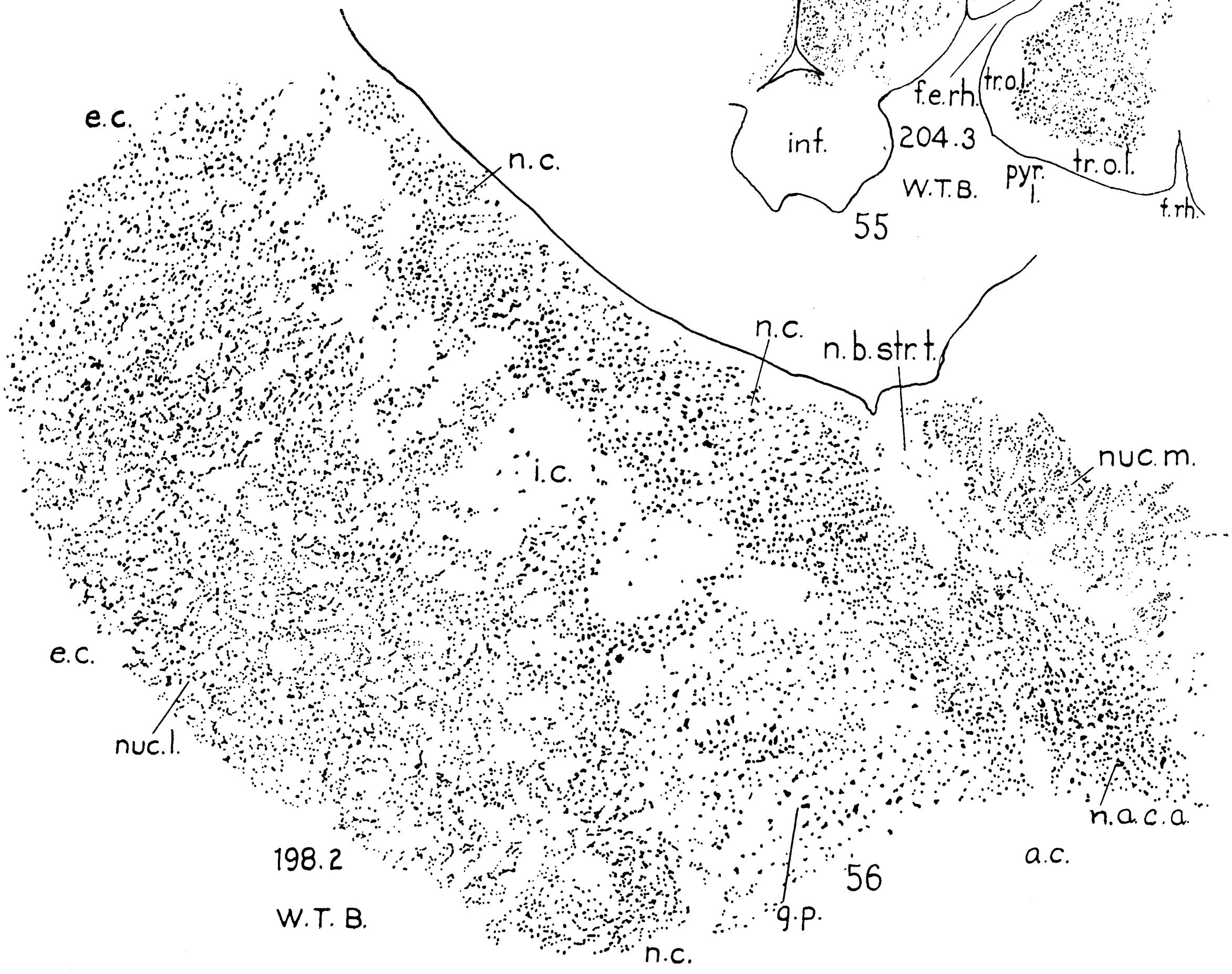
e.c.
n.c.
n.c.
n.b.str.t.
i.c.
nuc.m.
e.c.
nuc.l.
n.a.c.a.
198.2
W.T.B.
a.c.
g.p.
n.c.

56

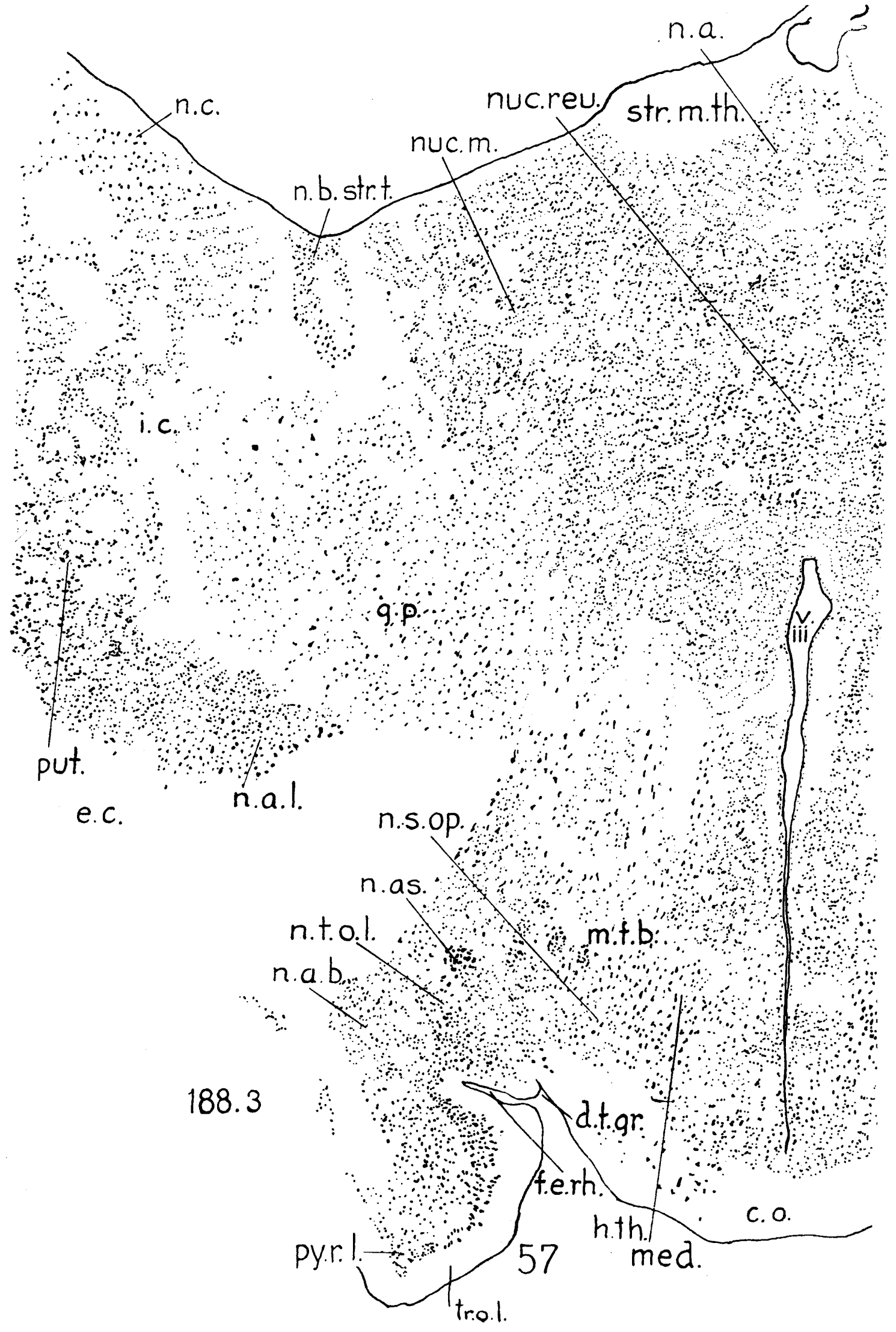
n.a.
nuc.reu.
str.m.th.
n.c.
nuc.m.
n.b.str.t.
i.c.
q.p.
V.
iii
put.
e.c.
n.a.l.
n.s.op.
n.as.
n.t.o.l.
m.t.b.
n.a.b.
188.3
d.t.gr.
f.e.rh.
c.o.
h.th.
med.
py.r.l.
57
tr.o.l.

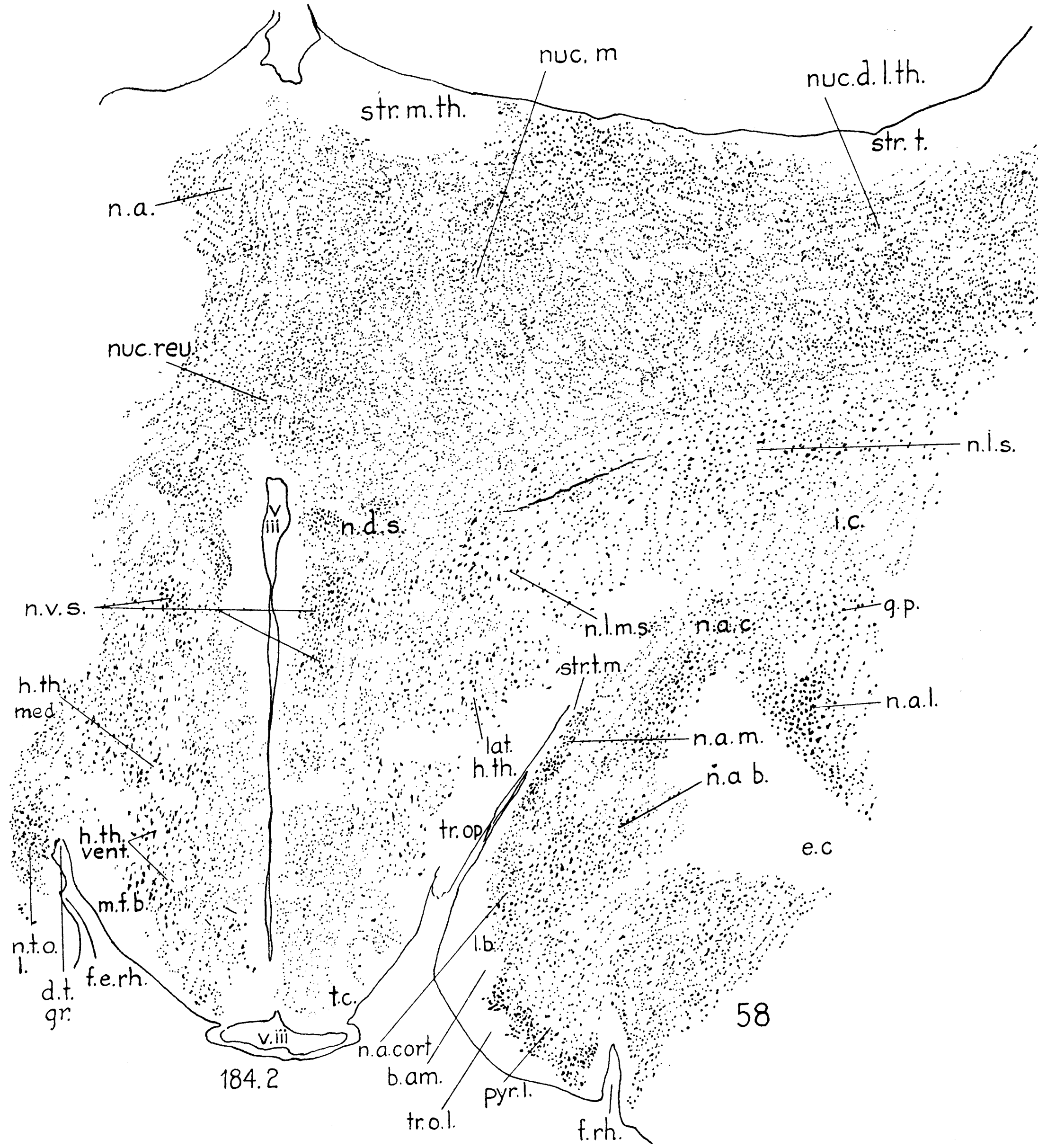
nuc. m
nuc. d. l. th.
str. m. th.
str. t.
n. a.
nuc. reu.
n. l. s.
v iii
n. d. s.
i. c.
n. v. s.
g. p.
n. l. m. s.
n. a. c.
str. t. m.
n. a. l.
h. th. med.
lat. h. th.
n. a. m.
n. a b.
tr. op.
h. th. vent.
e. c
m. f. b.
l. b.
n. t. o. l.
d. t. gr.
f. e. rh.
t. c.
v. iii
n. a. cort.
b. am.
pyr. l.
tr. o. l.
f. rh.
184. 2

58

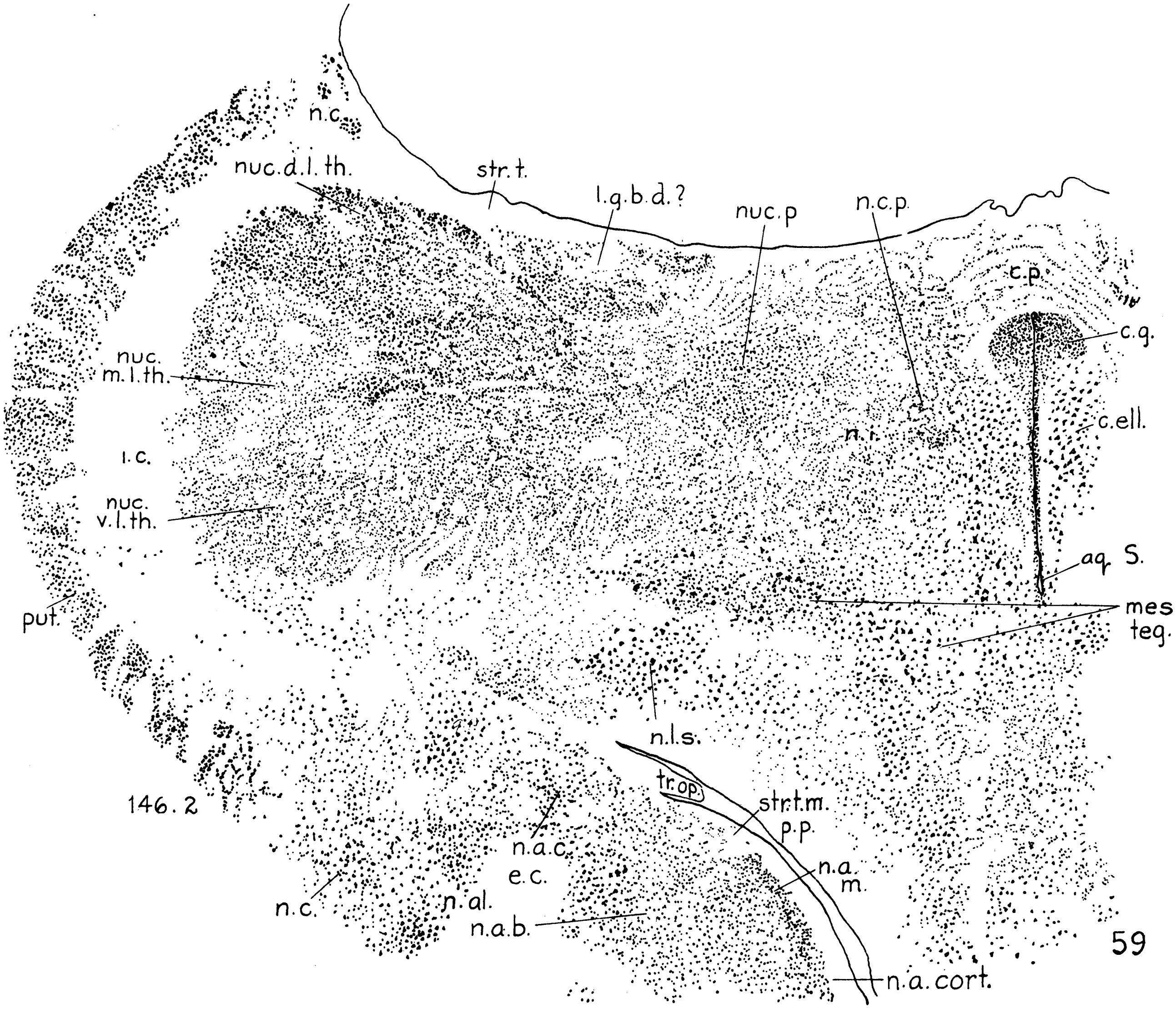
n.c.
nuc.d.l.th.
str.t.
l.q.b.d.?
nuc.p
n.c.p.
c.p.
c.q.
nuc.
m.l.th.
c.ell.
n.r.
l.c.
nuc.
v.l.th.
aq. S.
put.
mes
teg.
n.l.s.
tr.op.
146.2
str.t.m.
p.p.
n.a.c.
e.c.
n.a.
m.
n.c.
n.al.
n.a.b.
n.a.cort.

59

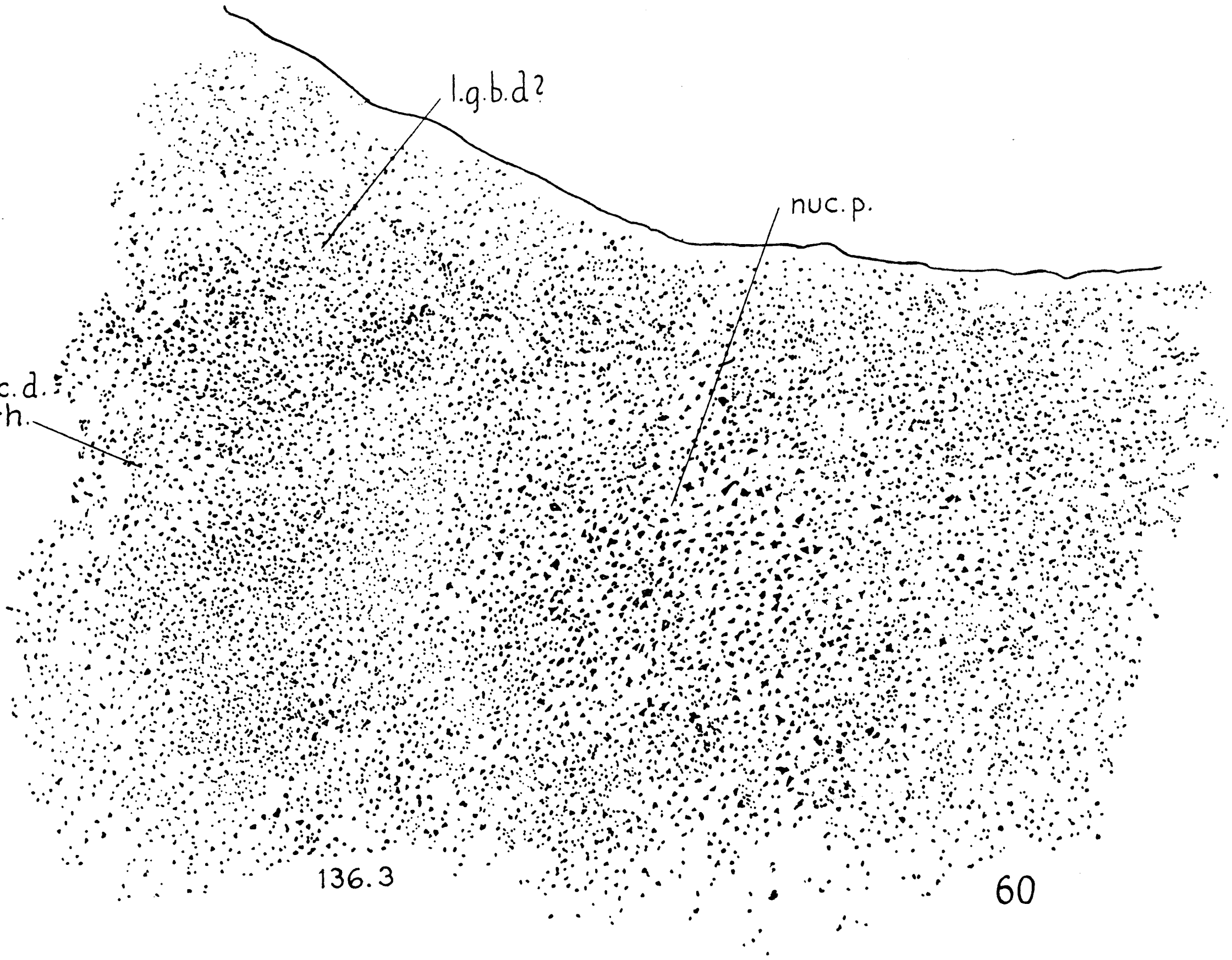
l.g.b.d?
nuc.p.
nuc.d.
l.th.
136.3

60


l.g.b.d.?
nuc.p.
c.s.
s.g.s.
s.g.m.
s.g.p.
s.g.per.
n.i.
n.m.v.l.
130.2

61

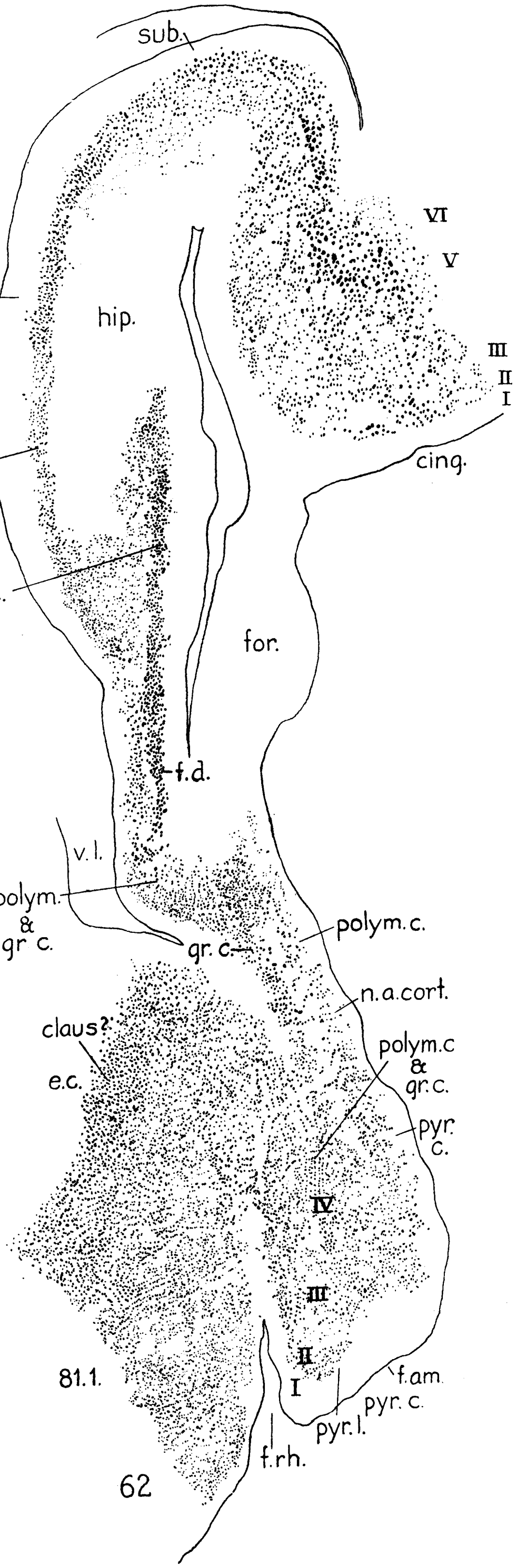

62

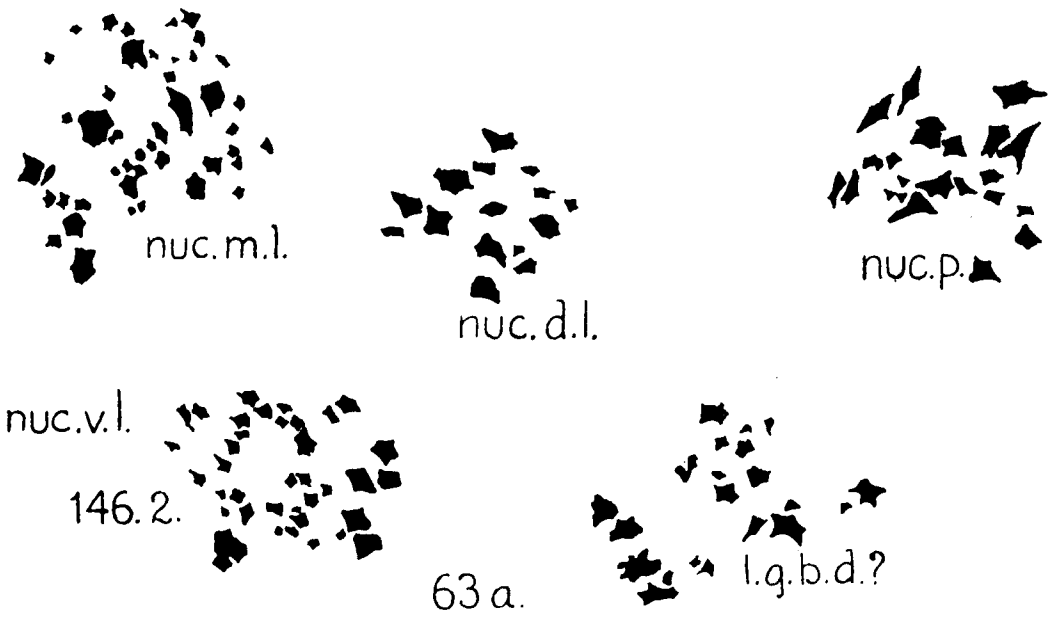

63 a.



63 b.

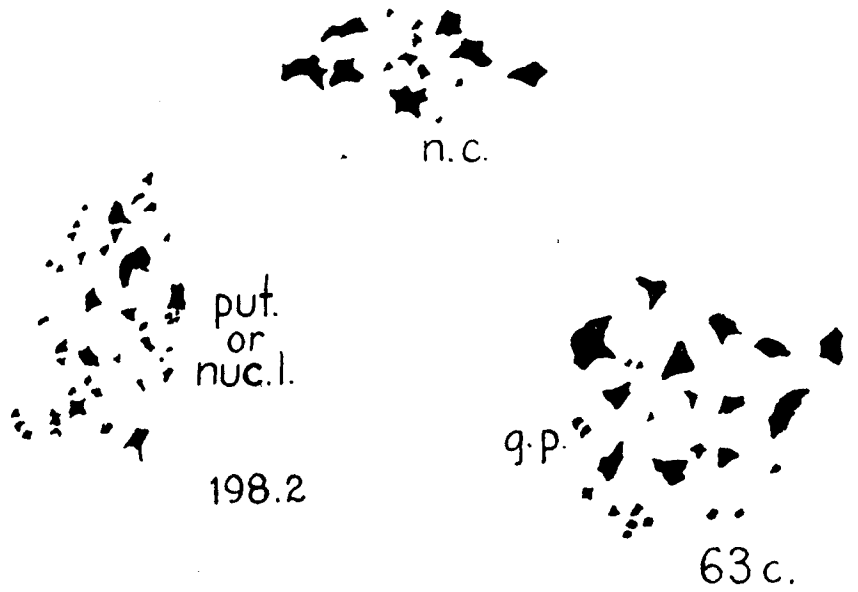

63 c.


n.d.s.
184.2
n.l.s.
n.v.s.
n.l.m.s.

64a

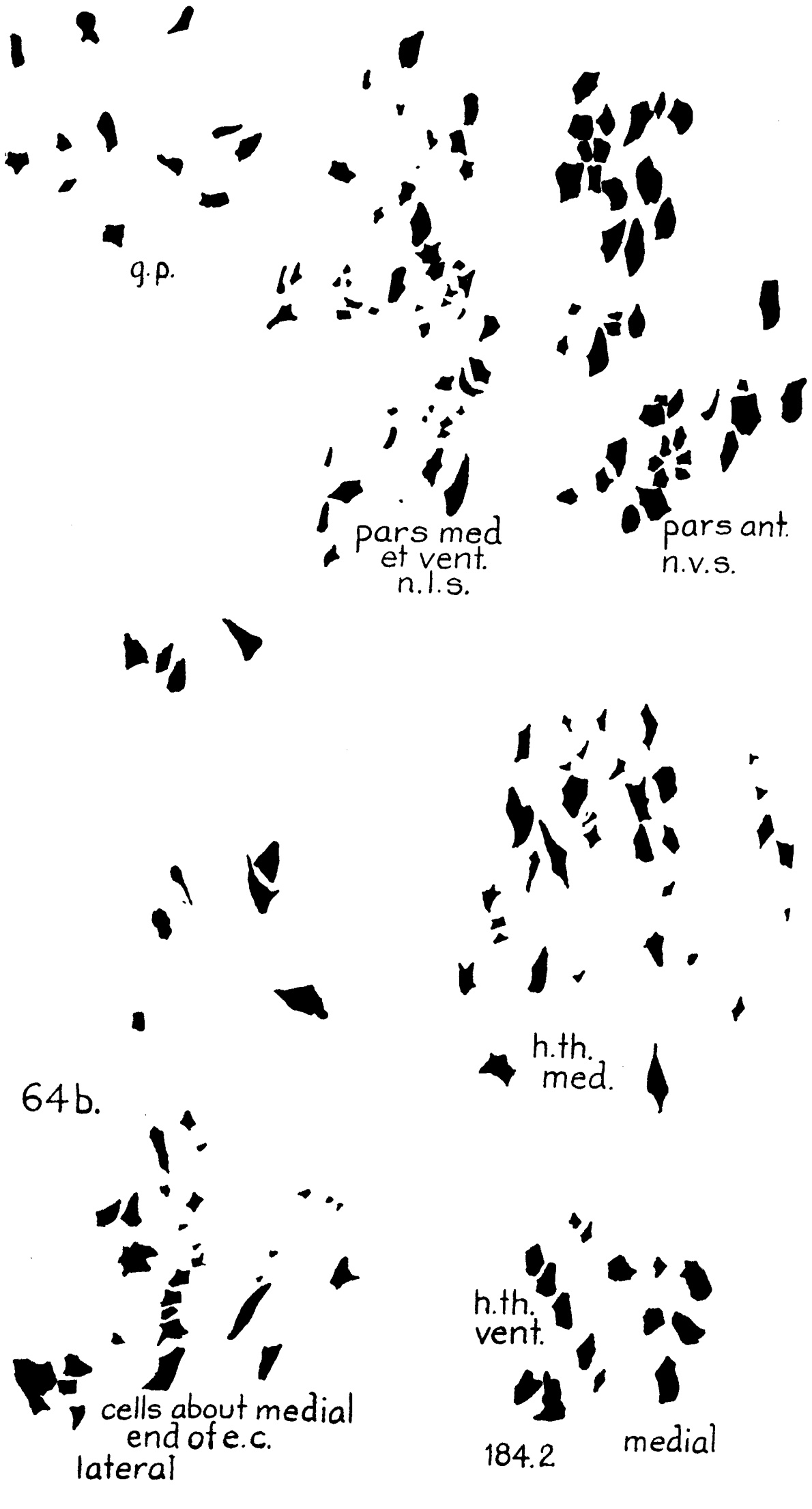
g.p.
pars med
et vent.
n.l.s.
pars ant.
n.v.s.
h.th.
med.
h.th.
vent.
184.2
medial
cells about medial
end of e.c.
lateral

64b.

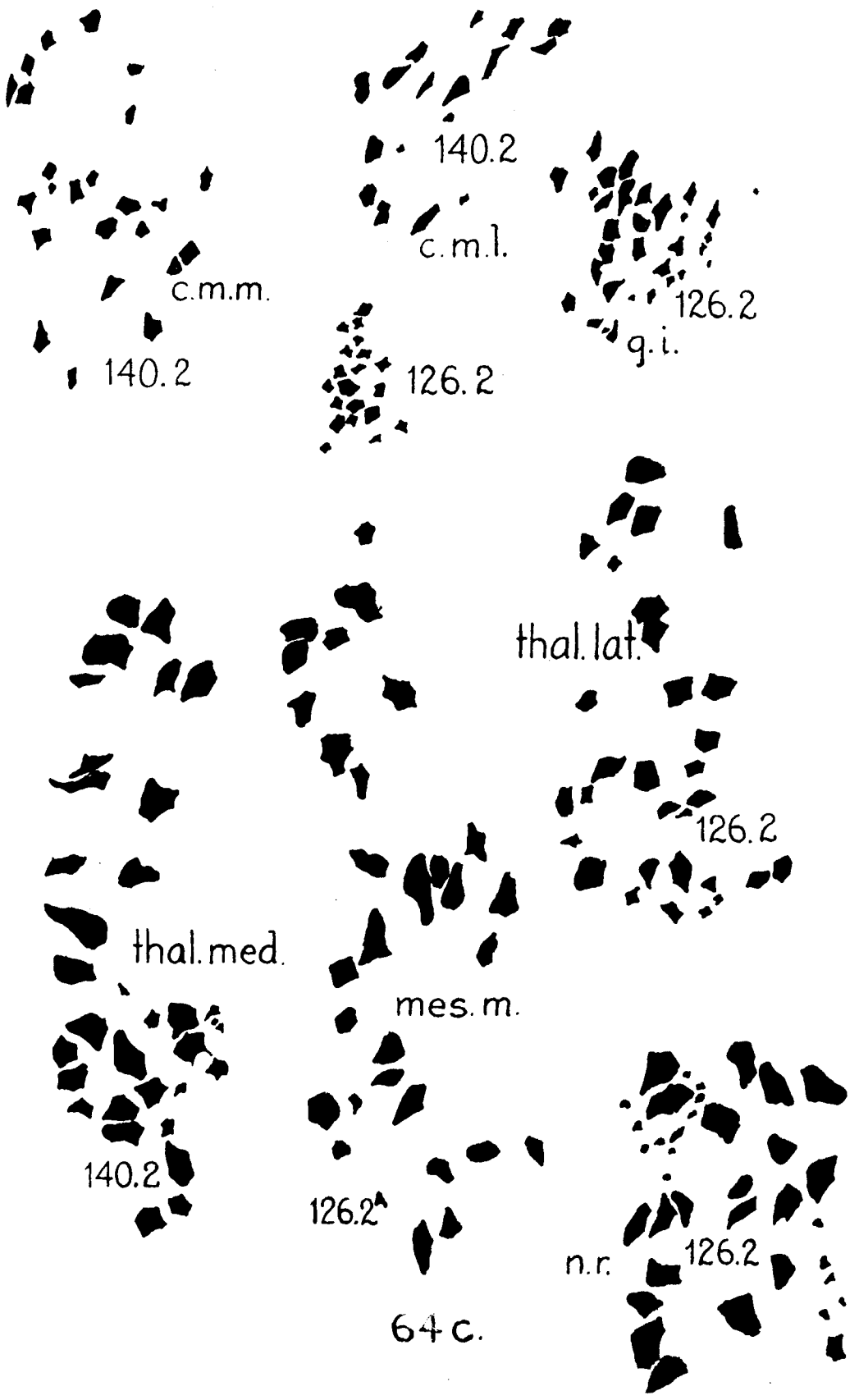
c.m.m.
140.2
140.2
c.m.l.
126.2
126.2
q.i.
thal. lat.
126.2
thal. med.
mes. m.
140.2
126.2
n.r.
126.2

64c.


nuc.c.str.
82.2
n.d.str.t.
201.2
nuc.str.t.
113.1
201.2
nuc.a.c.
n.a.c.
184.2
201.2
n.c.
n.a.s.
n.a.l.
184.2
n.a.cort.
113.1
184.2
n.a.m.
184.2.
n.a.b.
184.2
nuc.tr.o.l.
126.2
n.a.b.

65

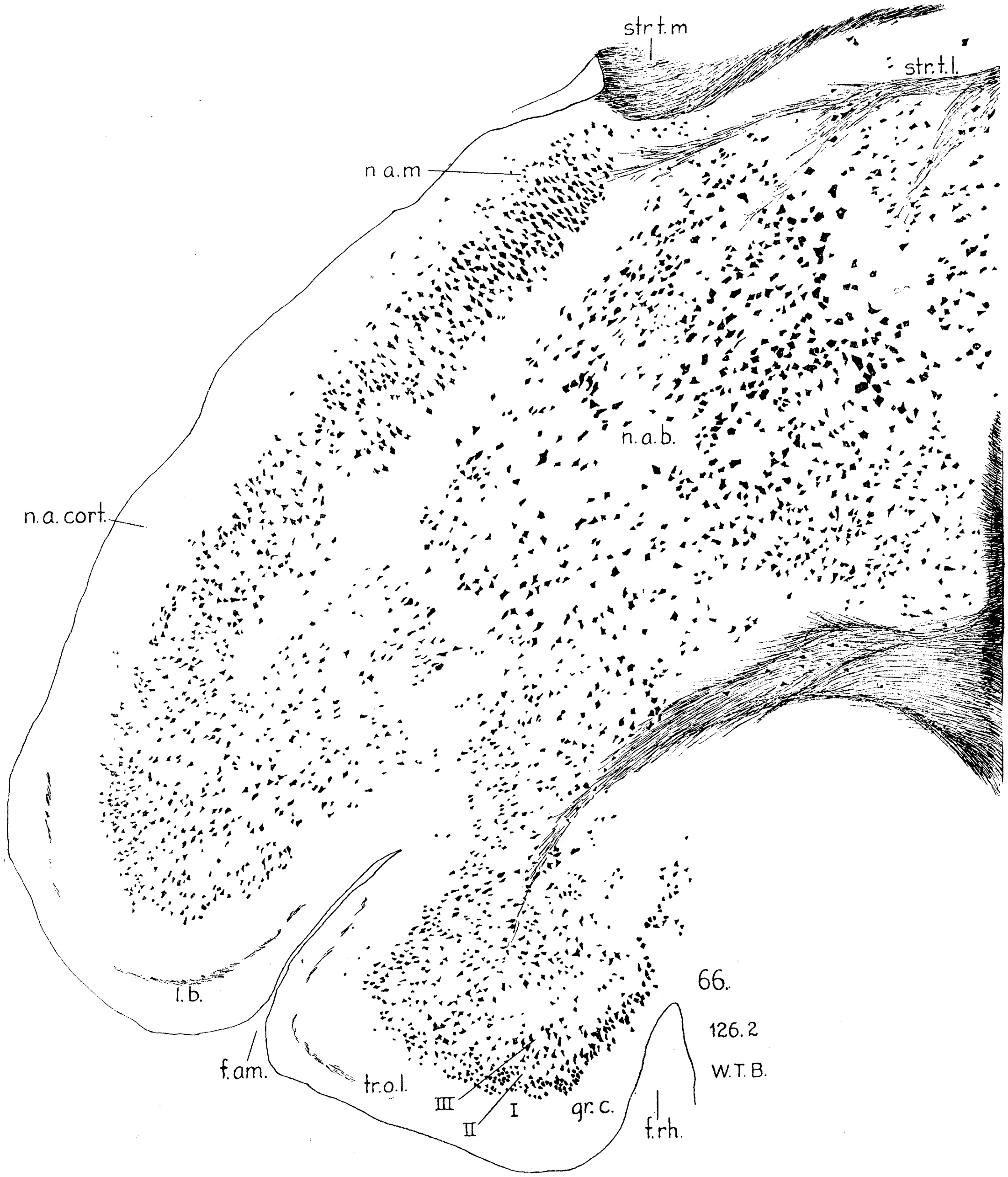
str.t.m
str.t.l.
n.a.m
n.a.b.
n.a.cort.
l.b.
f.am.
tr.o.l.
III
II
I
gr.c.
f.rh.
66.
126.2
W.T.B.

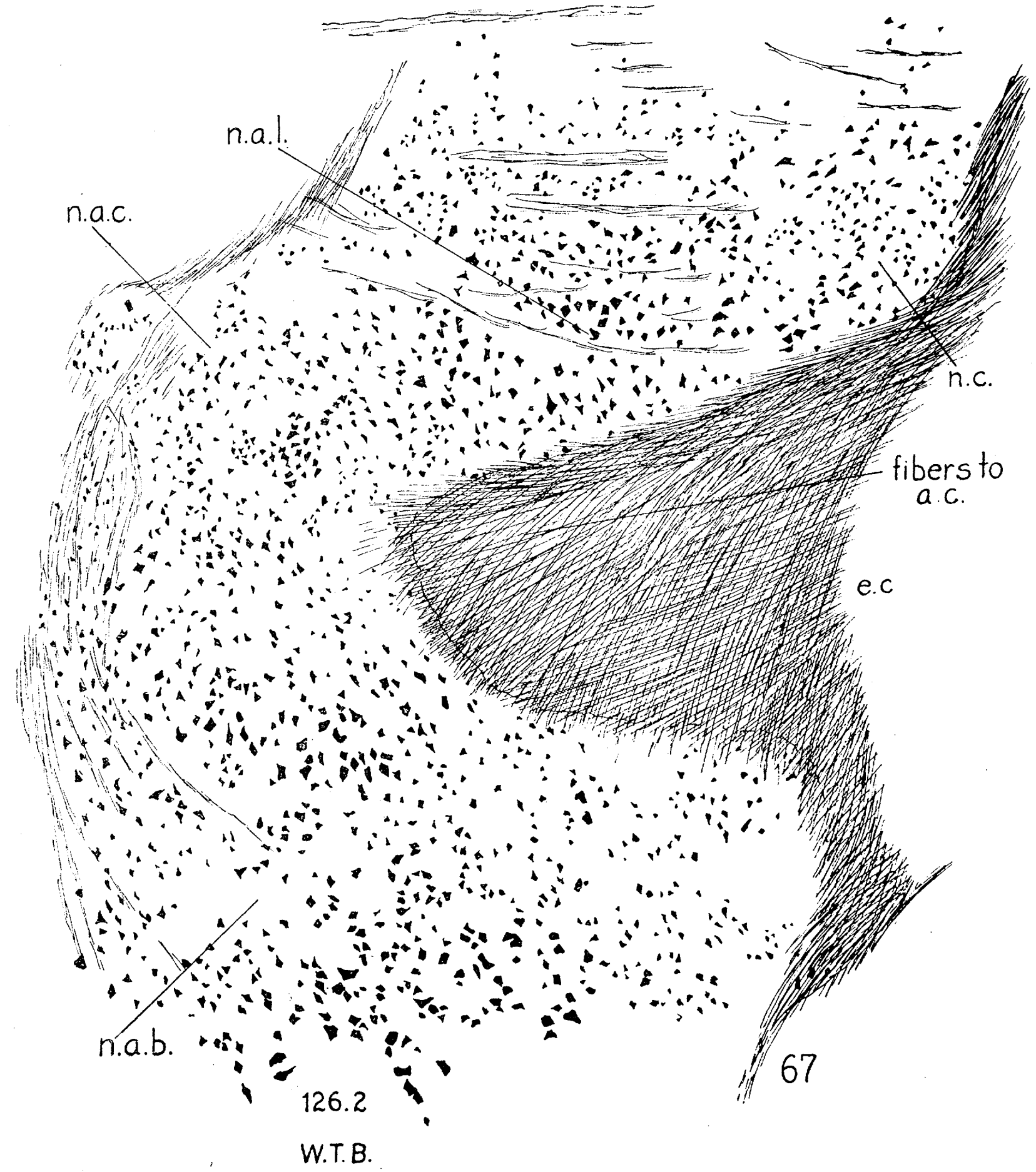
n.a.l.
n.a.c.
n.c.
fibers to a.c.
e.c
n.a.b.
126.2
W.T.B.

67

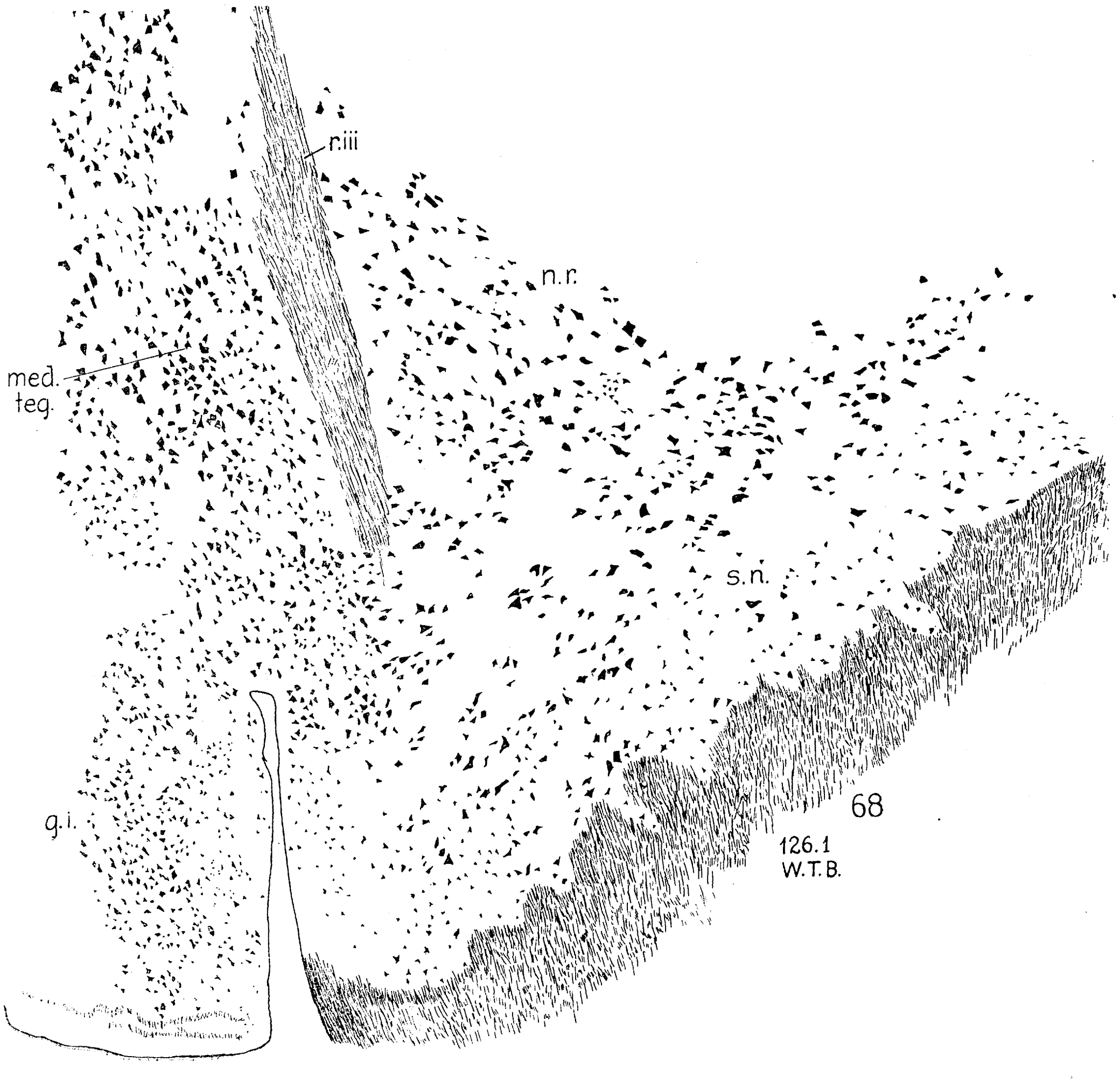
n.iii
n.r.
med. teg.
s.n.
g.i.
126.1
W.T.B.

68

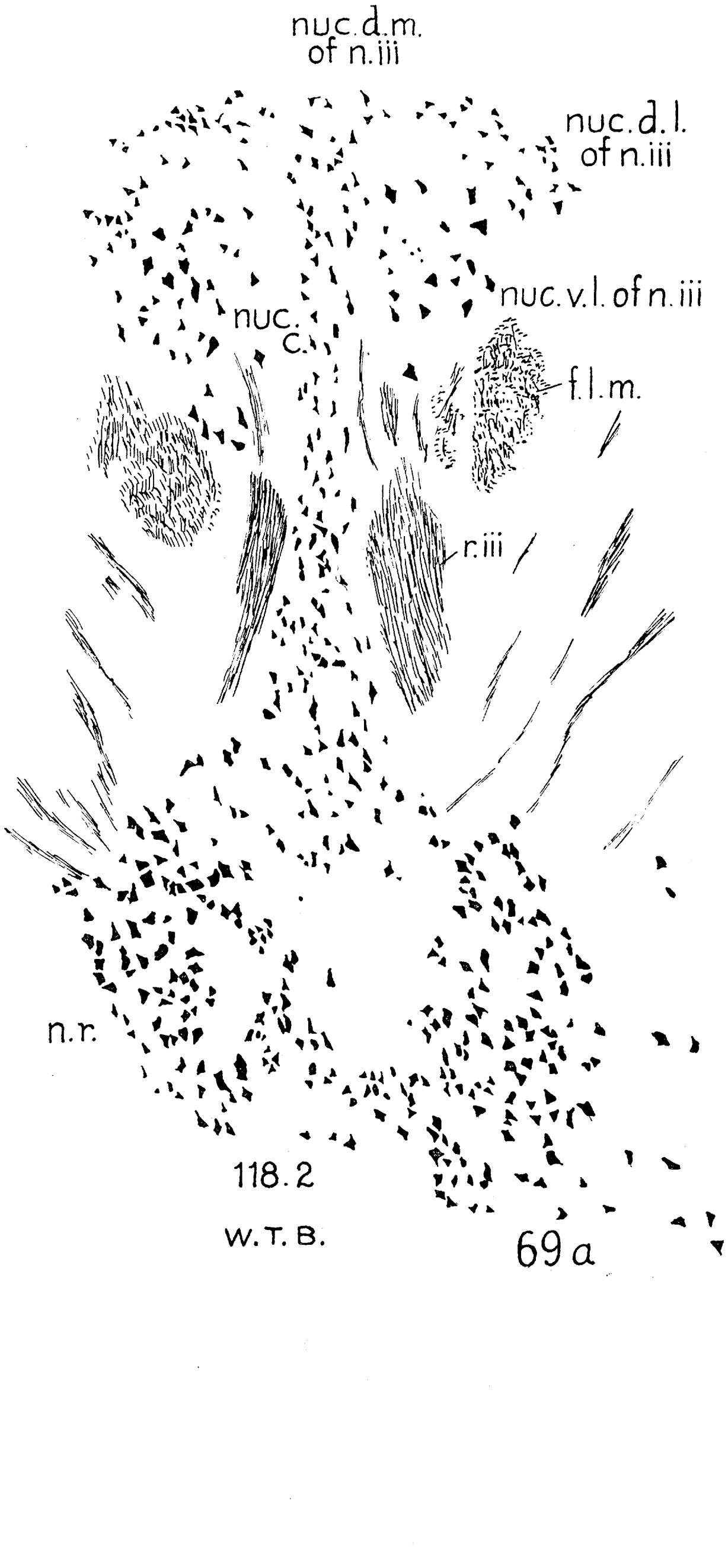
nuc. d.m. of n.iii
nuc. d. l. of n.iii
nuc. v. l. of n. iii
nuc. c.
f. l. m.
r. iii
n. r.
118. 2
W. T. B.

69 *a*

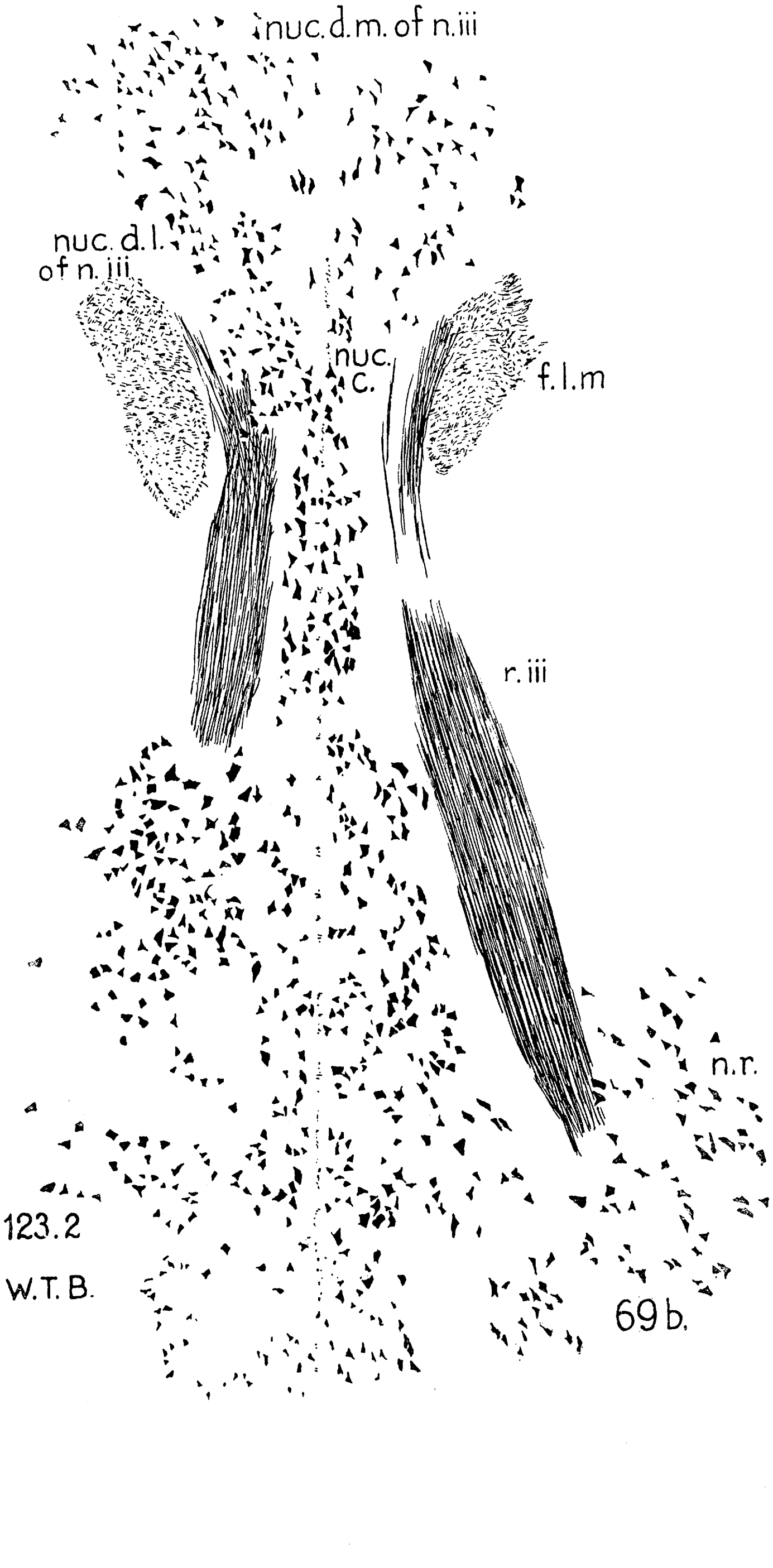
nuc. d.m. of n. iii
nuc. d. l. of n. iii
nuc. c.
f. l. m
r. iii
n. r.
123. 2
W. T. B.

69 b.

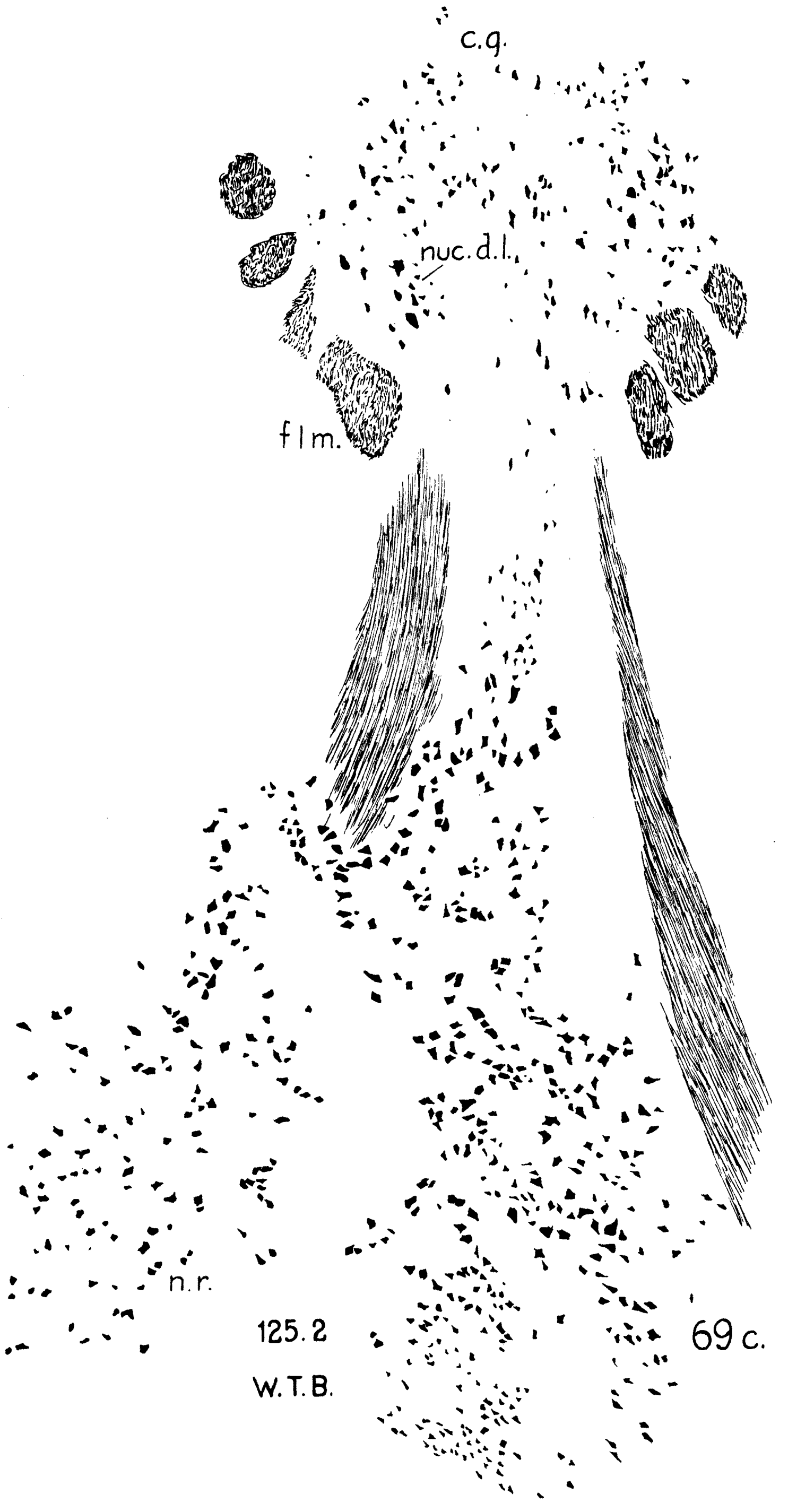

69 c.

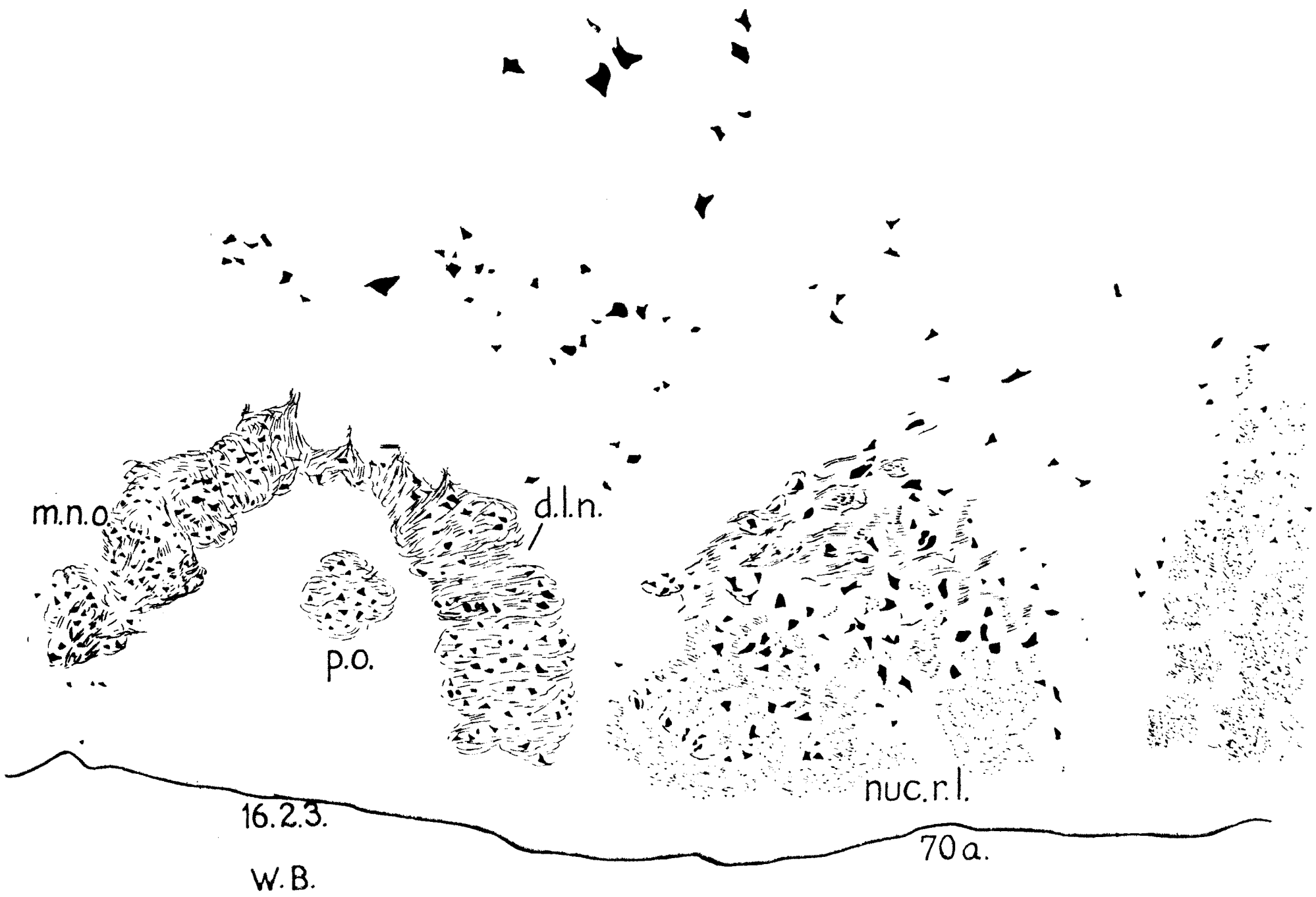

70 a.

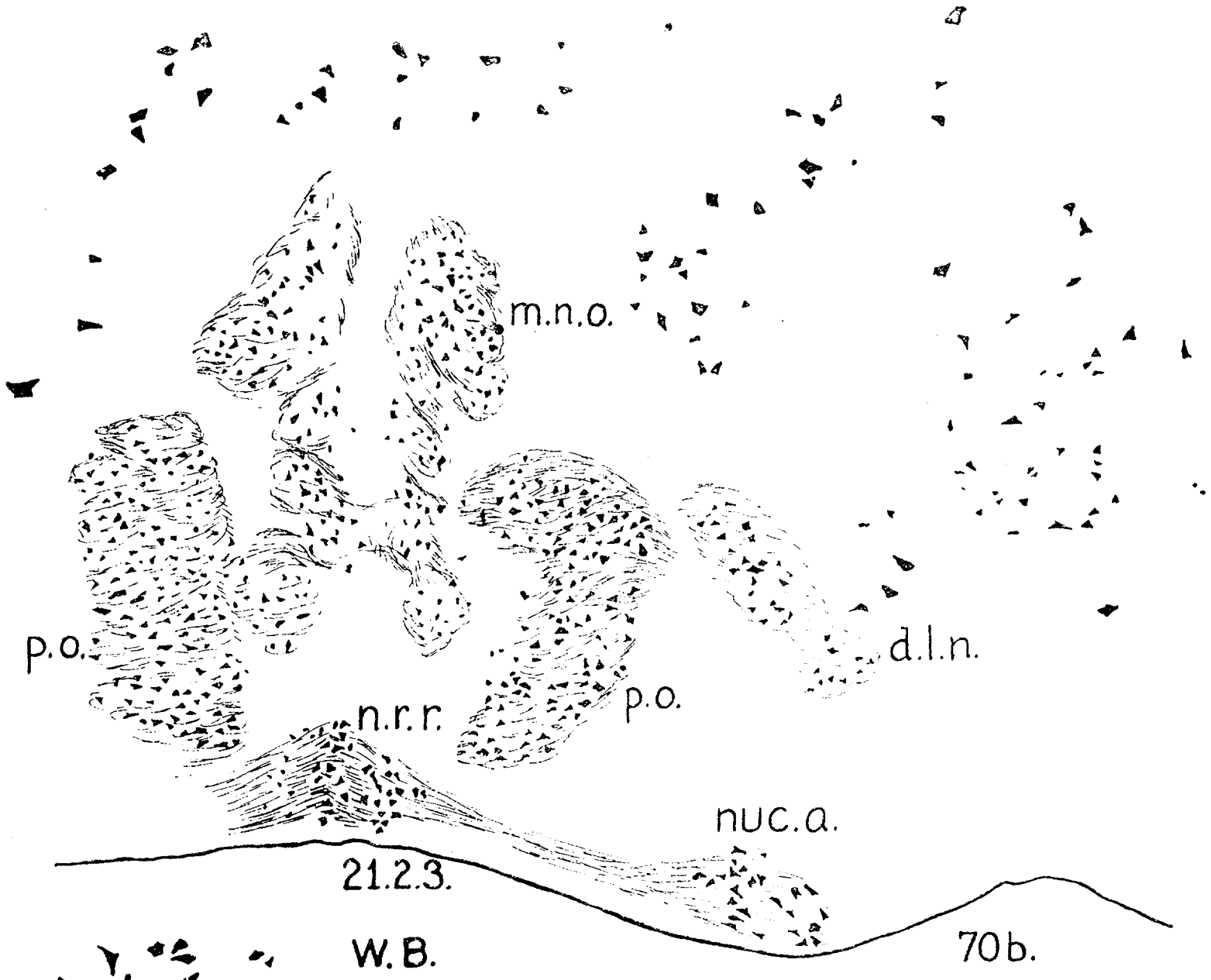
m.n.o.
p.o.
p.o.
d.l.n.
n.r.r.
nuc.a.
21.2.3.
W.B.

70b.

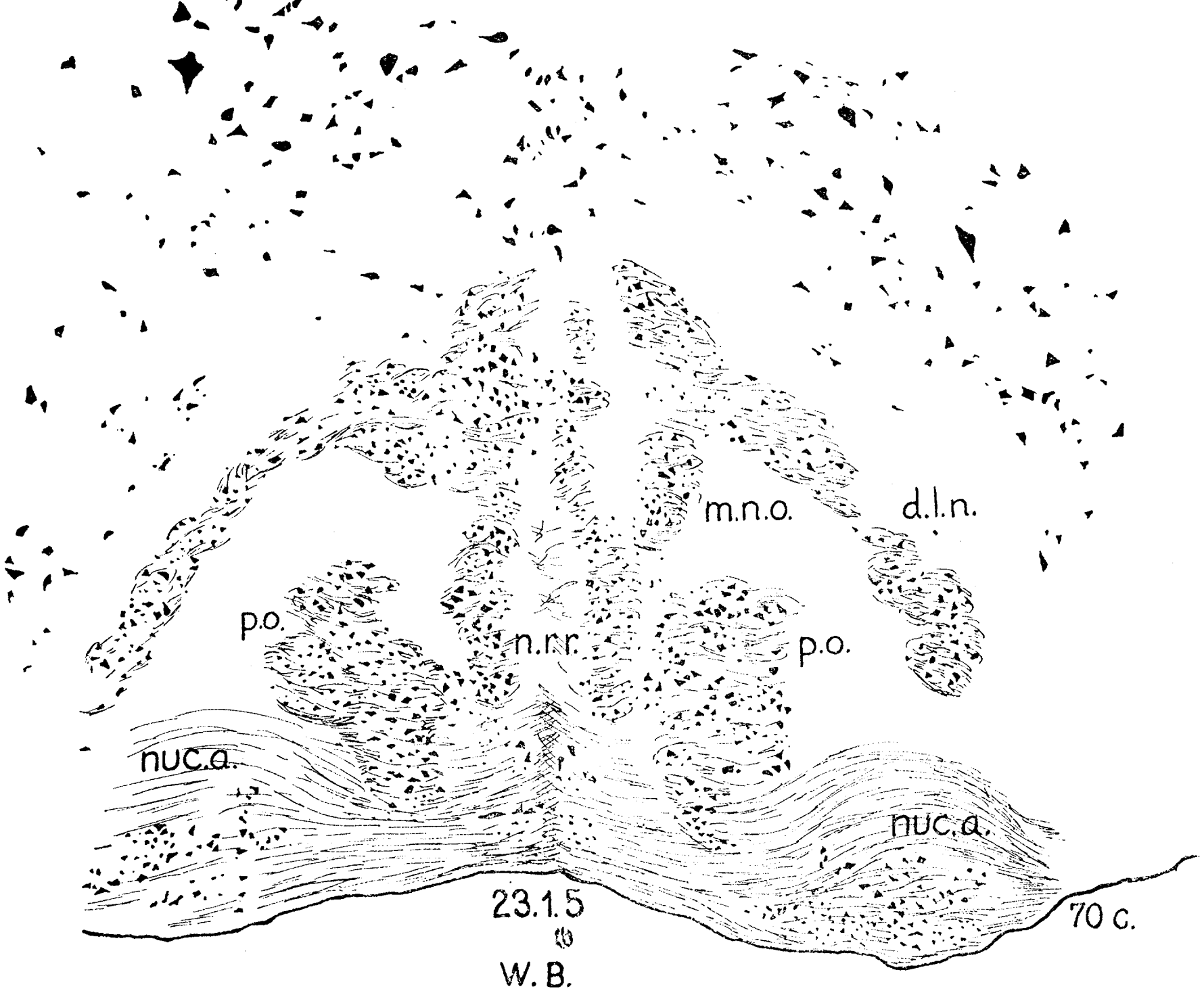
m.n.o.
d.l.n.
p.o.
n.r.r.
p.o.
nuc.a.
nuc.a.
23.1.5
W.B.

70 c.

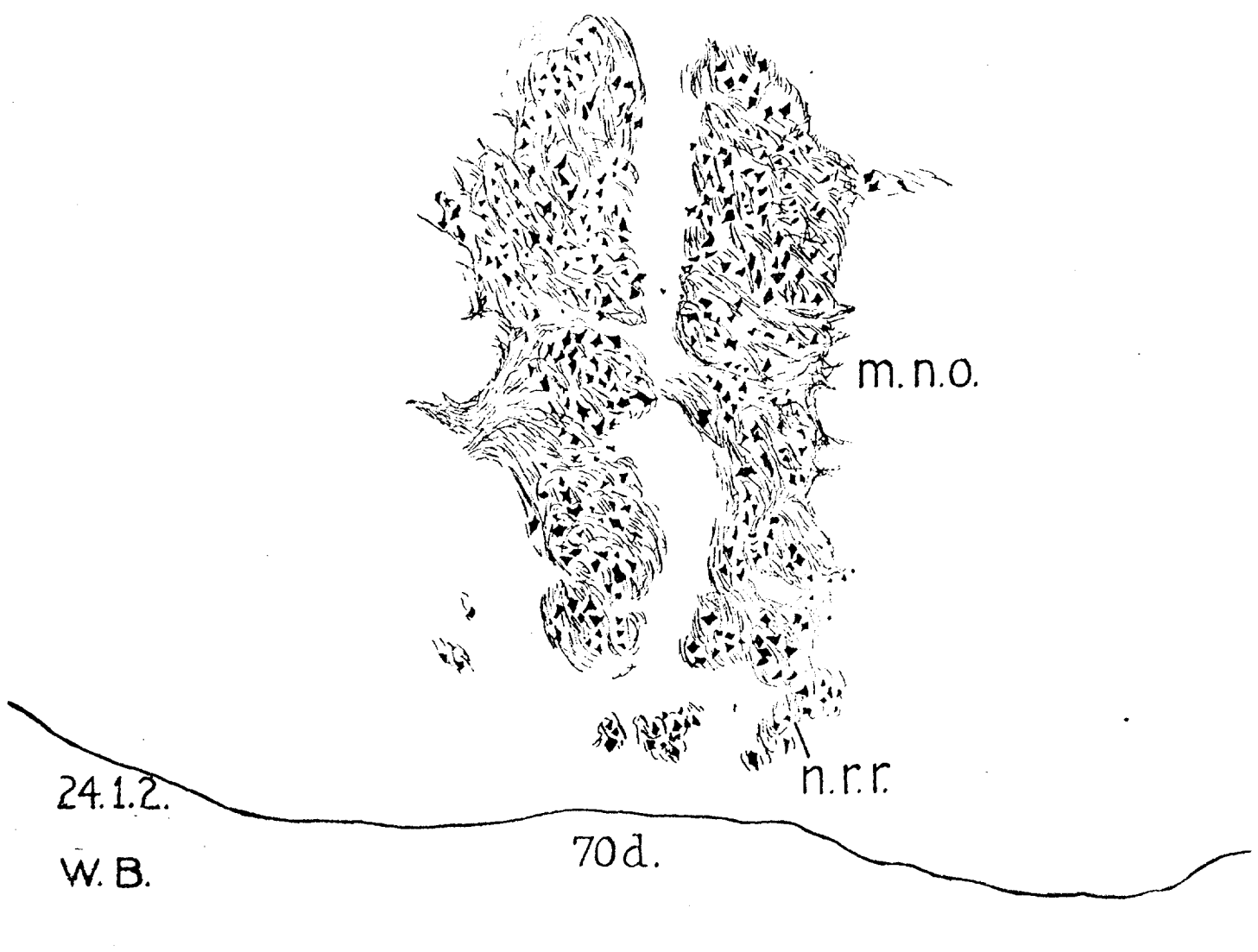
m.n.o.
n.r.r.
24.1.2.
W.B.

70d.

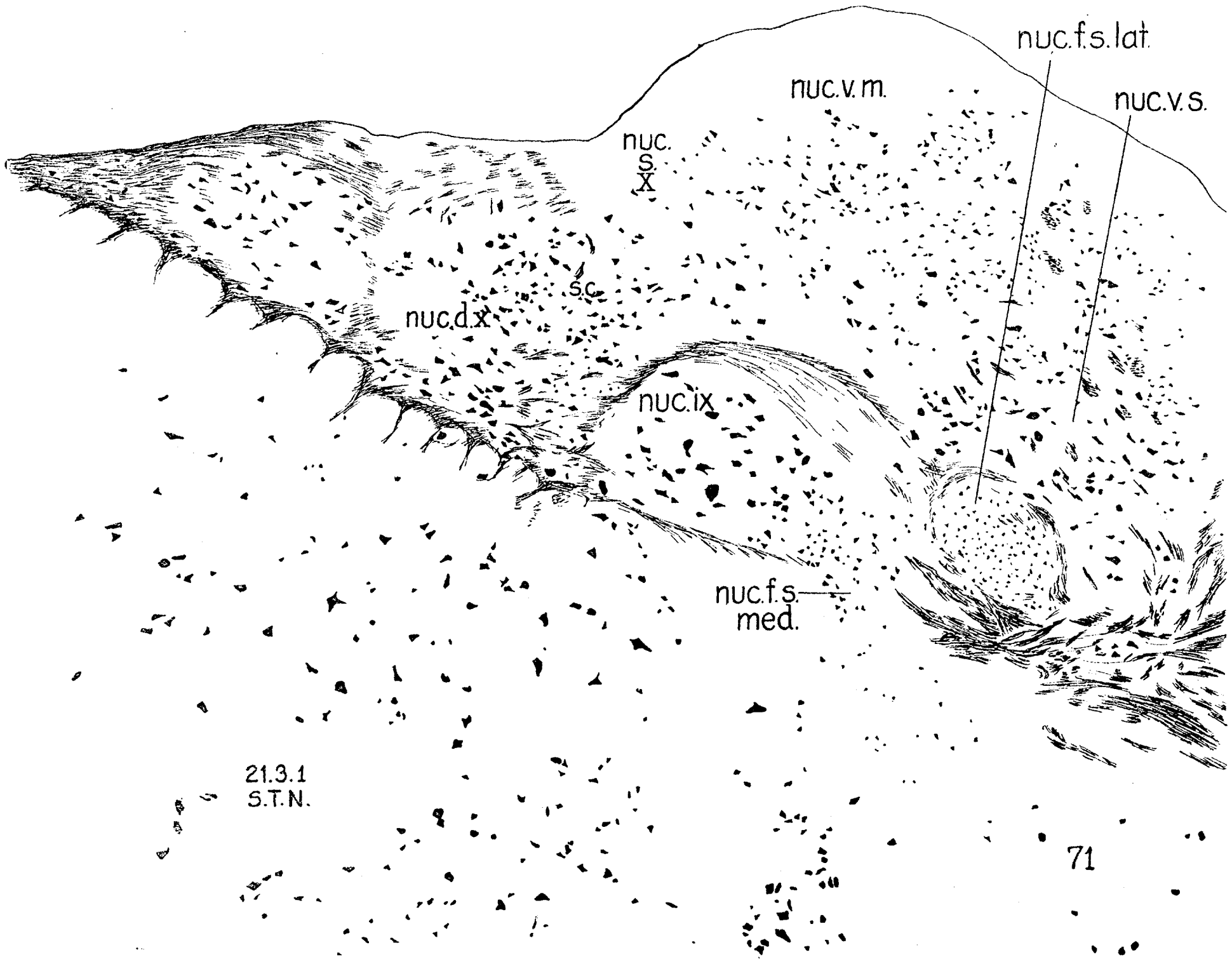
nuc.f.s.lat.
nuc.v.m.
nuc.v.s.
nuc. s. x
s.c.
nuc.d.x
nuc.ix
nuc.f.s. med.
21.3.1
S.T.N.

71

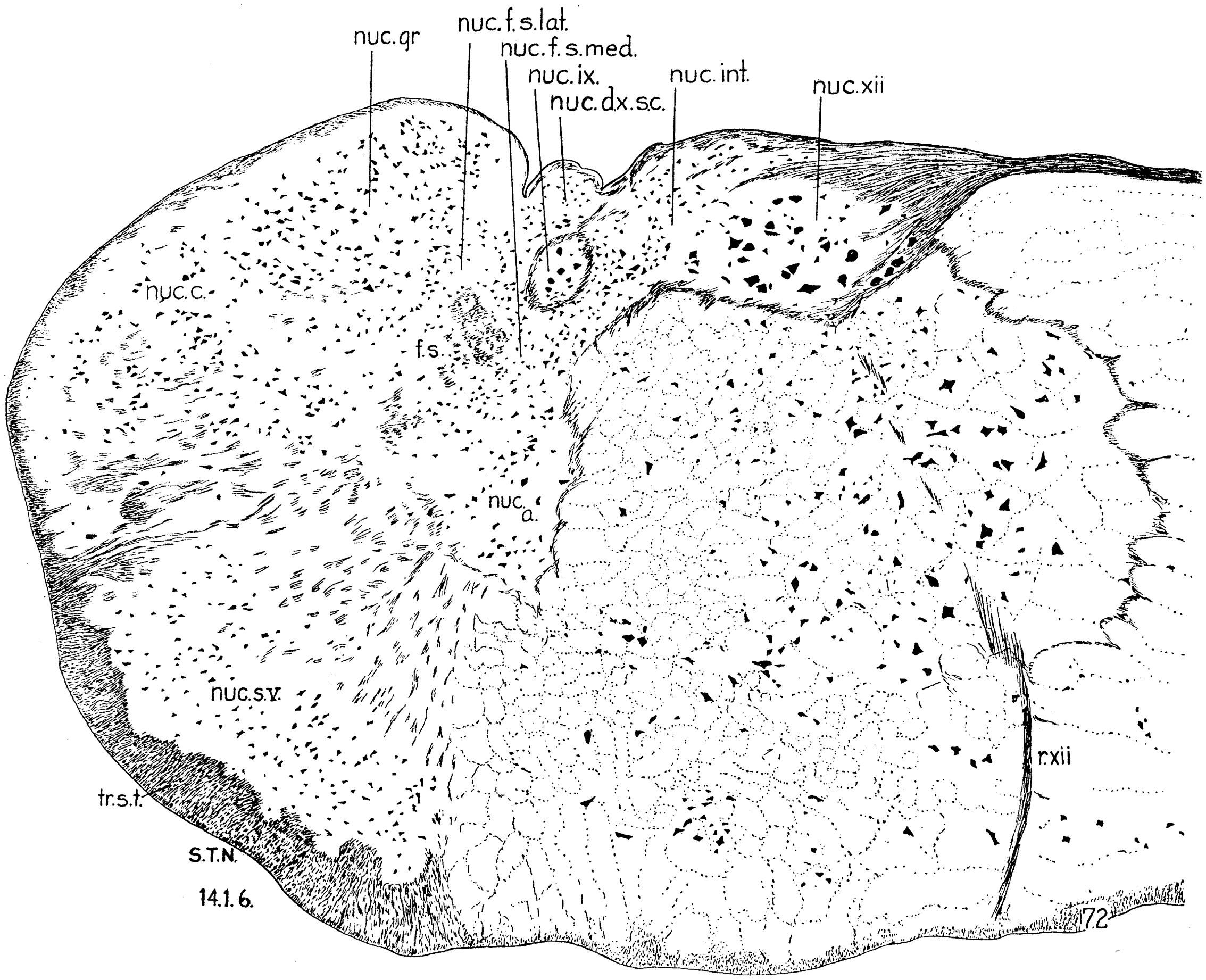
nuc.gr
nuc.f.s.lat.
nuc.f.s.med.
nuc.ix.
nuc.dx.s.c.
nuc.int.
nuc.xii
nuc.c.
f.s.
nuc.a.
nuc.s.v.
tr.s.t.
S.T.N.
14.1.6.
r.xii

72

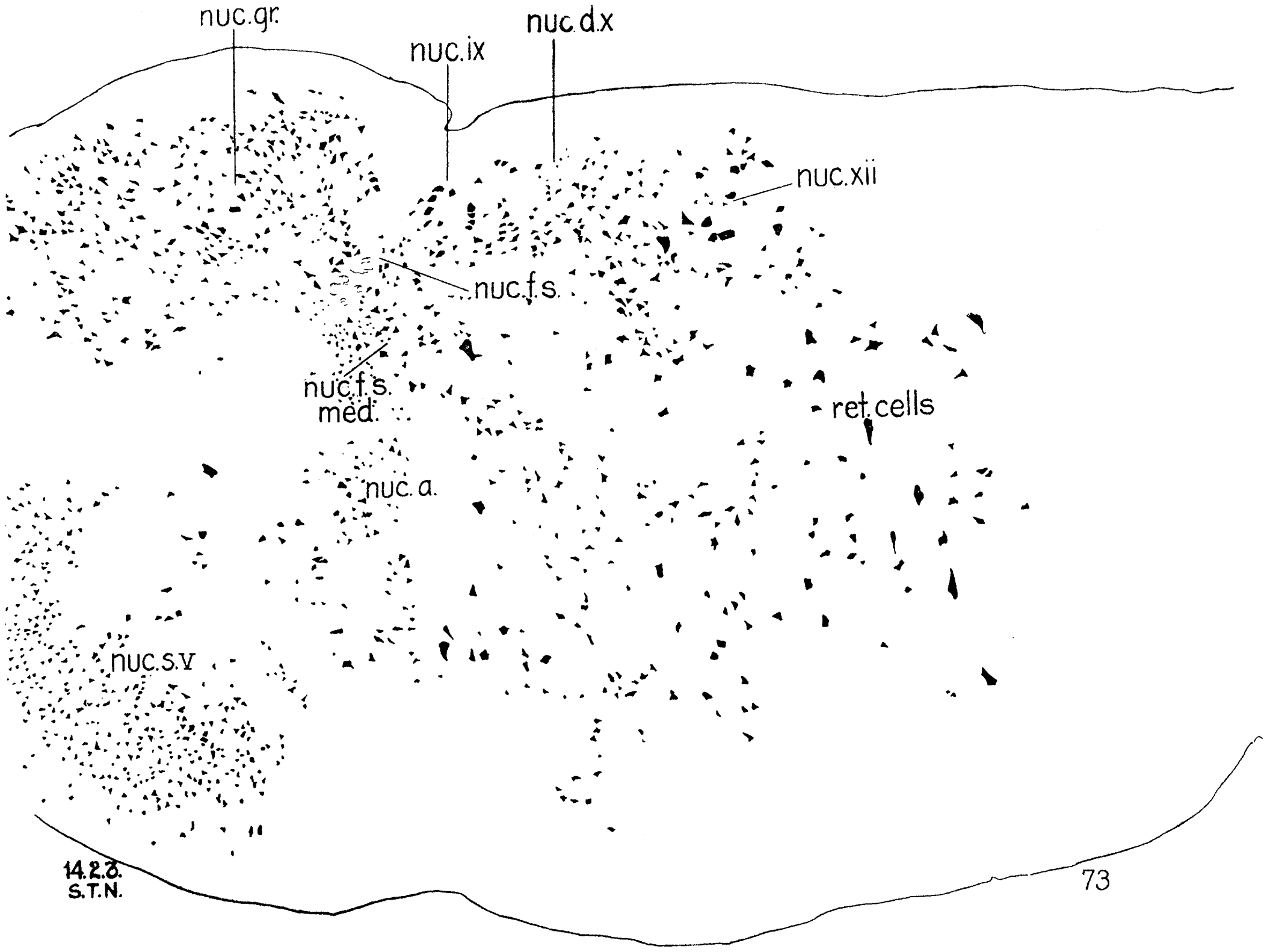
nuc.gr.
nuc.ix
nuc.d.x
nuc.xii
nuc.f.s.
nuc.f.s. med.
ret.cells
nuc.a.
nuc.s.V
14.2.3. S.T.N.

73


ret. cells.
nuc.s.V l.
nuc.s.V. m.
58.1.2. S.T.N.

74

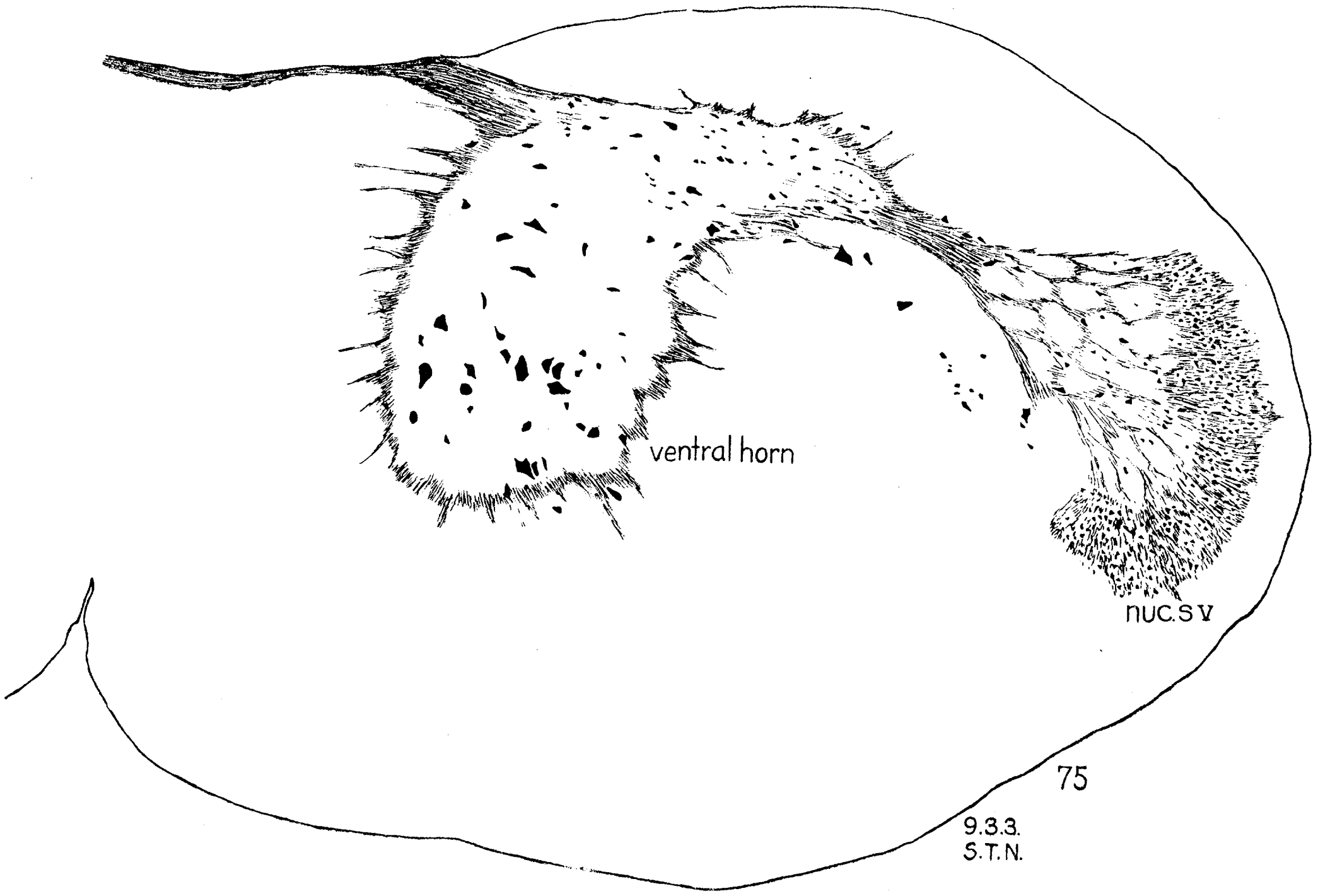
ventral horn
nuc.s V
9.3.3.
S.T.N.

75

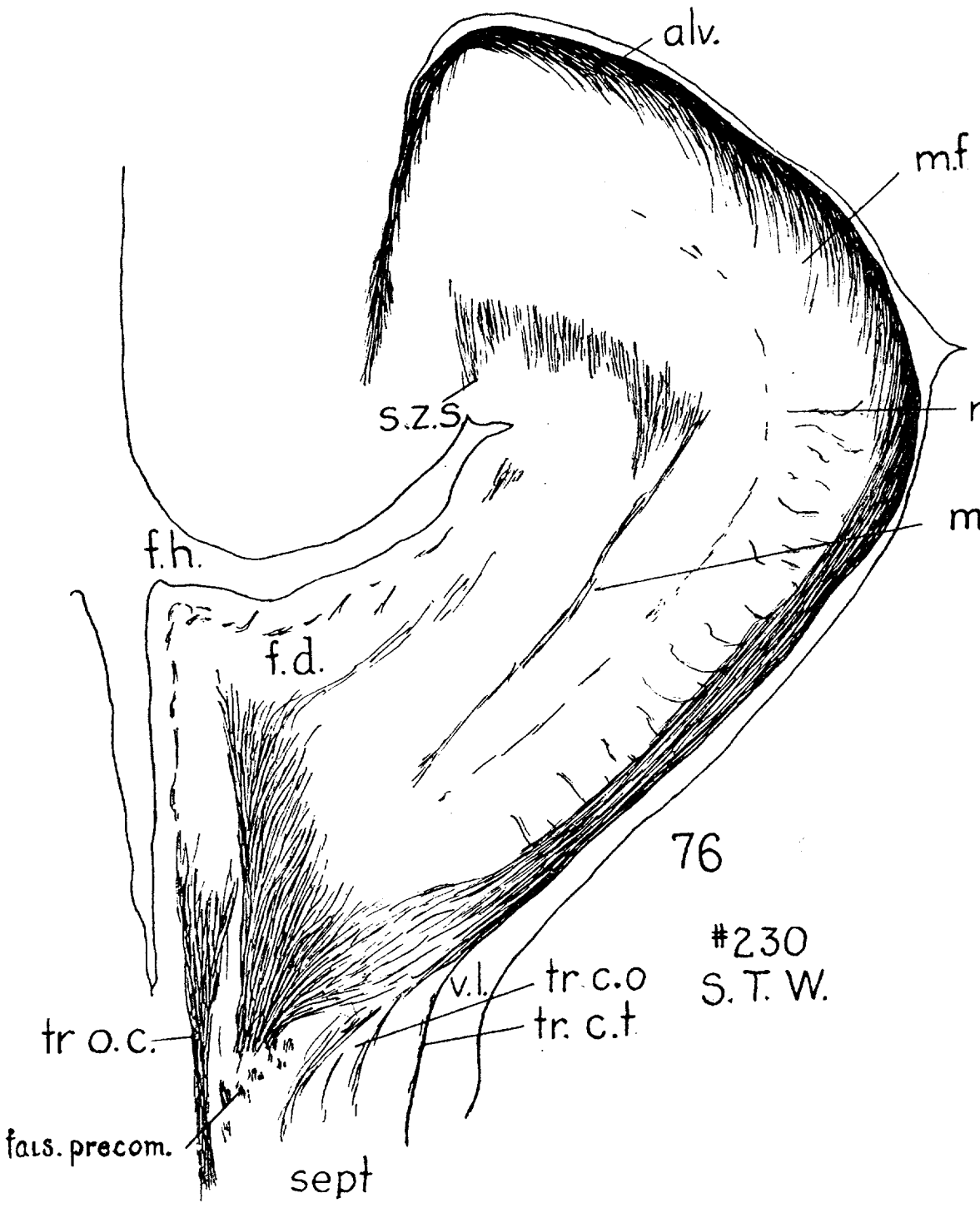
alv.
m.f o.b.
s.z.s.
m.f.d.b
m.f.m.b.
f.h.
f.d.
#230
S.T.W.
tr o.c.
v.l.
tr c.o
tr. c.t
fais. precom.
sept

76

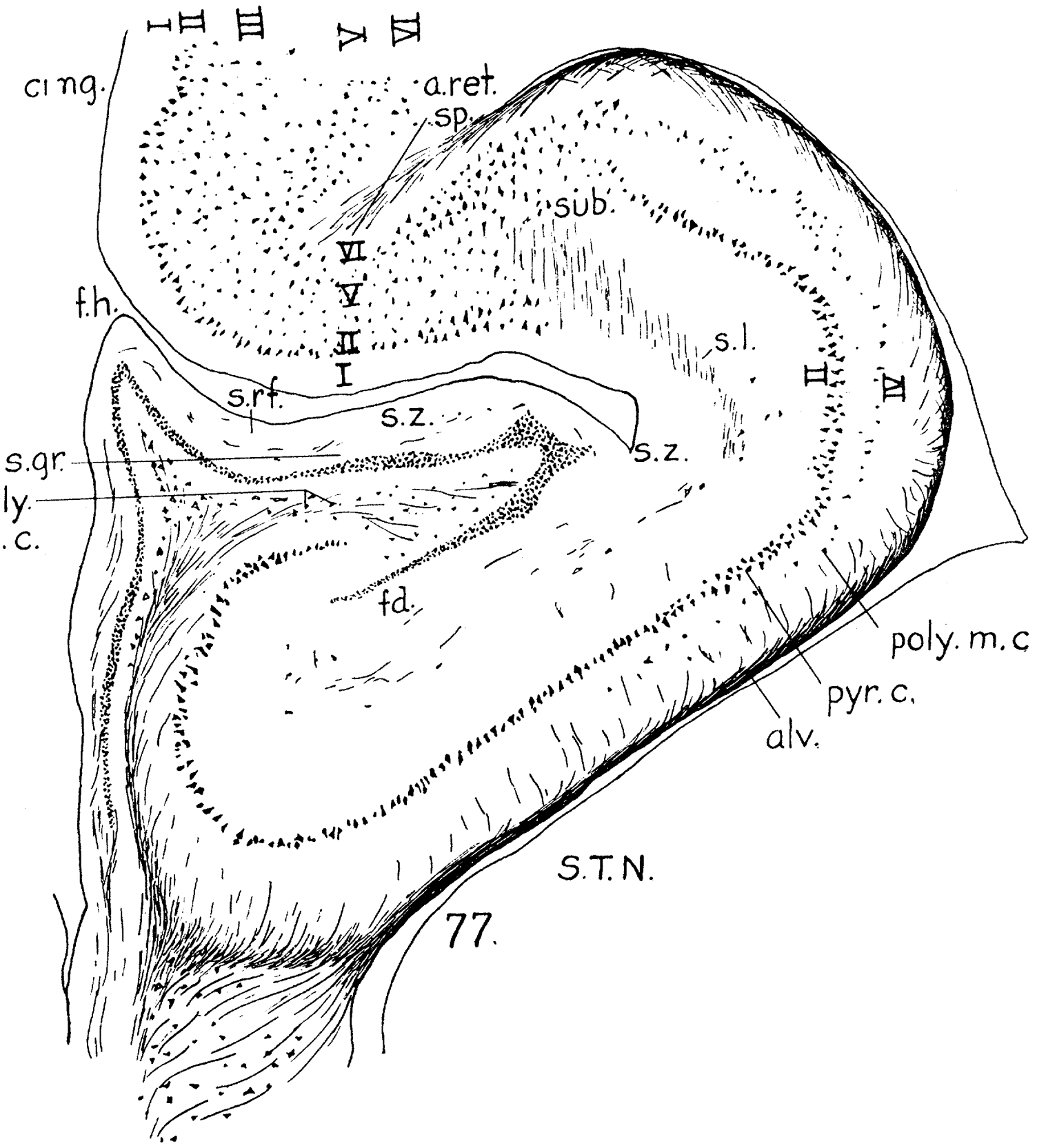
I
II
III
V
VI
cing.
a.ret.
sp.
sub.
VI
V
II
I
f.h.
s.rf.
s.z.
s.gr.
poly.
m.c.
s.z.
s.l.
II
VI
fd.
poly. m.c
pyr. c.
alv.
S.T.N.

77.

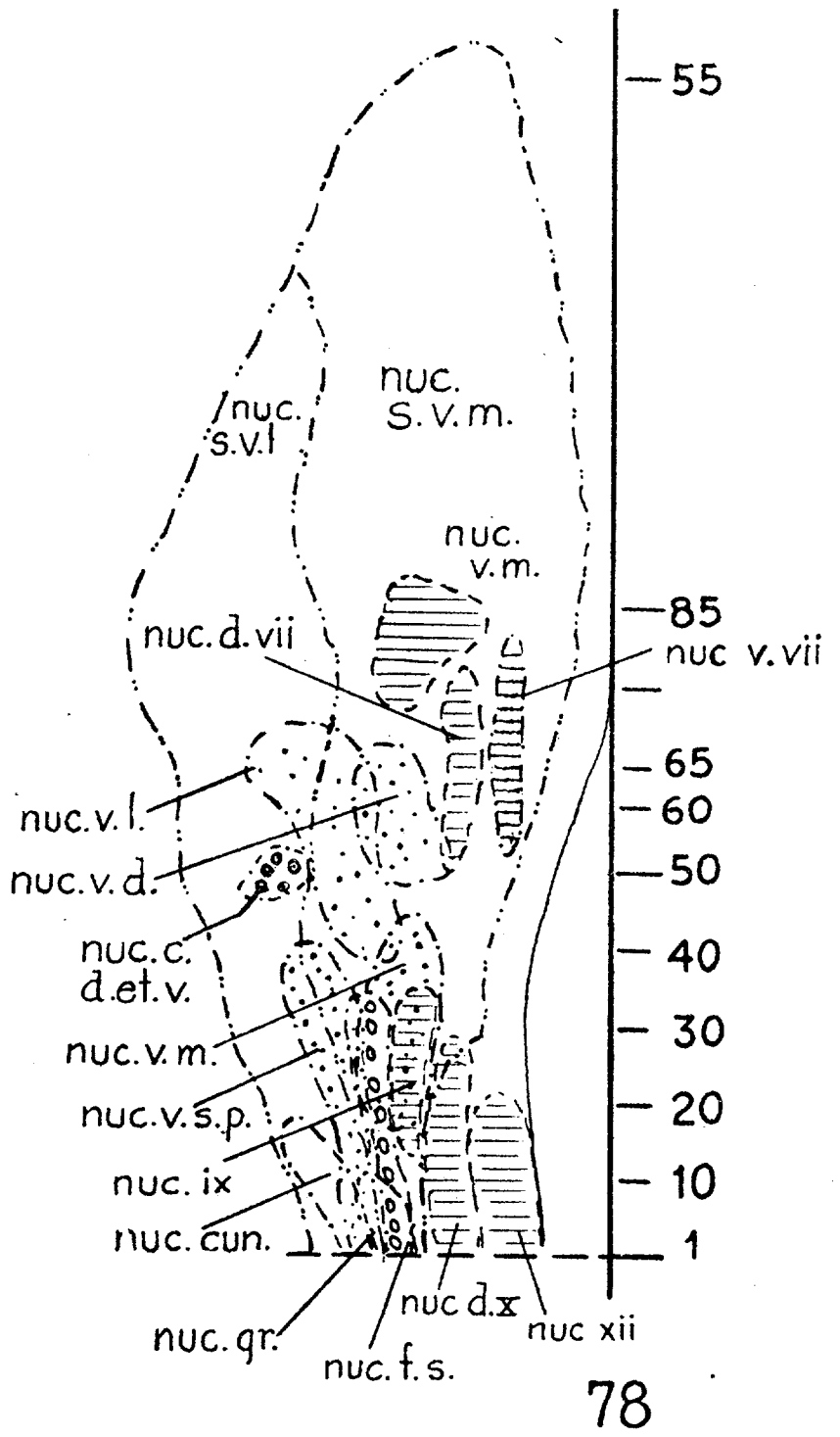
nuc. s.v.l
nuc. s.v.m.
nuc. v.m.
nuc. d. vii
nuc v. vii
nuc. v. l.
nuc. v. d.
nuc. c. d. et. v.
nuc. v. m.
nuc. v. s. p.
nuc. ix
nuc. cun.
nuc. gr.
nuc. f. s.
nuc d. x
nuc xii
55
85
65
60
50
40
30
20
10
1

78

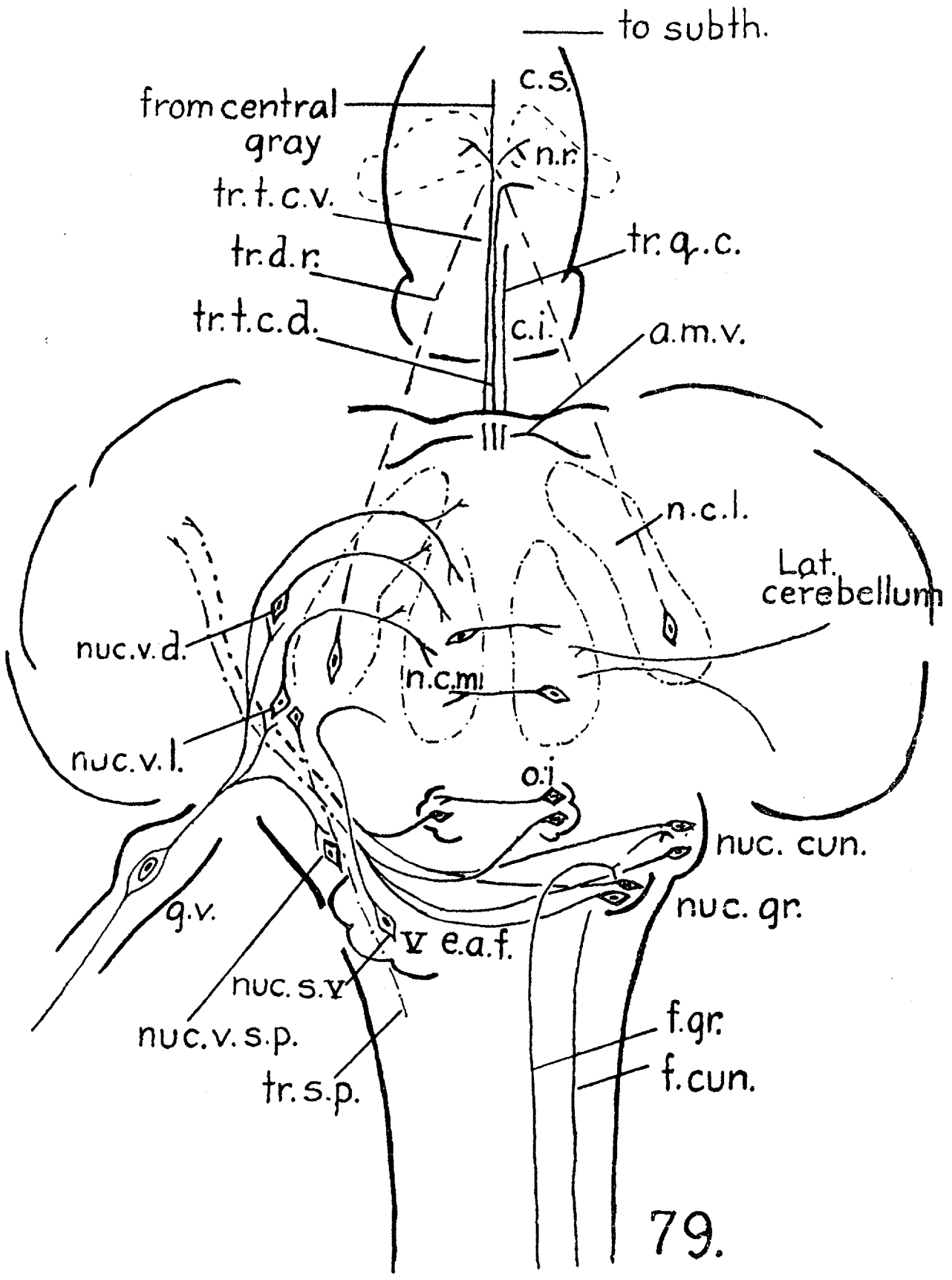
to subth.
c.s.
from central gray
n.r.
tr. t. c. v.
tr. d. r.
tr. q. c.
tr. t. c. d.
c.i.
a.m.v.
III
n.c.l.
Lat. cerebellum
nuc. v. d.
n.c.m.
nuc. v. l.
o.i.
nuc. cun.
nuc. gr.
g.v.
V e.a.f.
nuc. s. V
nuc. v. s. p.
tr. s. p.
f. gr.
f. cun.

79.

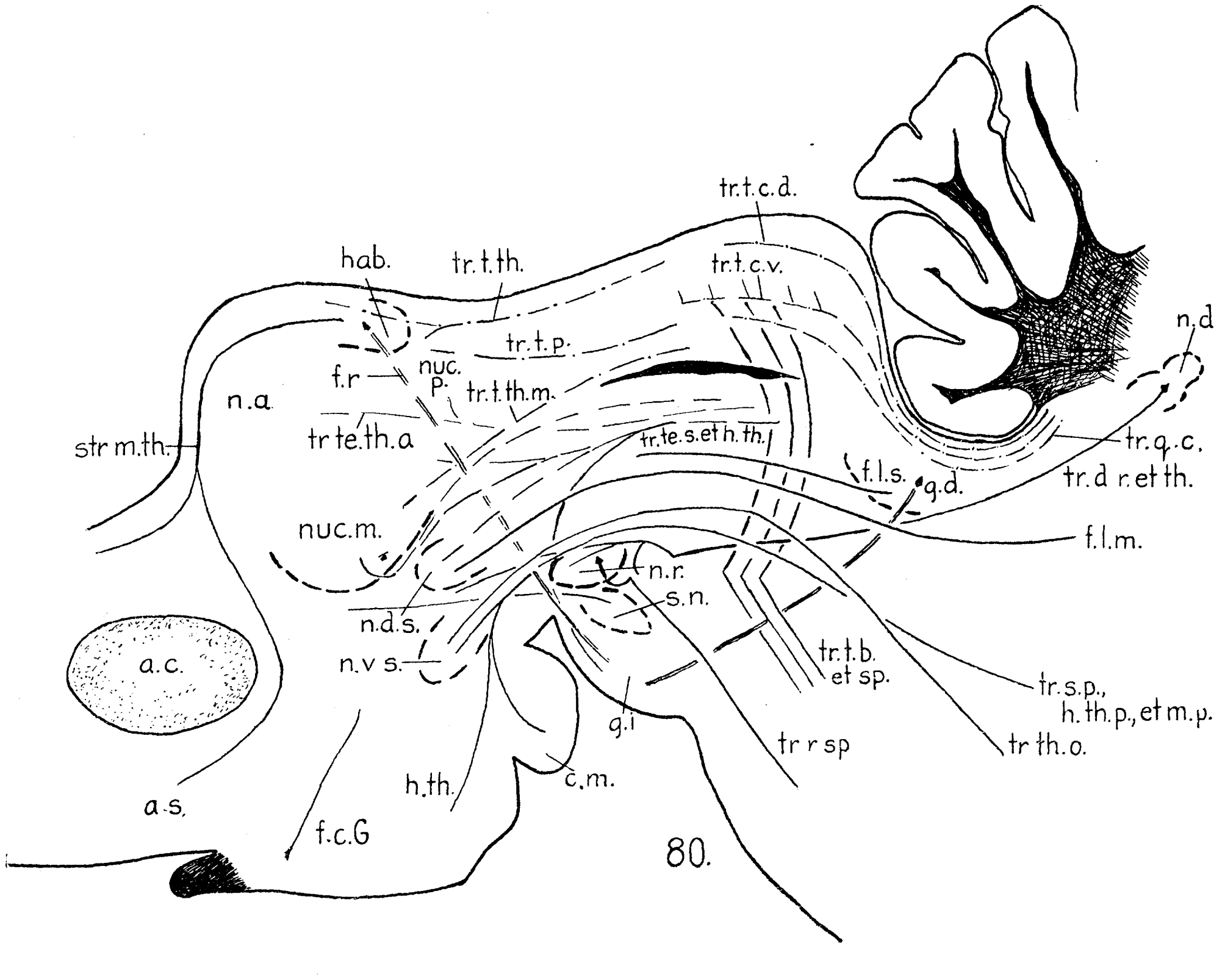
tr. t. c. d.
hab.
tr. t. th.
tr. t. c. v.
tr. t. p.
n. d
n. a
f. r
nuc. P.
tr. t. th. m.
str m. th.
tr te. th. a
tr. te. s. et h. th.
tr. q. c.
f. l. s.
q. d.
tr. d r. et th.
nuc. m.
f. l. m.
n. r.
s. n.
n. d. s.
a. c.
n. v s.
tr. t. b. et sp.
tr. s. p., h. th. p., et m. p.
g. i
tr r sp
tr th. o.
a. s.
h. th.
c. m.
f. c. G

80.

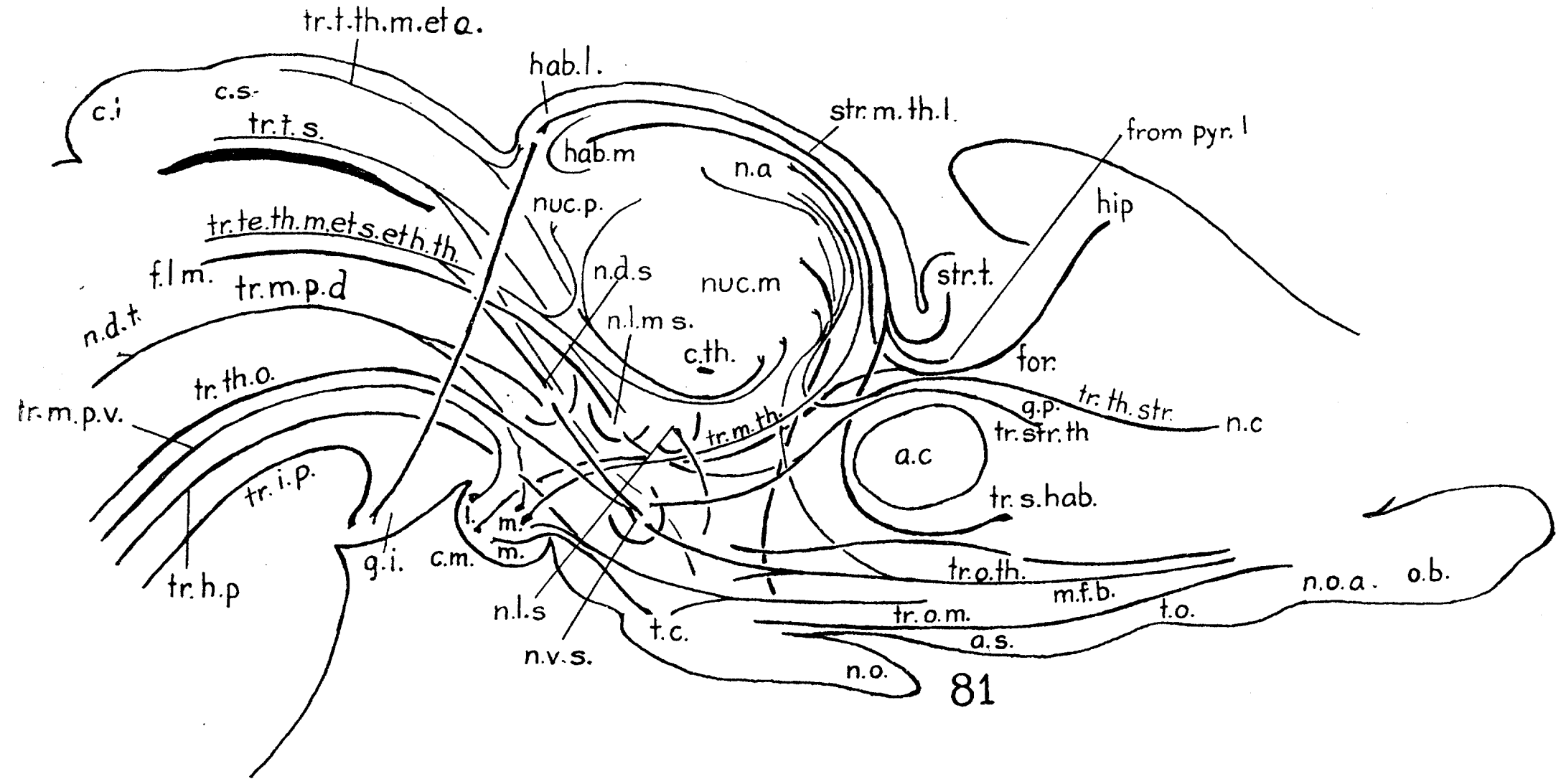
tr.t.th.m.et a.
c.s.
c.i
tr.t.s.
tr.te.th.m.et s.et h.th.
f.l m.
tr.m.p.d
n.d.t.
tr.th.o.
tr.m.p.v.
tr.i.p.
tr.h.p
g.i.
c.m.
l.
m.
m.
n.l.s
n.v.s.
t.c.
hab.l.
hab.m
nuc.p.
n.d.s
n.l.m s.
nuc.m
c.th.
n.a
str.m.th.l.
from pyr. l
hip
str.t.
for.
g.p.
tr.th.str.
n.c
tr.str.th
a.c
tr.s.hab.
tr.m.th.
tr.o.th.
m.f.b.
n.o.a.
o.b.
tr.o.m.
a.s.
t.o.
n.o.

81

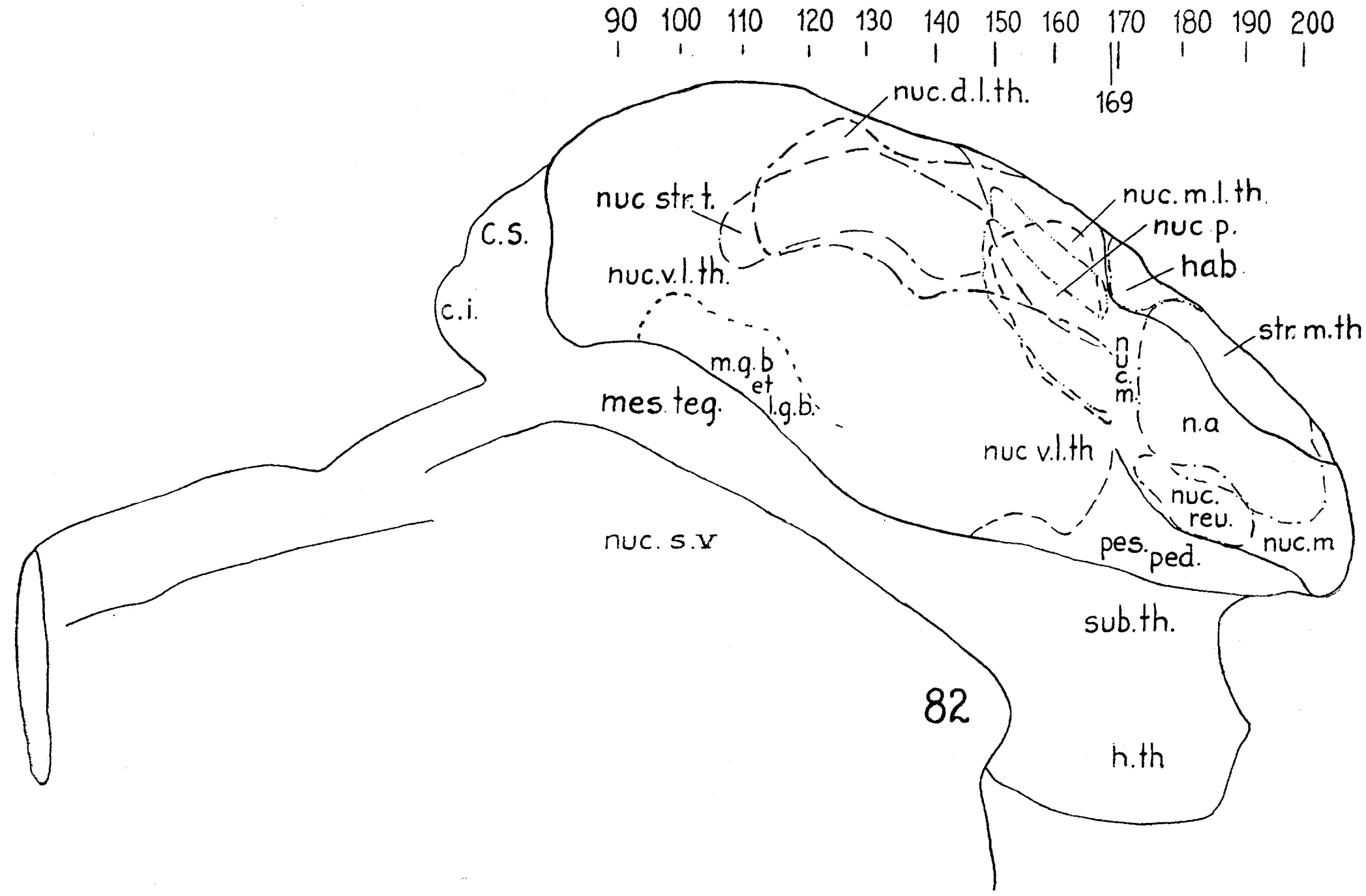
90
100
110
120
130
140
150
160
170
169
180
190
200
nuc.d.l.th.
nuc str.t.
c.s.
c.i.
nuc.v.l.th.
nuc.m.l.th
nuc p.
hab
str.m.th
n u c m
n.a
m.q.b et l.g.b.
mes teg.
nuc v.l.th
nuc. reu.
pes. ped.
nuc.m
nuc. s.V
sub.th.
h.th

82

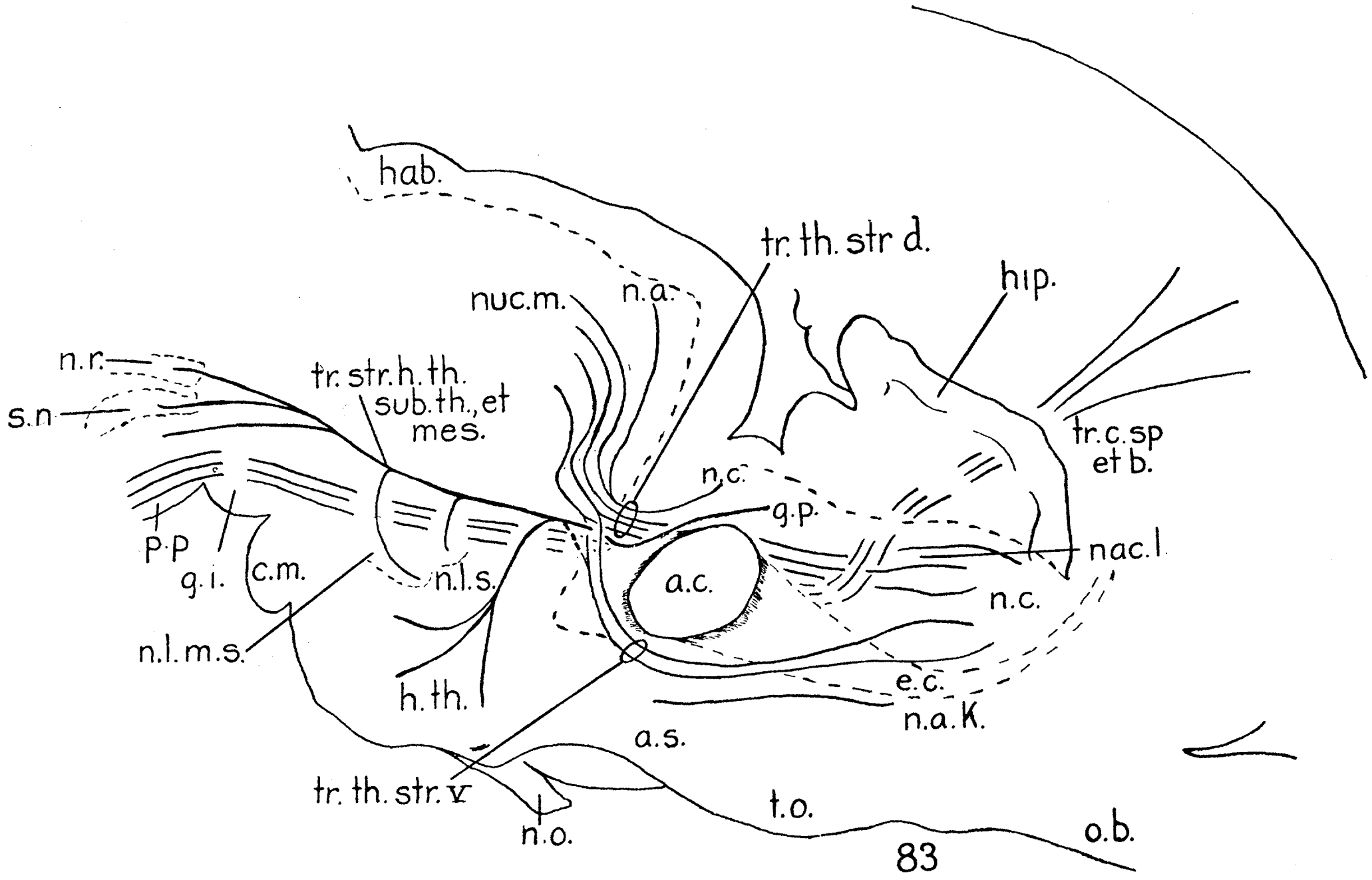
hab.
tr.th.str d.
hip.
nuc.m.
n.a.
n.r.
s.n
tr.str.h.th. sub.th., et mes.
tr.c.sp et b.
n.c.
g.p.
nac.l
p.p
g.i.
c.m.
n.l.s.
a.c.
n.c.
n.l.m.s.
h.th.
e.c.
n.a.K.
a.s.
tr.th.str.V
t.o.
n.o.
o.b.

83

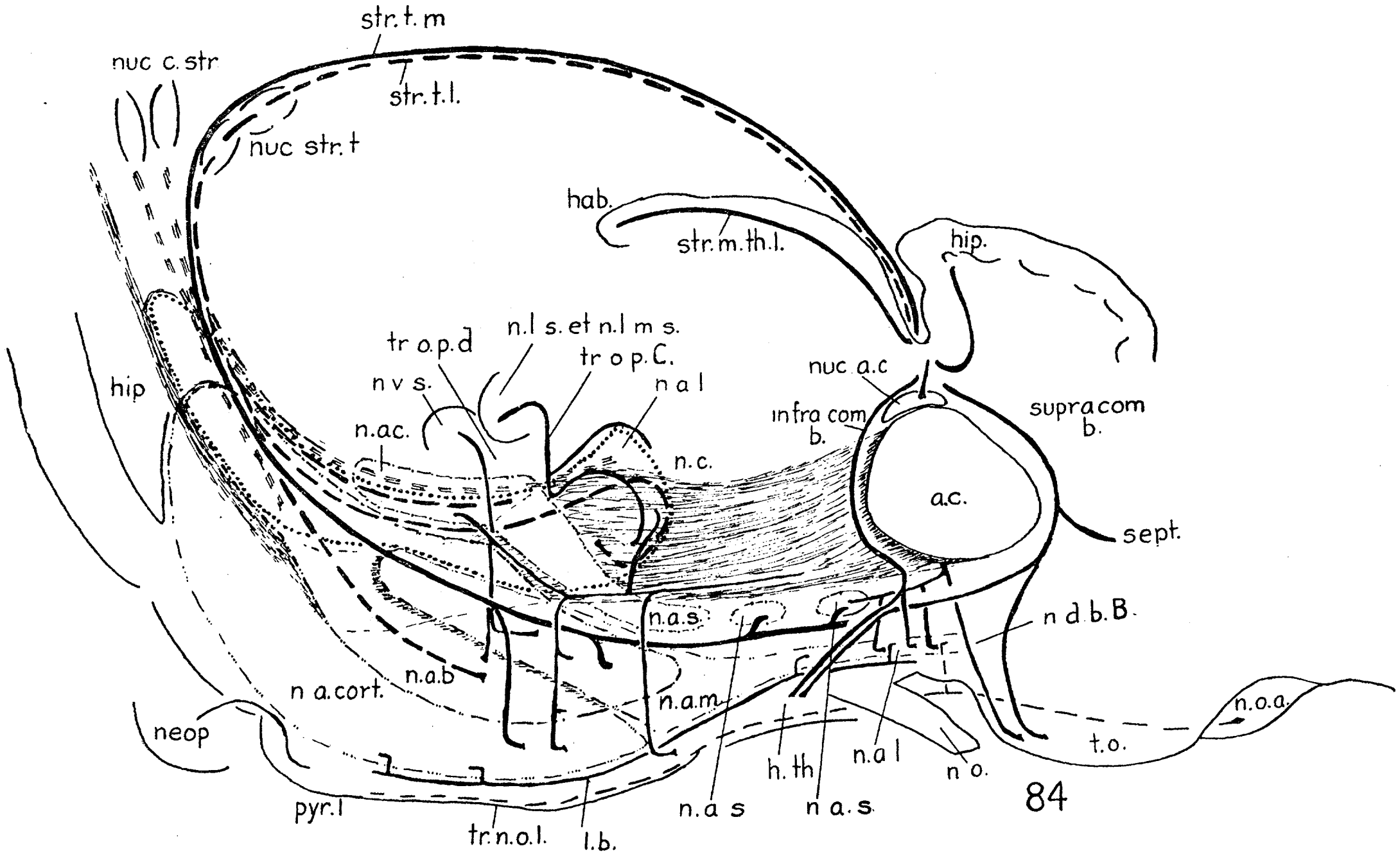

84

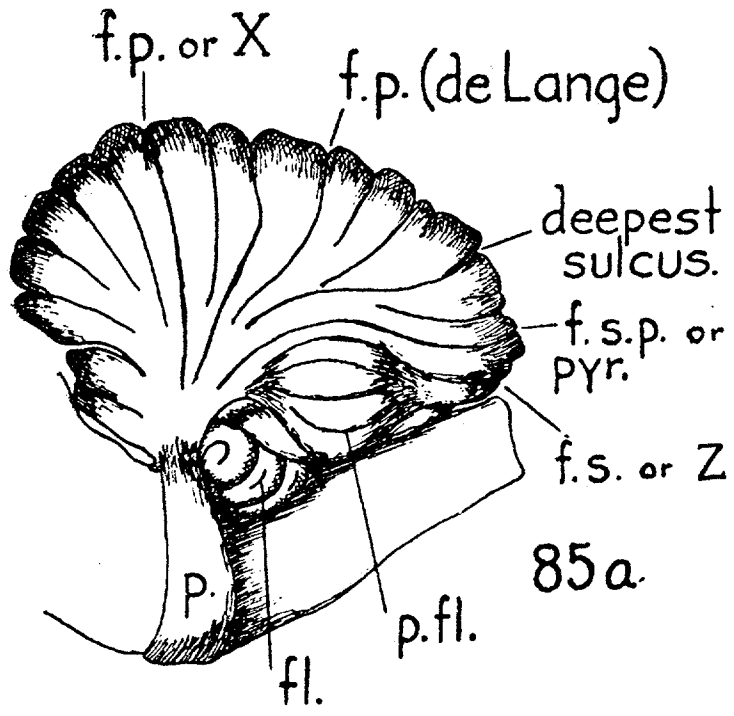

85 a.

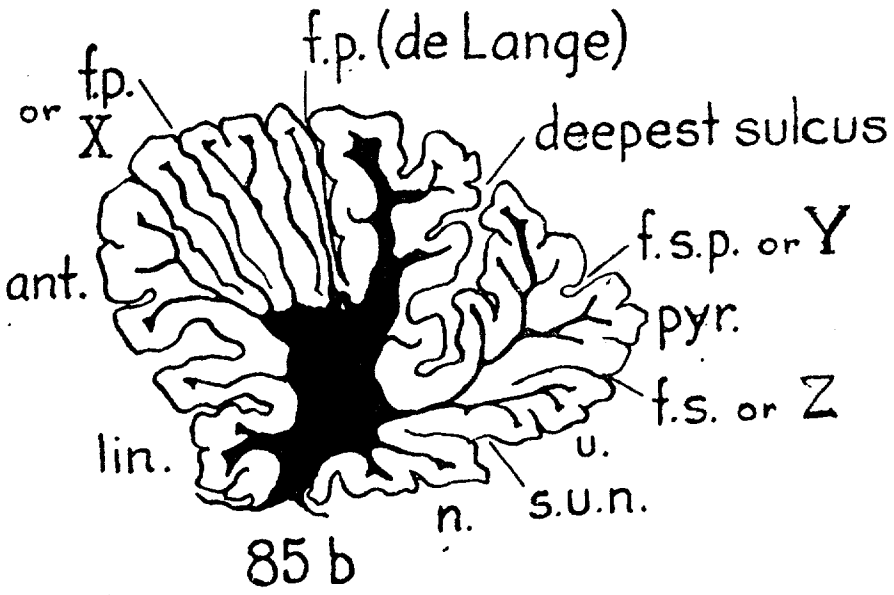

85 b

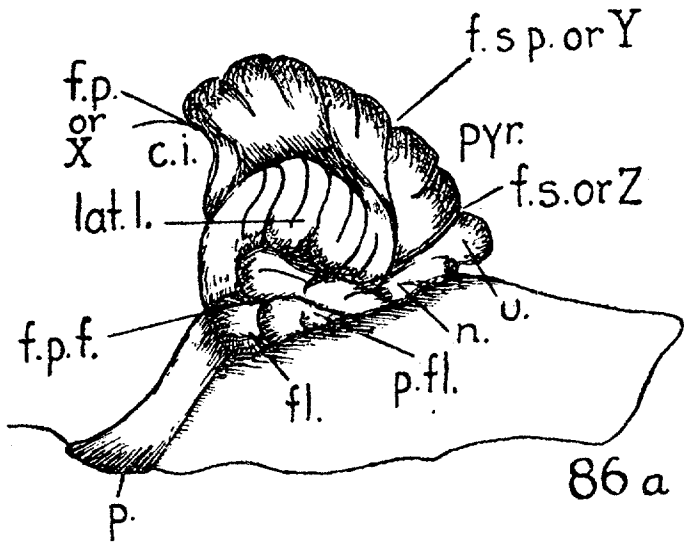

86 a

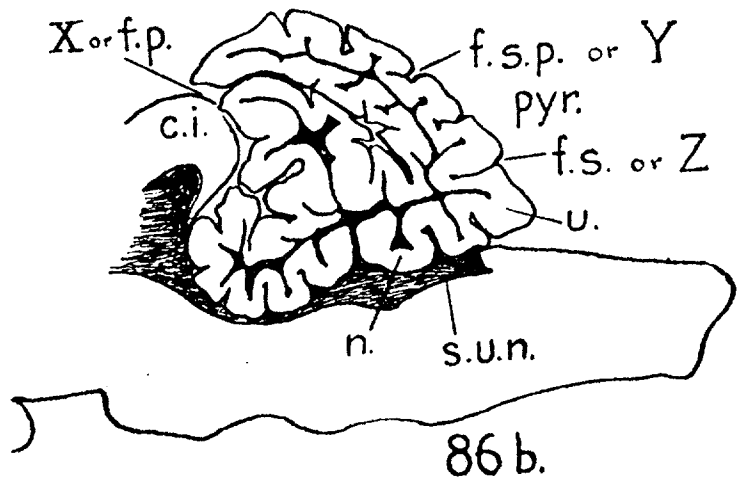

86 b.

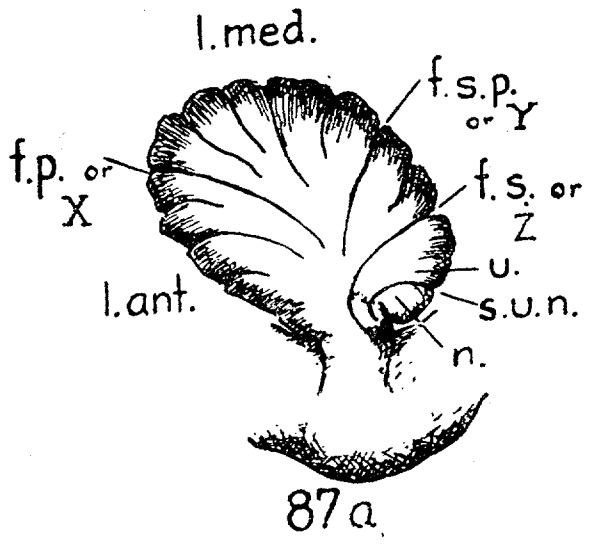

87 a.

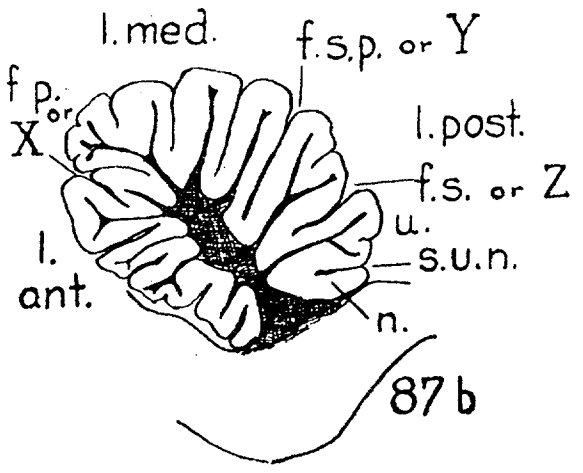

87 b

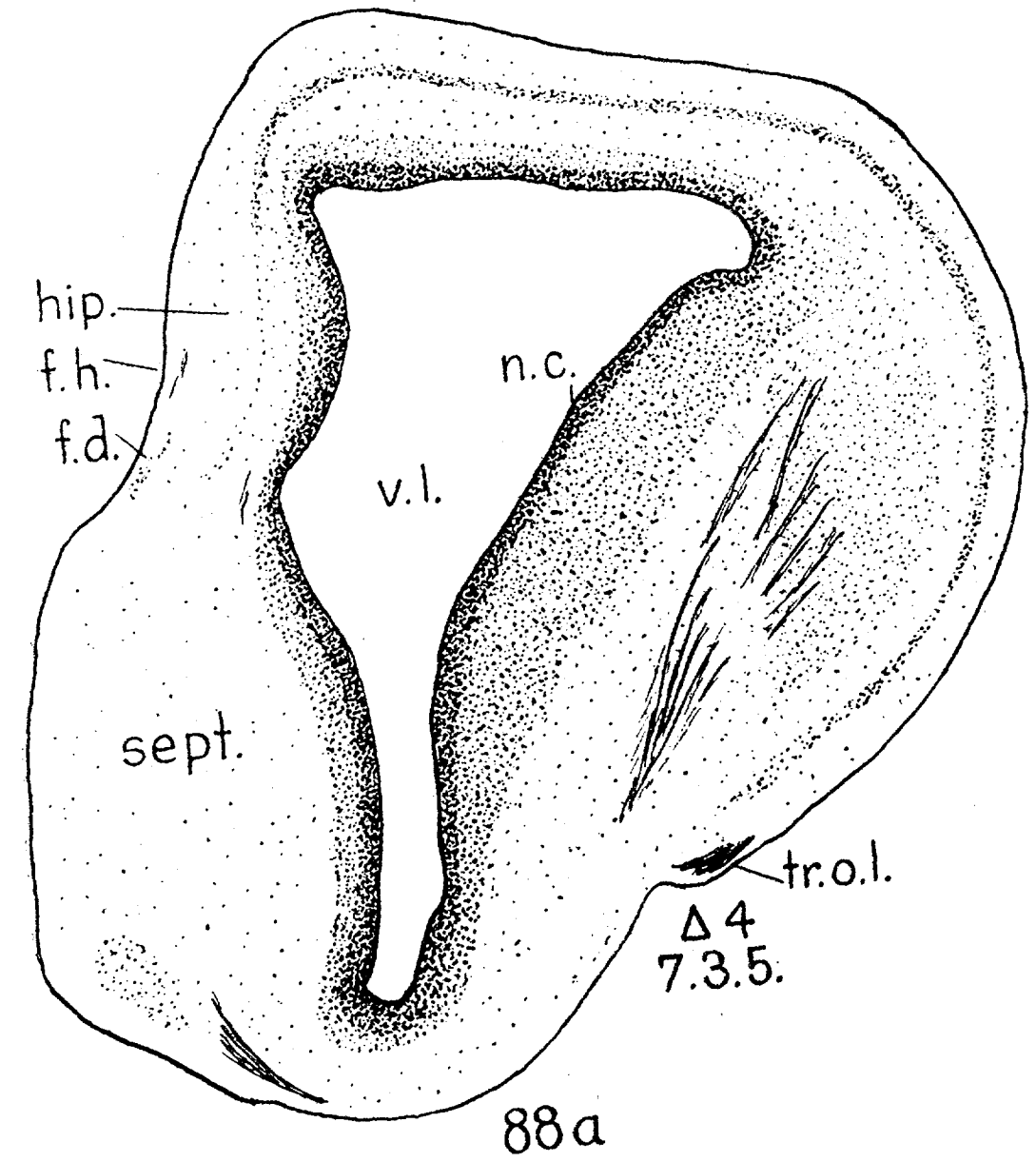
hip.
f.h.
f.d.
n.c.
v.l.
sept.
tr.o.l.
Δ4
7.3.5.

88 a

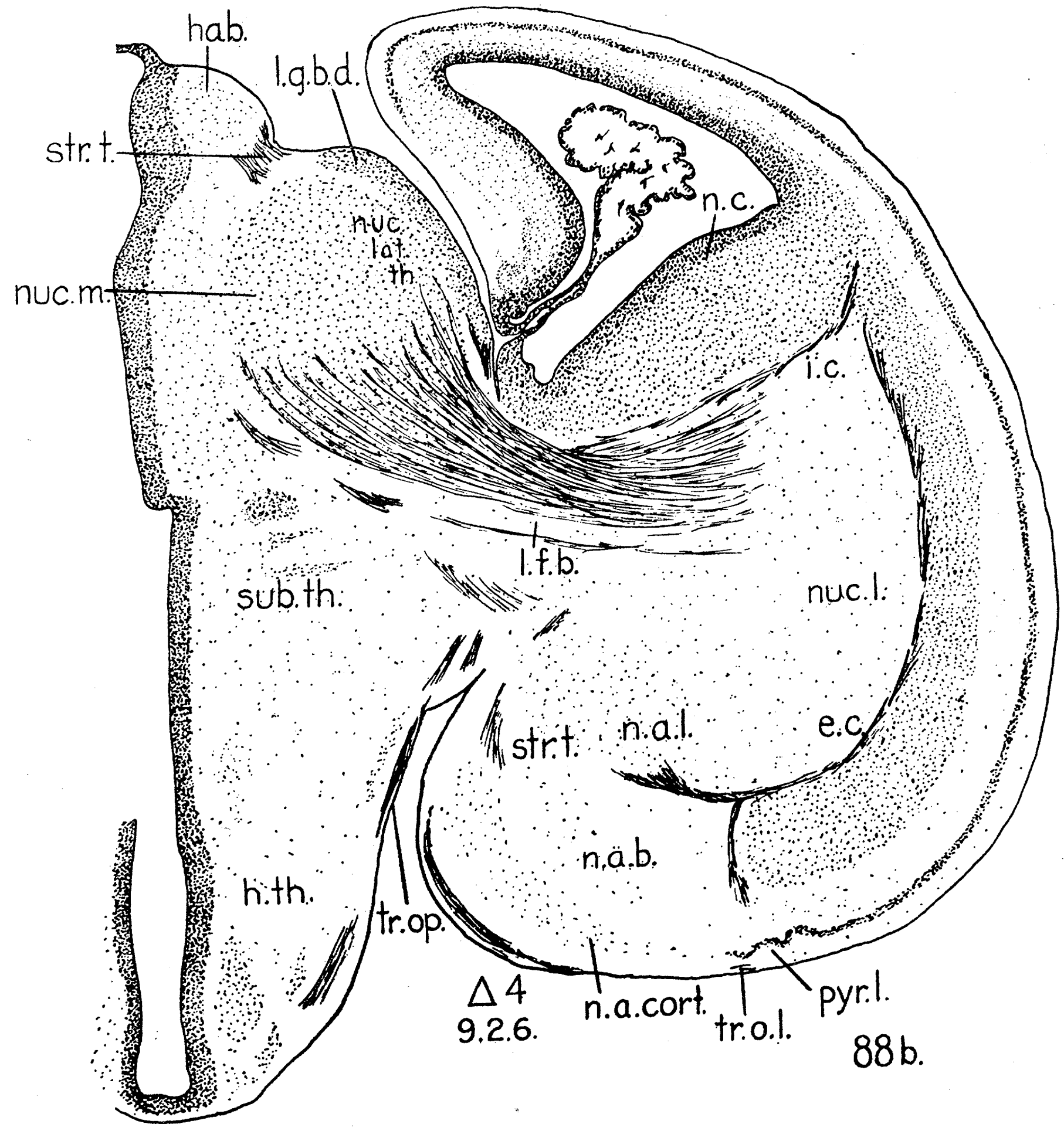
hab.
l.g.b.d.
str.t.
nuc. lat. th.
nuc.m.
n.c.
i.c.
l.f.b.
sub.th.
nuc.l.
str.t.
n.a.l.
e.c.
n.a.b.
h.th.
tr.op.
Δ4
9.2.6.
n.a.cort.
tr.o.l.
pyr.l.

88 b.

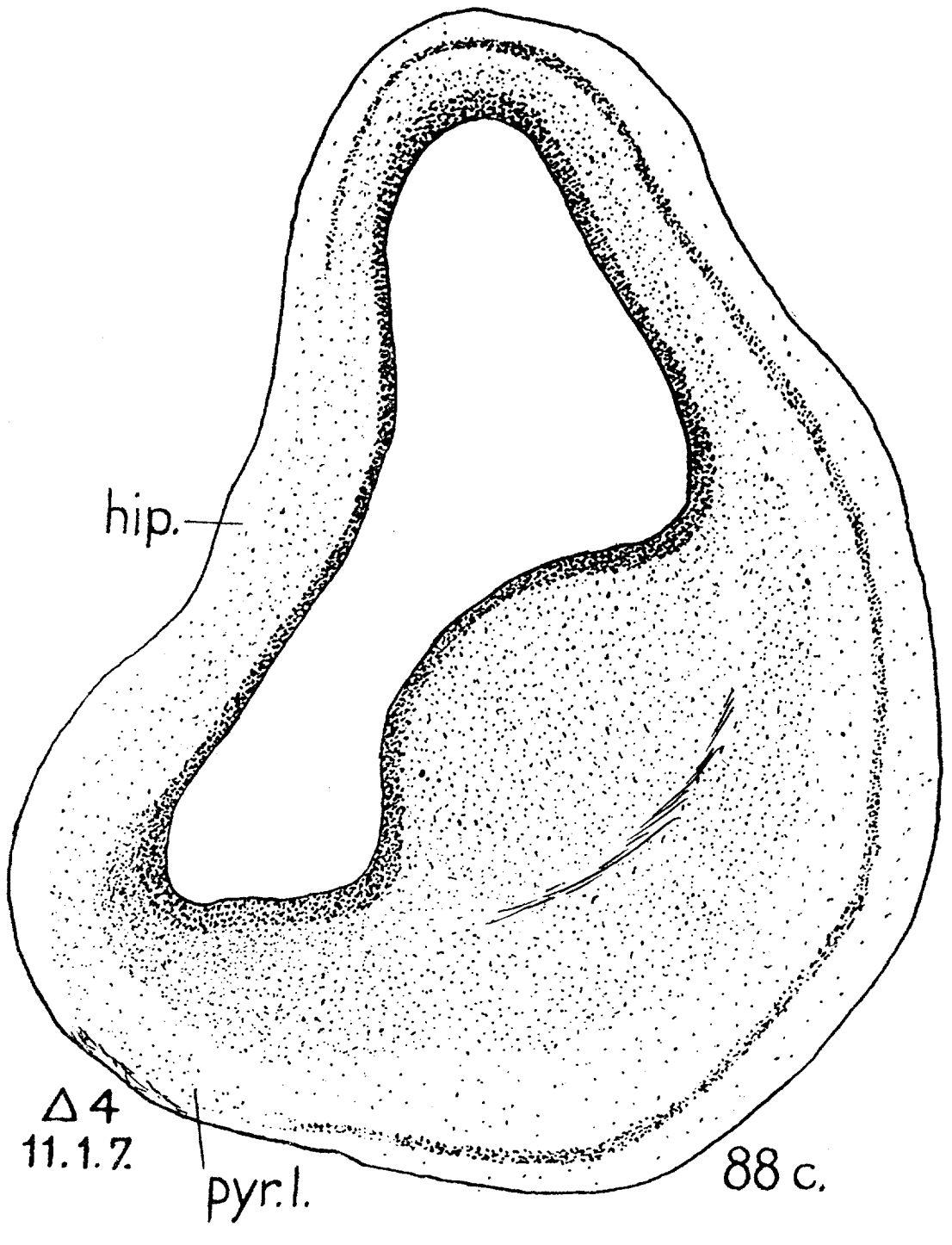
hip.
Δ4
11.1.7.
pyr.l.

88 c.

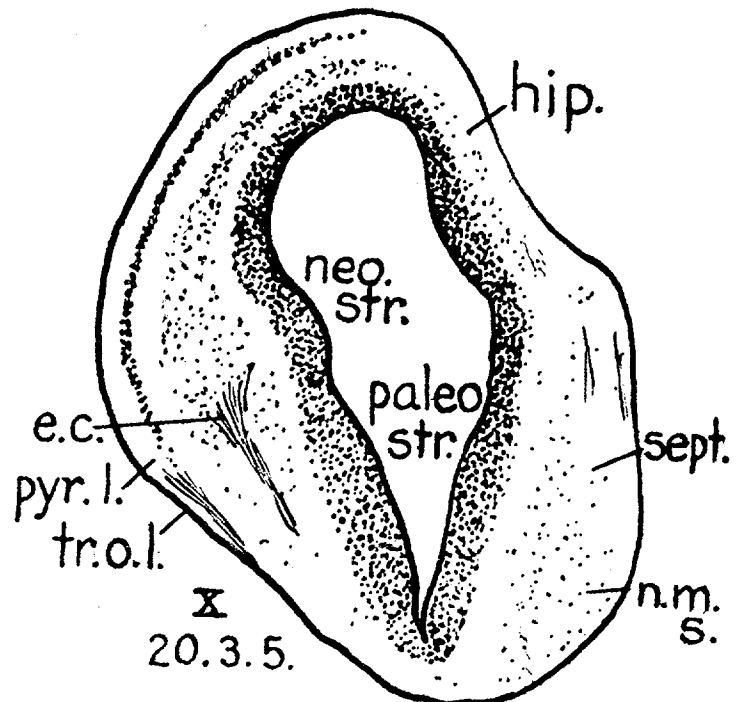

89 *a*

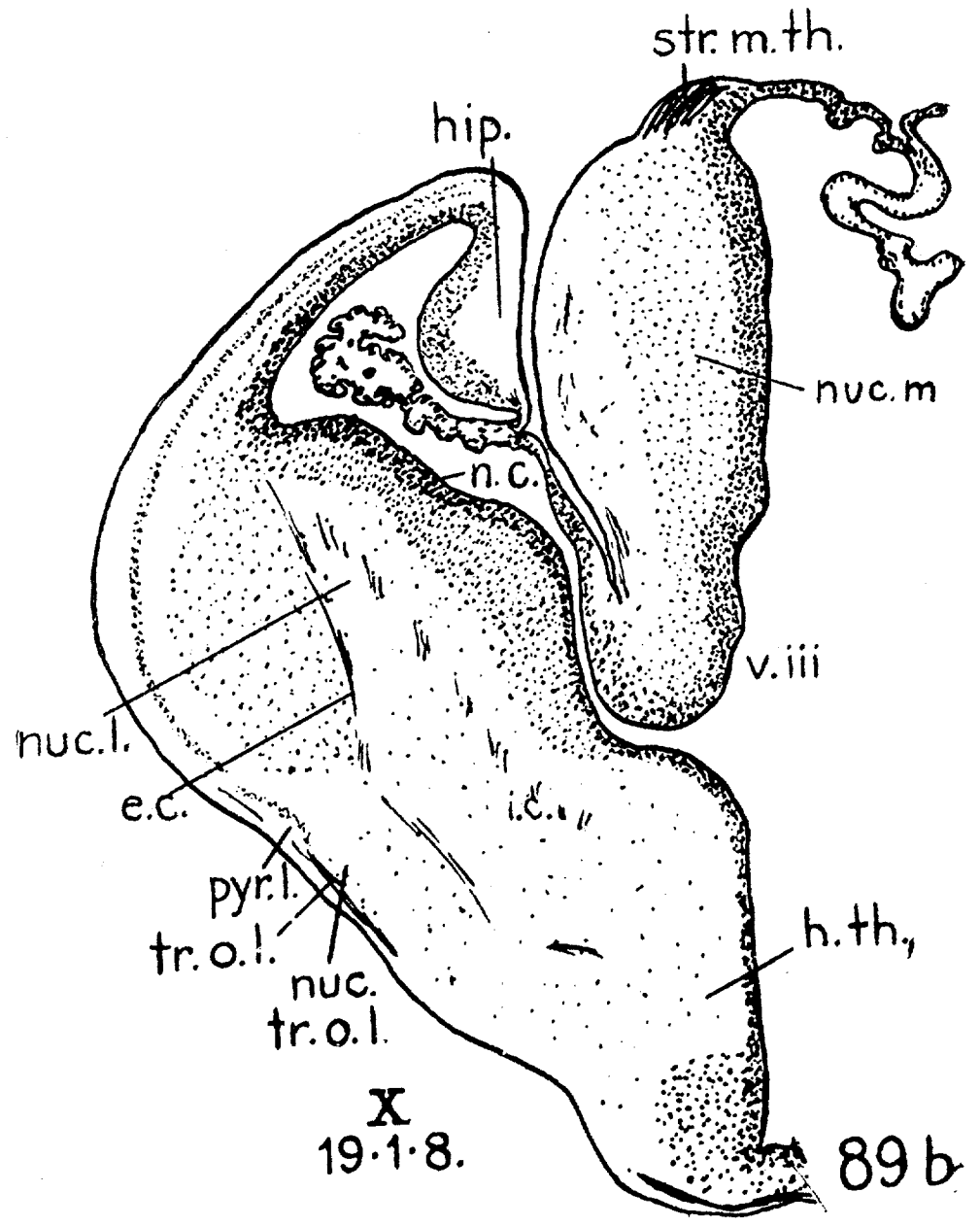

89 b

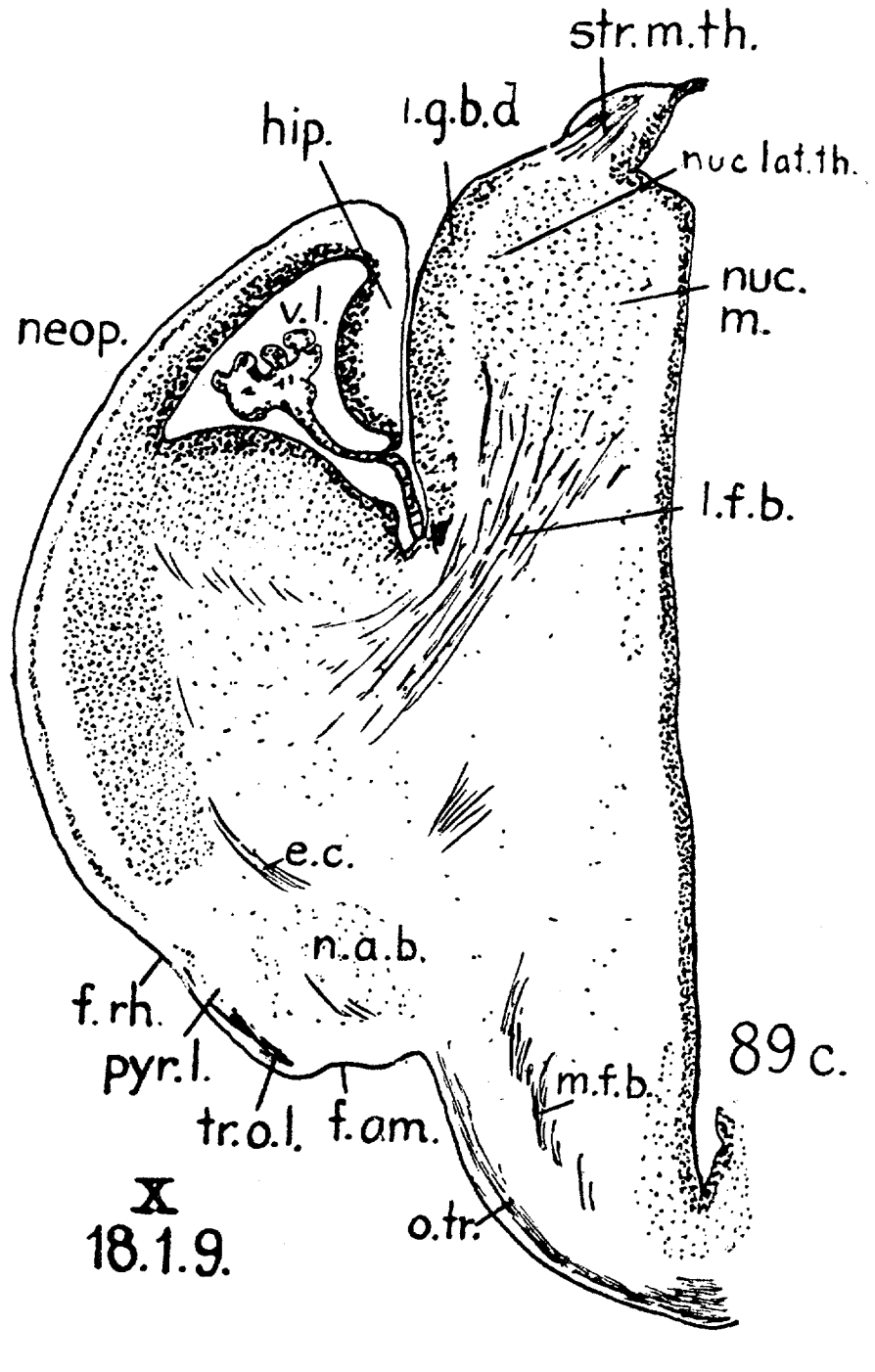

89 c.

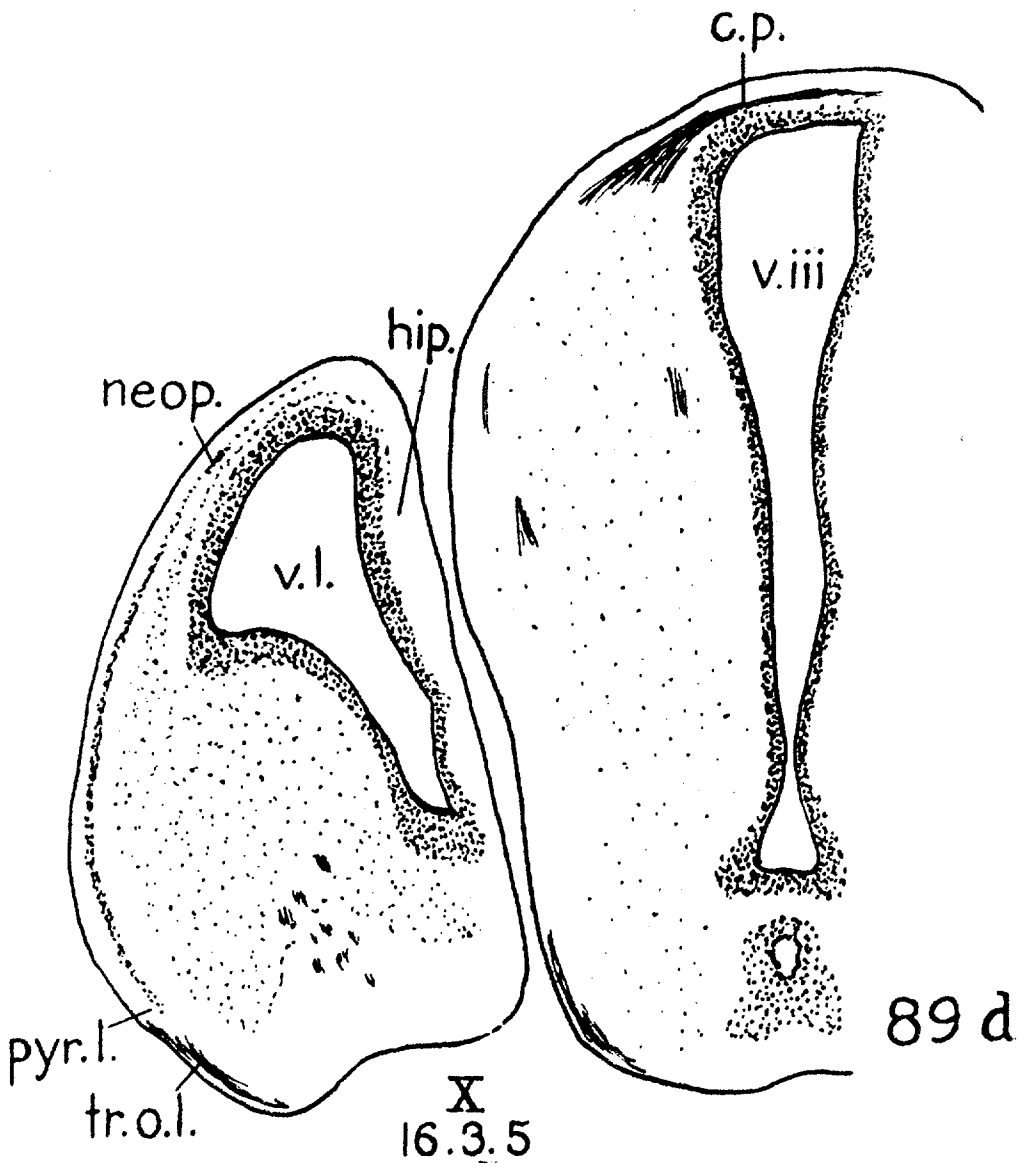

89 d

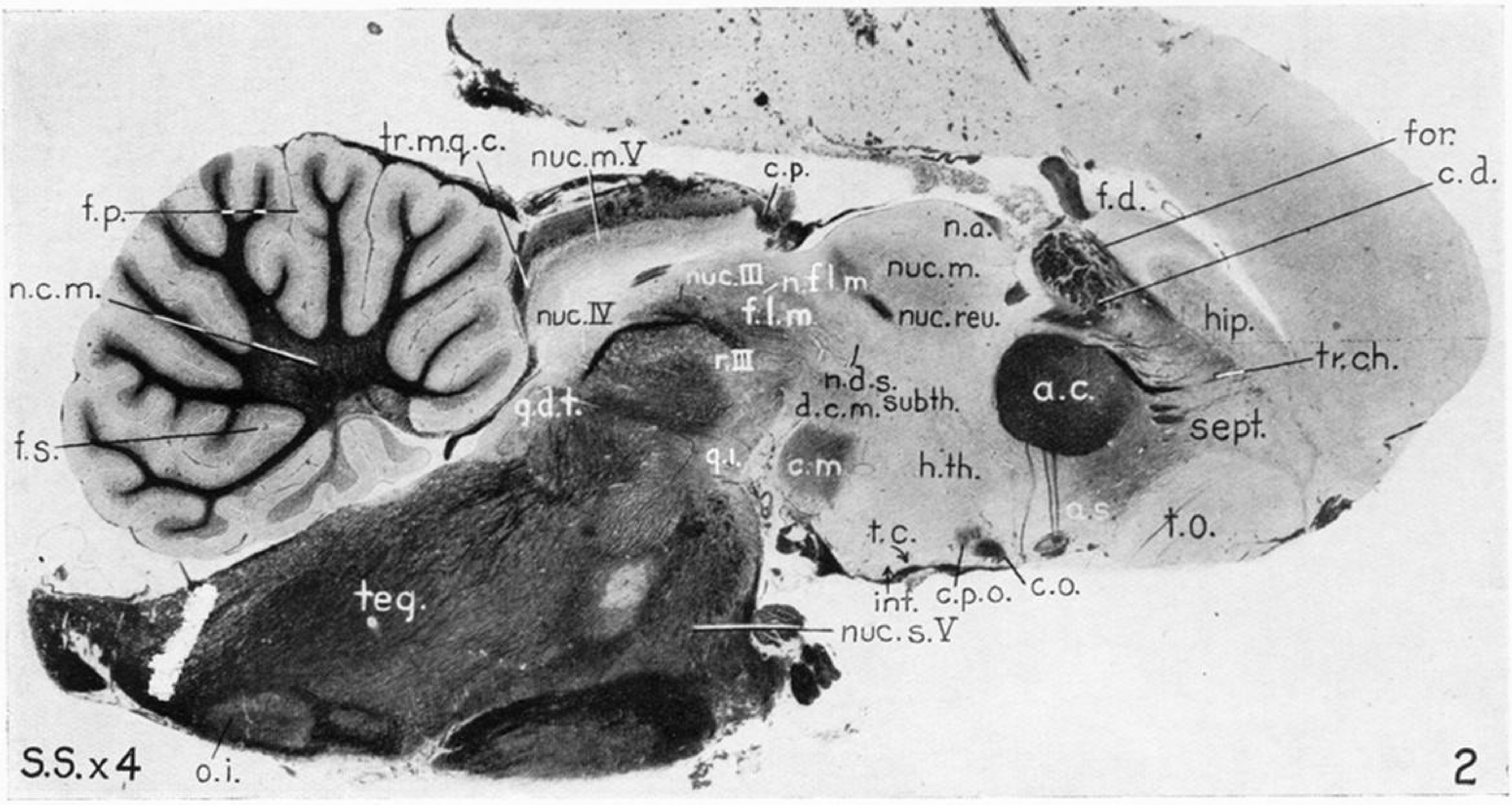

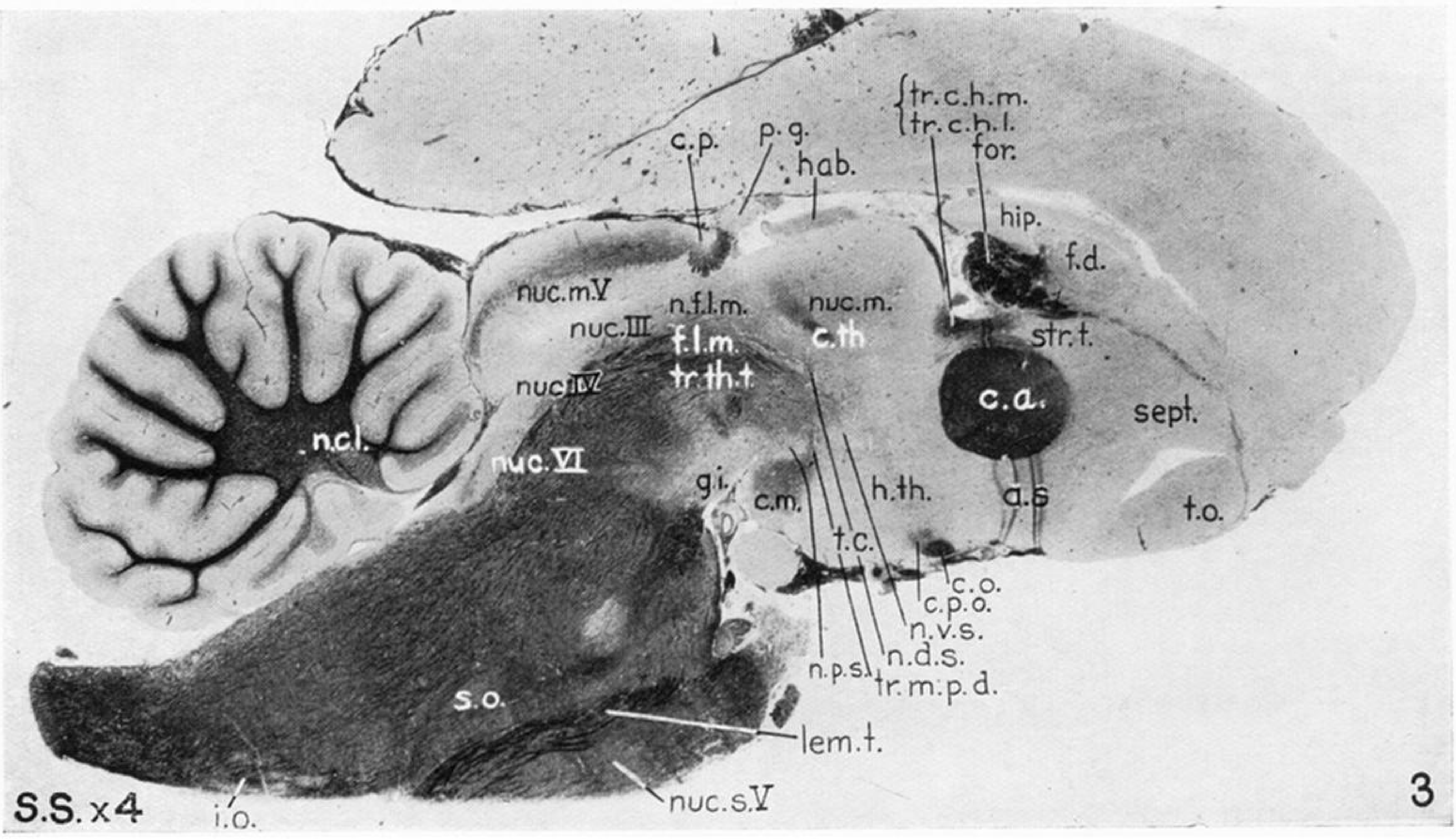

PLATE 41.

FIG. 1.—This is a photograph of the brain of Platypus taken *in situ*. The walls of the cranium have been removed, so that the whole is revealed in its relation to the eyes and the interesting fleshy rostrum which bears the openings of the nostrils, the so-called duck's bill. S. T. N. × 1.

FIGS. 2 to 11.—These are photographs of a sagittal series, at one time a part of Sir VICTOR HORSLEY's collection. × 4.

FIG. 2.—This section is taken slightly lateral to the median plane and shows the mesencephalic root of the fifth nerve, the fasciculus longitudinalis medialis, the roots of the oculo-motor nerve, the dorsal and ventral commissures, the fornix and the corpus mamillare.

FIG. 3.—Through the septum, the tuberculum olfactorium, the corpus mamillare and the ganglion inter pedunculare. It shows the trigeminal lemniscus and the medial portion of the sensory nucleus of the fifth.

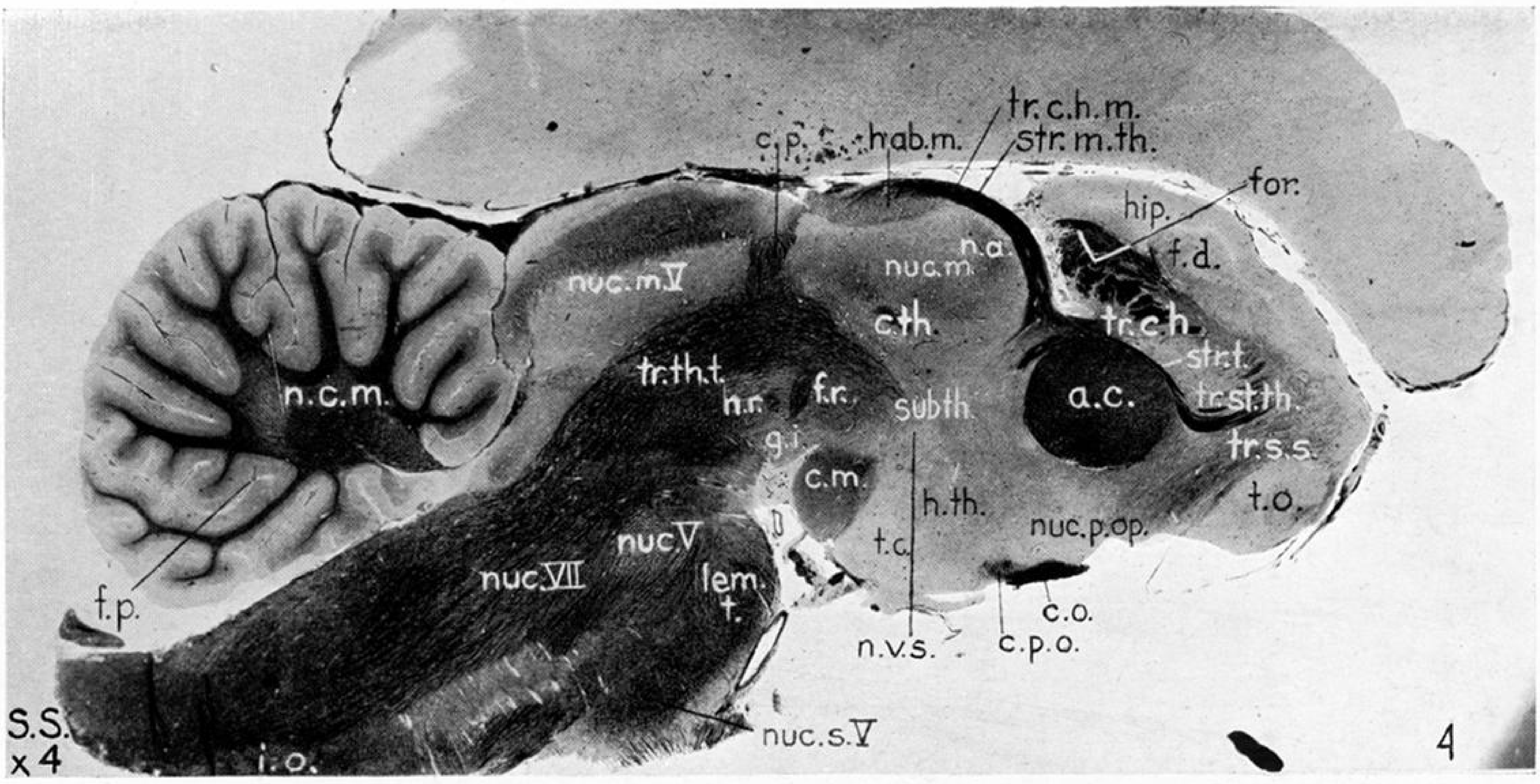

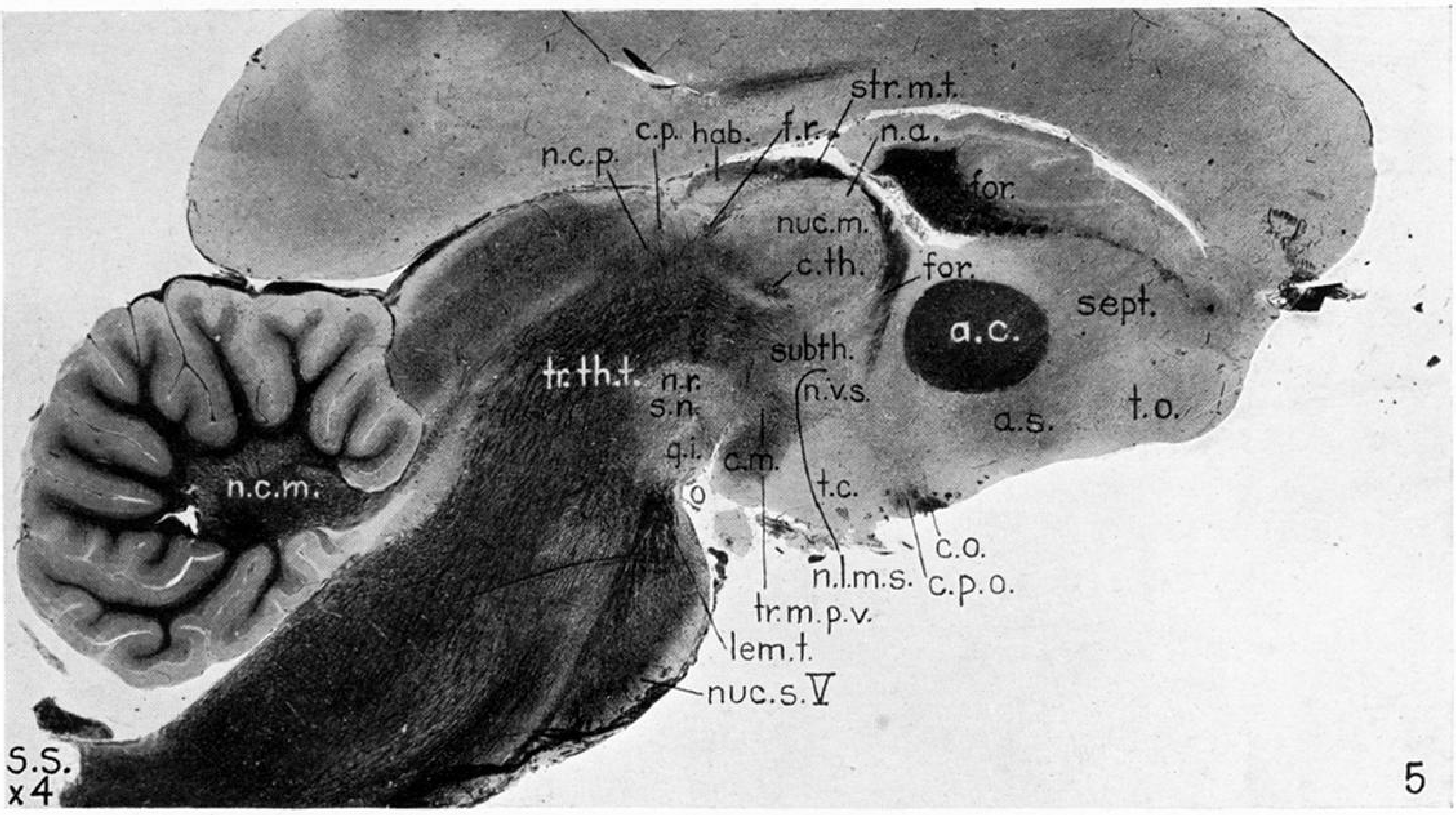

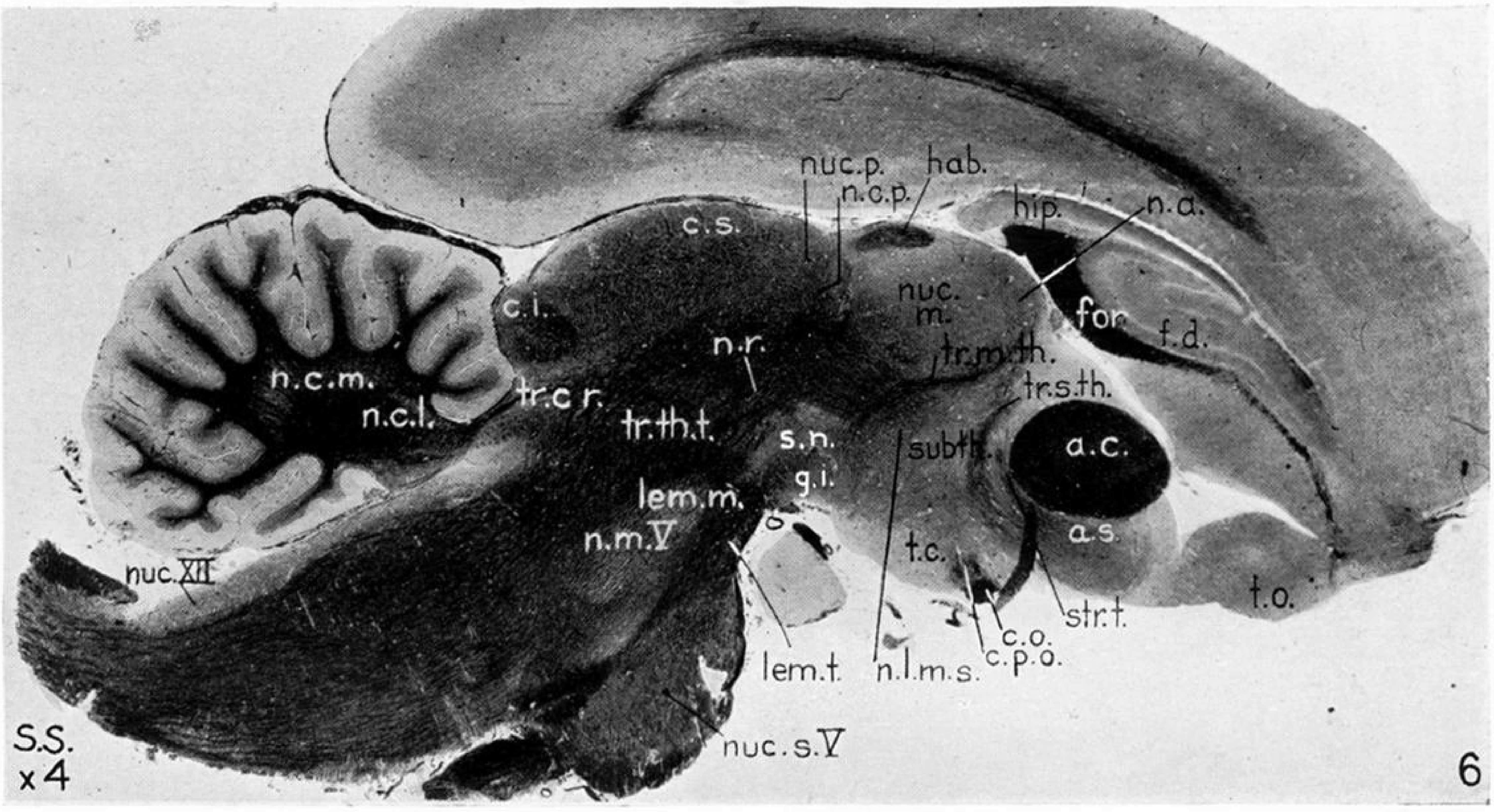

PLATE 42.

FIG. 4.—Through the trabecula and the stria medullaris thalami showing in particular the tecto-cerebellar tracts, the lateral cells of the mesencephalic nucleus of the trigeminus, the tractus strio-thalamicus ventralis and the tractus septo-corticalis.

FIG. 5.—Section showing the tractus habenulo-mamillaris, the fasciculus retroflexus, another tecto-cerebellar system, the trigeminal lemniscus, the commissura thalami, the medial nucleus of the cerebellum, and the great tegmental systems.

FIG. 6.—Section through the medial fibres of the cerebello-ruber fibre system, the lateral ventricle, the hippocampus, the fascia dentata and the tractus mamillo-thalamicus.

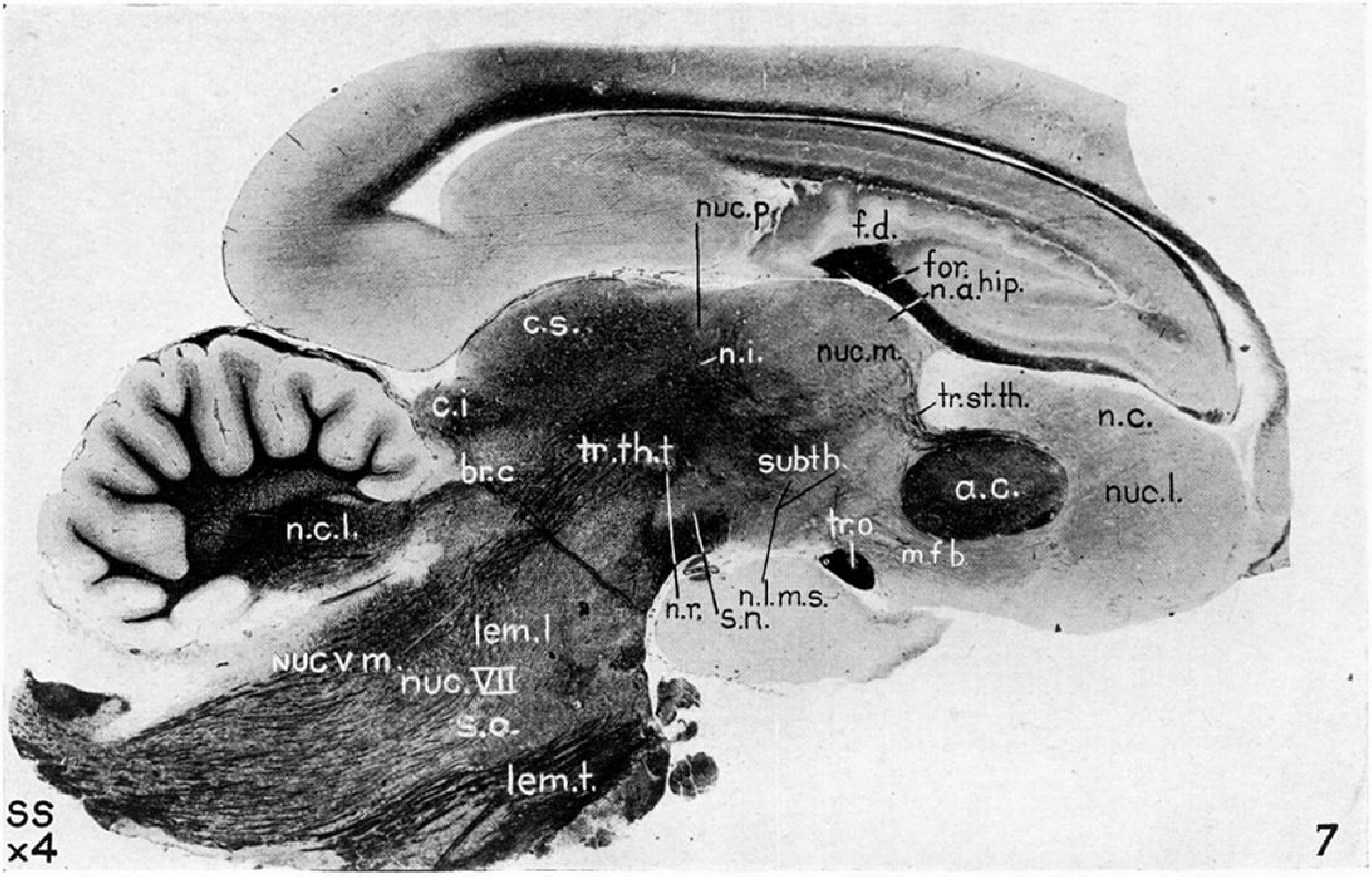

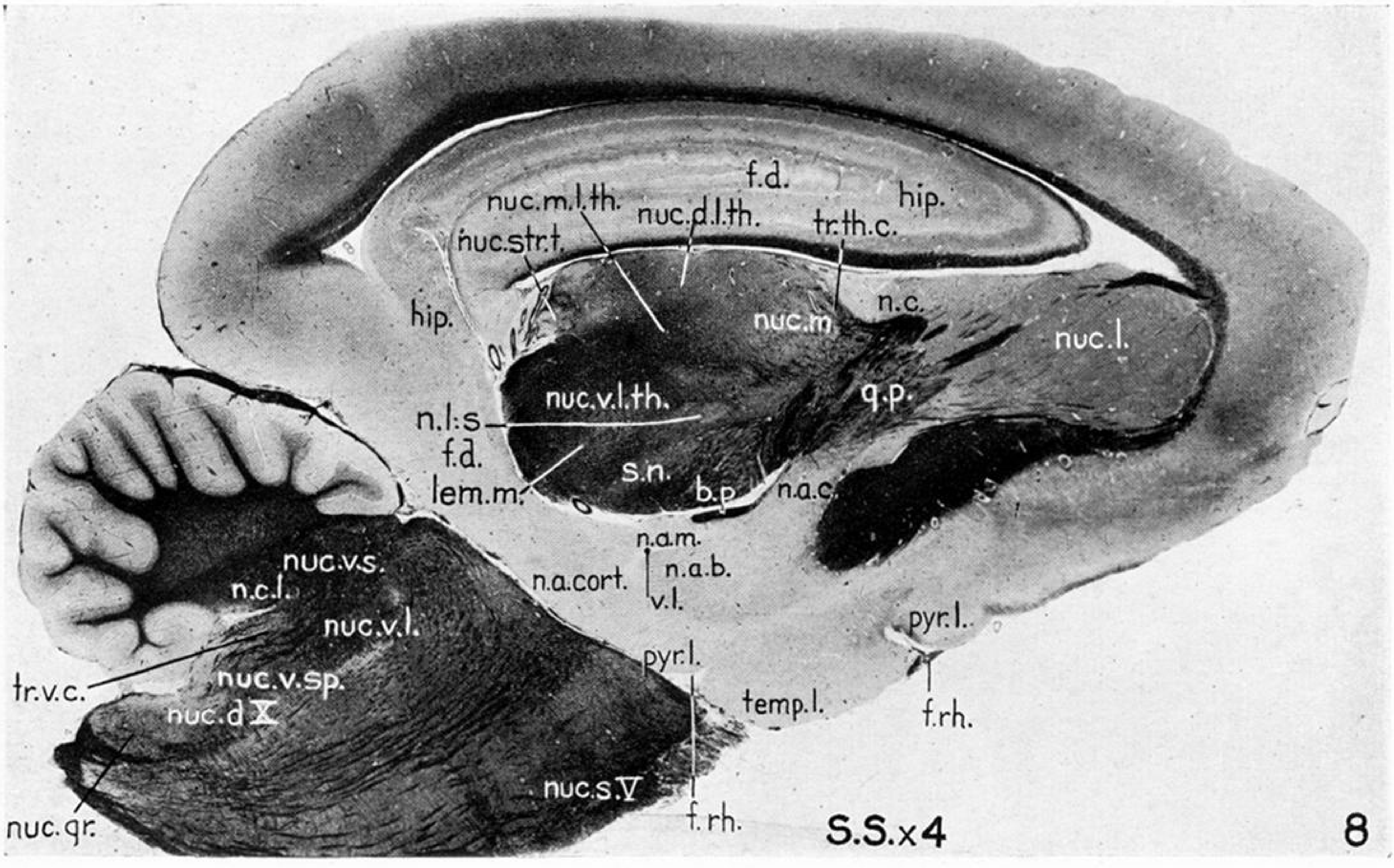

PLATE 43.

FIG. 7.—Through the inferior and superior colliculi showing the following tracts: strio-thalamic, the septo-thalamic and mesencephalic tracts, the lateral lemniscus, the brachium conjunctivum and the optic tract.

FIG. 8.—Section taken through the lateral part of the medulla, the corpus restiforme, the cerebellum, the thalamus, the anterior lateral part of the corpus striatum and the amygdaloid nuclei.

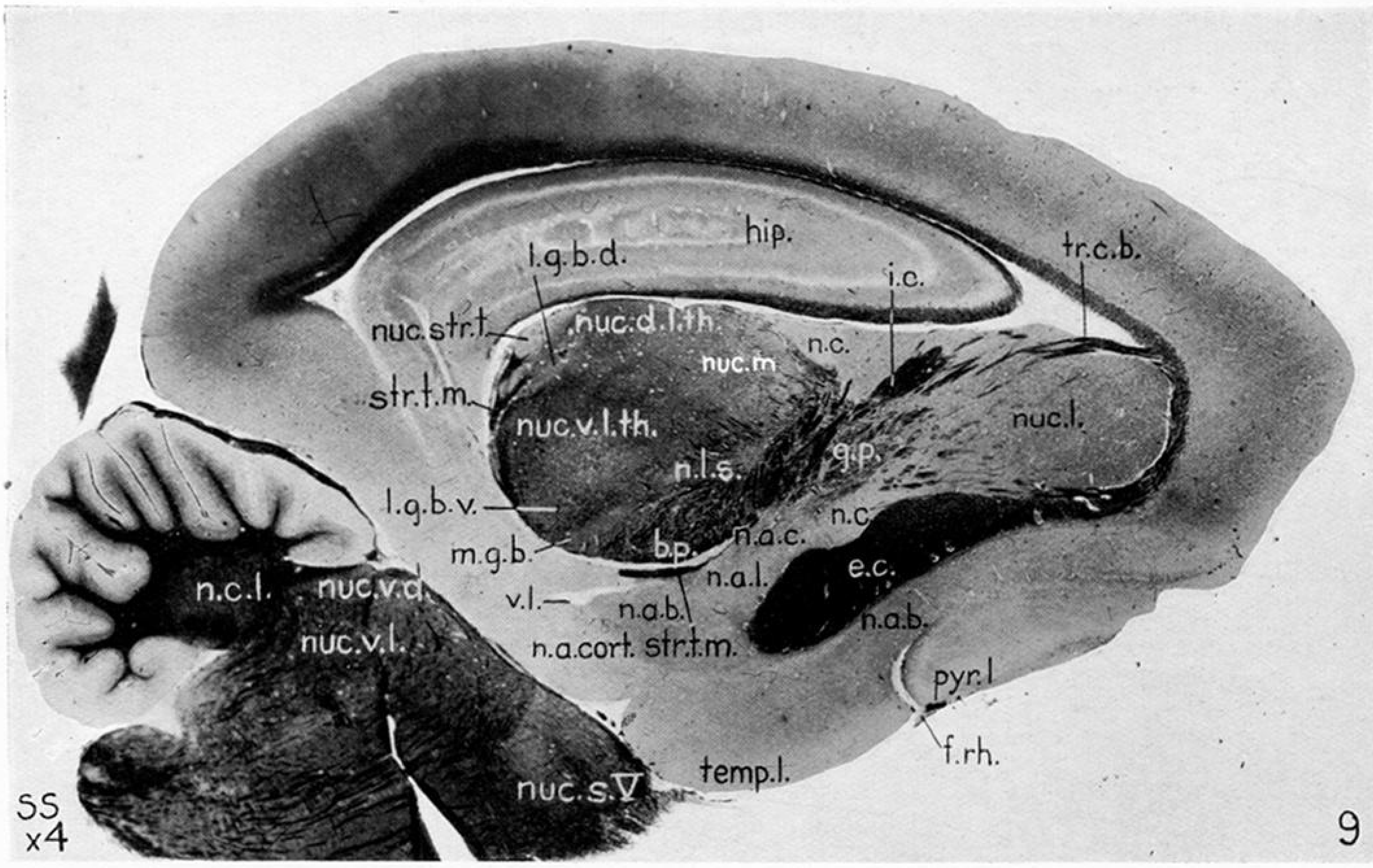

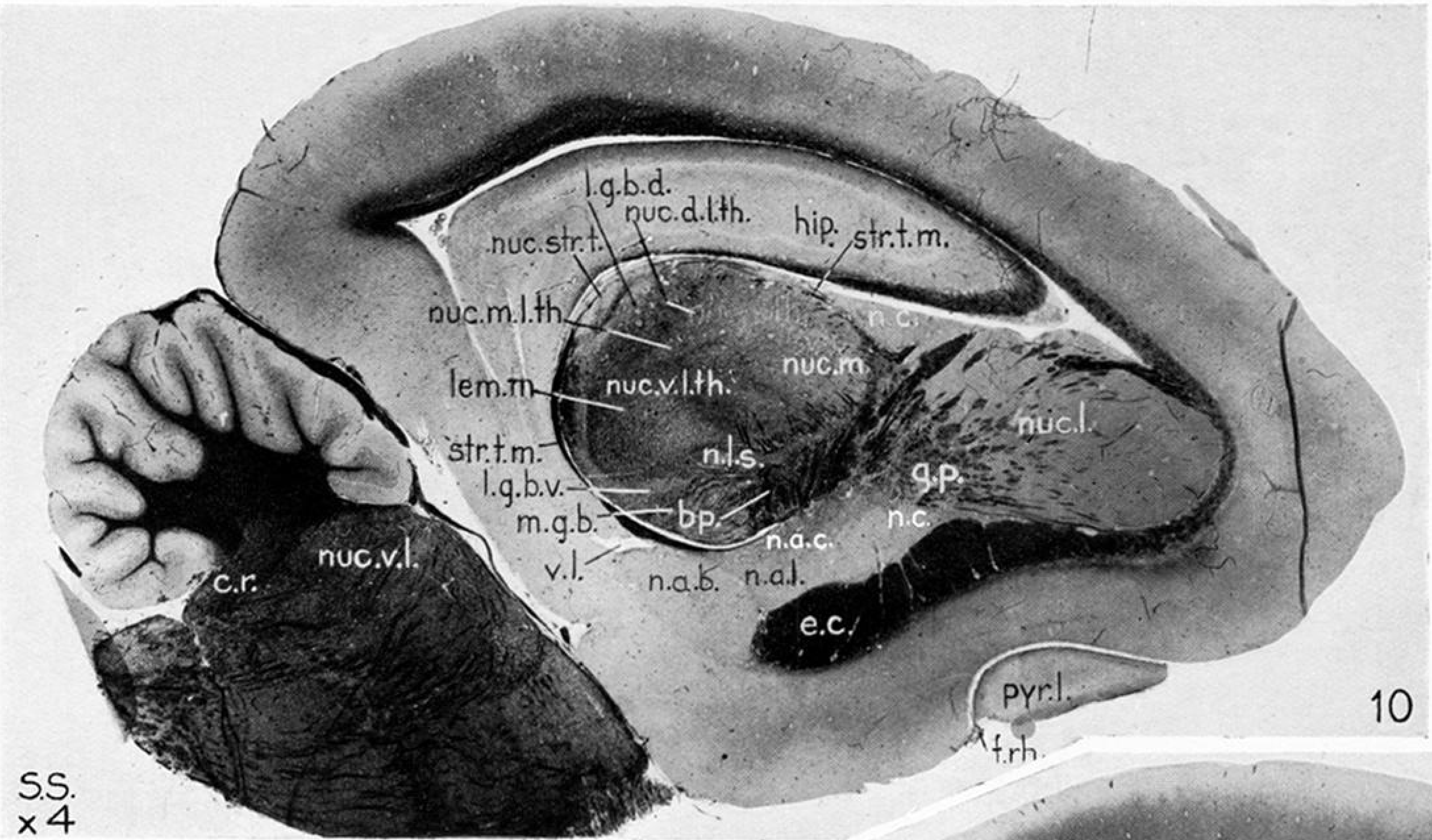

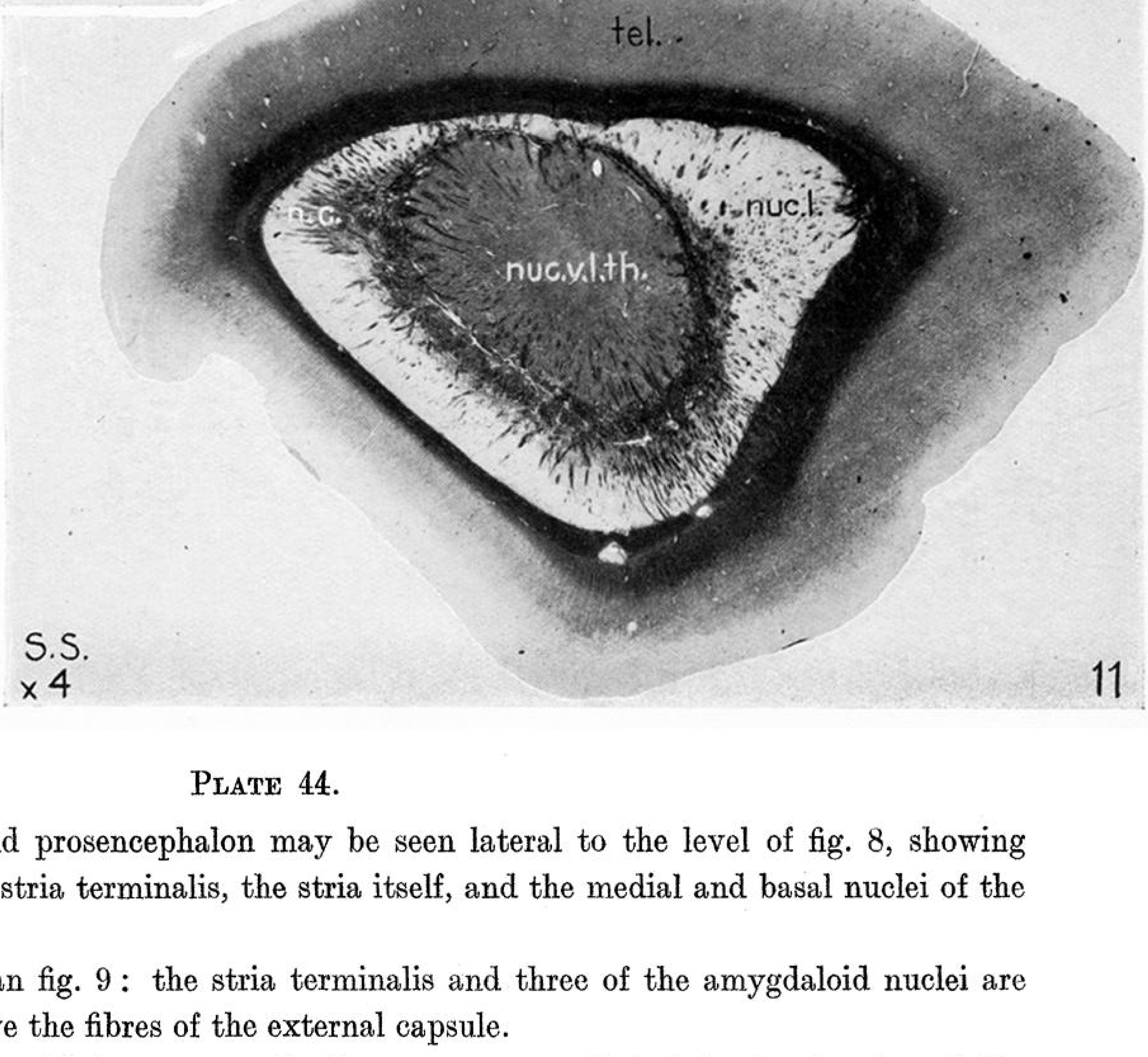

PLATE 44.

FIG. 9.—The rhombencephalon and prosencephalon may be seen lateral to the level of fig. 8, showing in particular the nuclei of the stria terminalis, the stria itself, and the medial and basal nuclei of the amygdala.

FIG. 10.—Section more lateral than fig. 9: the stria terminalis and three of the amygdaloid nuclei are easily distinguished lying above the fibres of the external capsule.

FIG. 11.—In this level the corpus striatum surrounds the numerous posterio-lateral extension of the nucleus lateralis thalami.

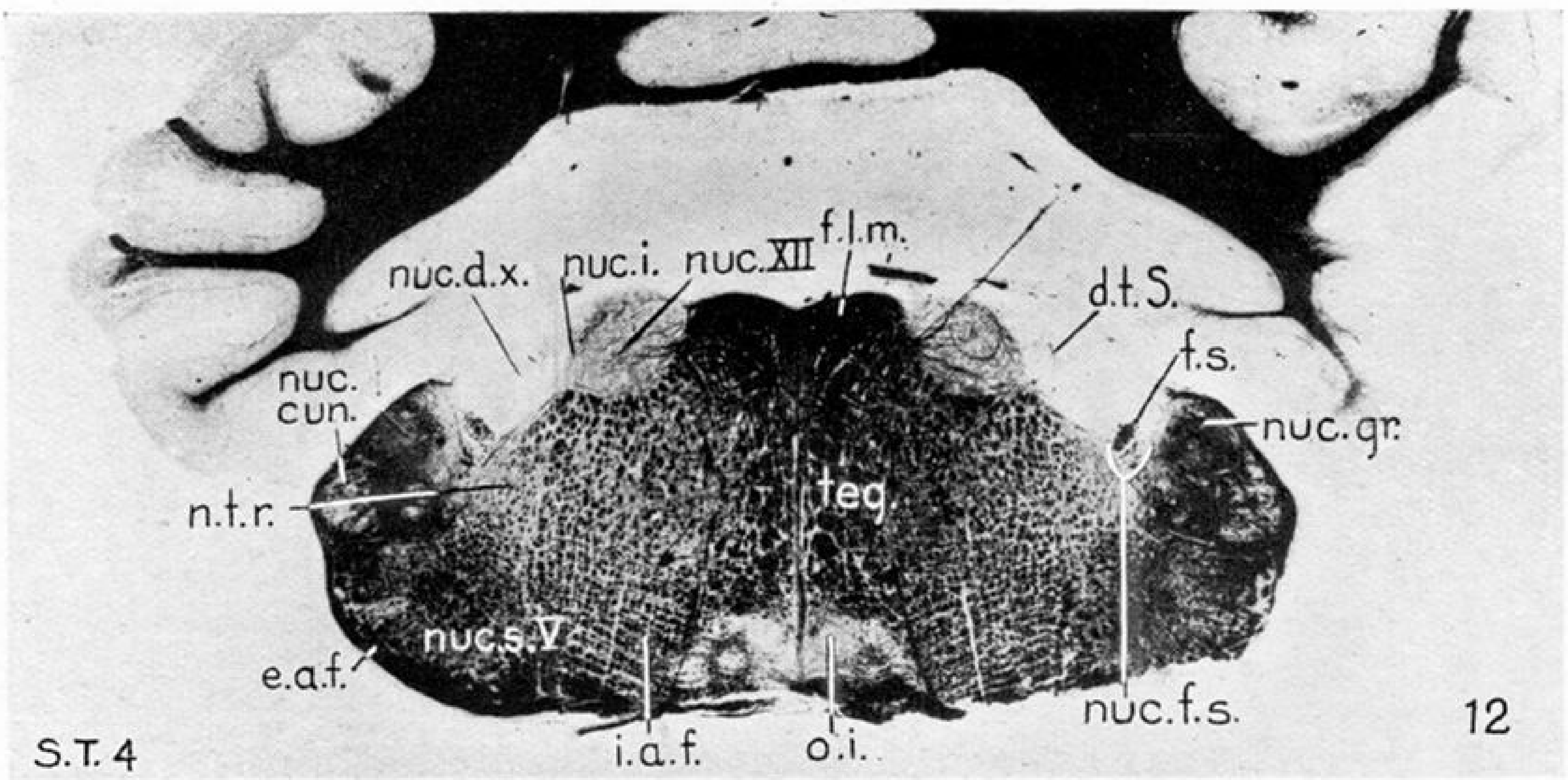

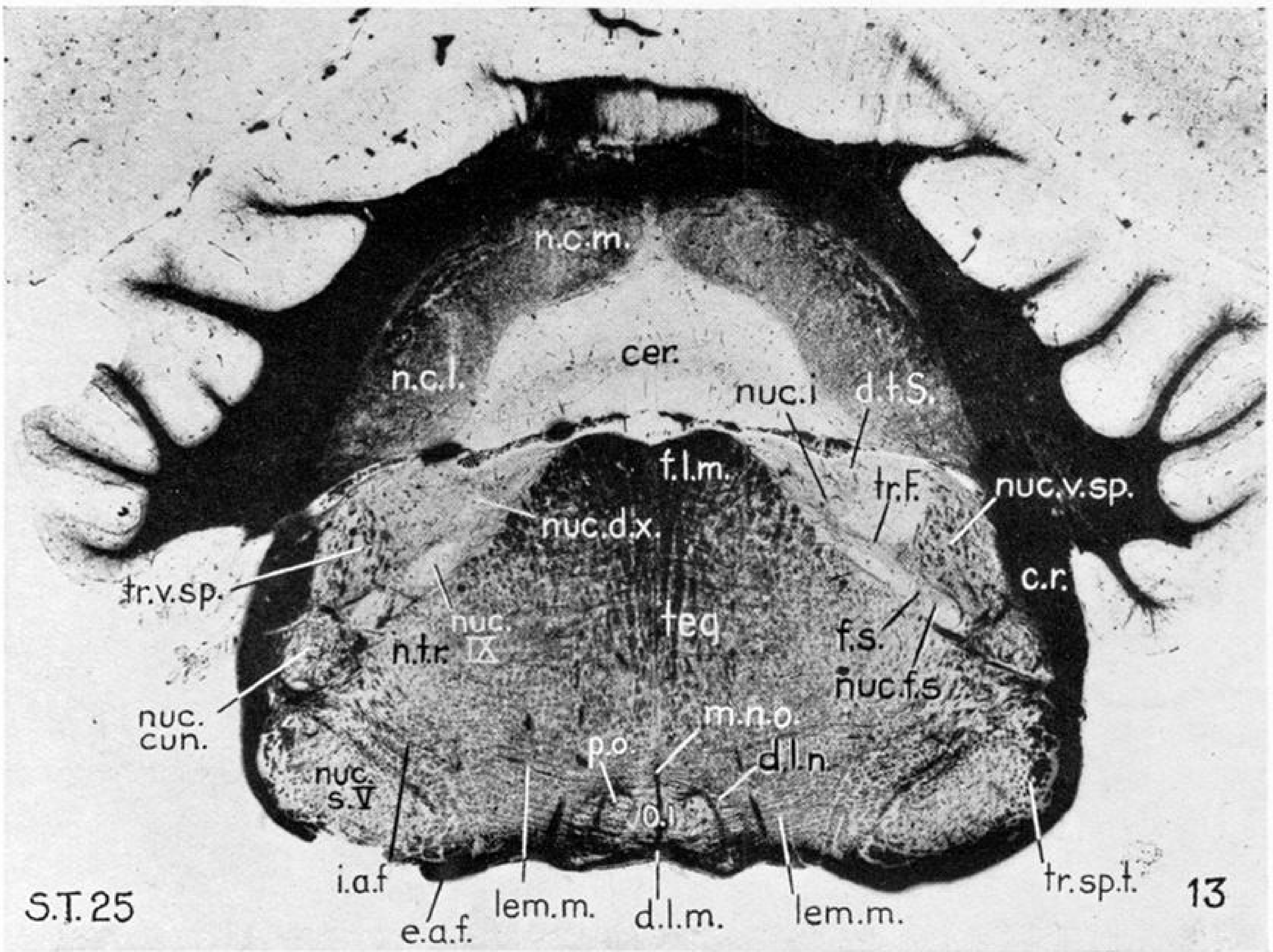

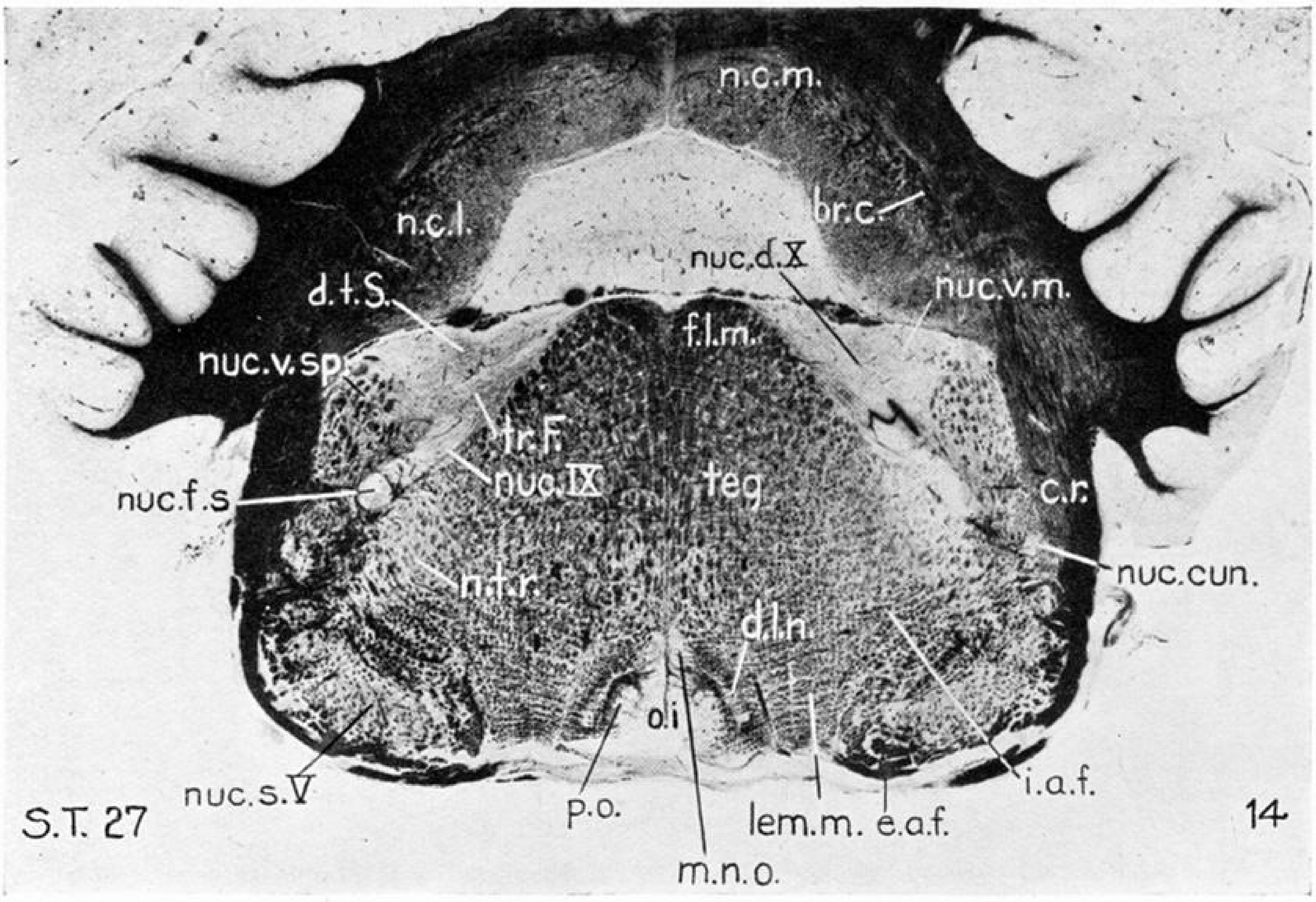

PLATE 45.

FIGS. 12 to 31 *b*.—These figures are photographs at various levels of the transverse Weigert series belonging to Prof. ELLIOT SMITH. × 6.

FIG. 12.—Through the level of the nucleus of the tenth and twelfth motor nerves, the nucleus gracillis and the inferior olive.

FIG. 13.—At the level of the rostral part of the eighth nerve, showing also the sensory nucleus of the fifth, the inferior olive, the medial, lateral and spinal nuclei of the vestibular system, the nucleus cuneatus and the lateral nucleus of the cerebellum.

FIG. 14.—Through the radix and nucleus of the facial nerve, showing the dorsal and ventral cochlear nuclei, the lateral lemniscus and the superior olive.

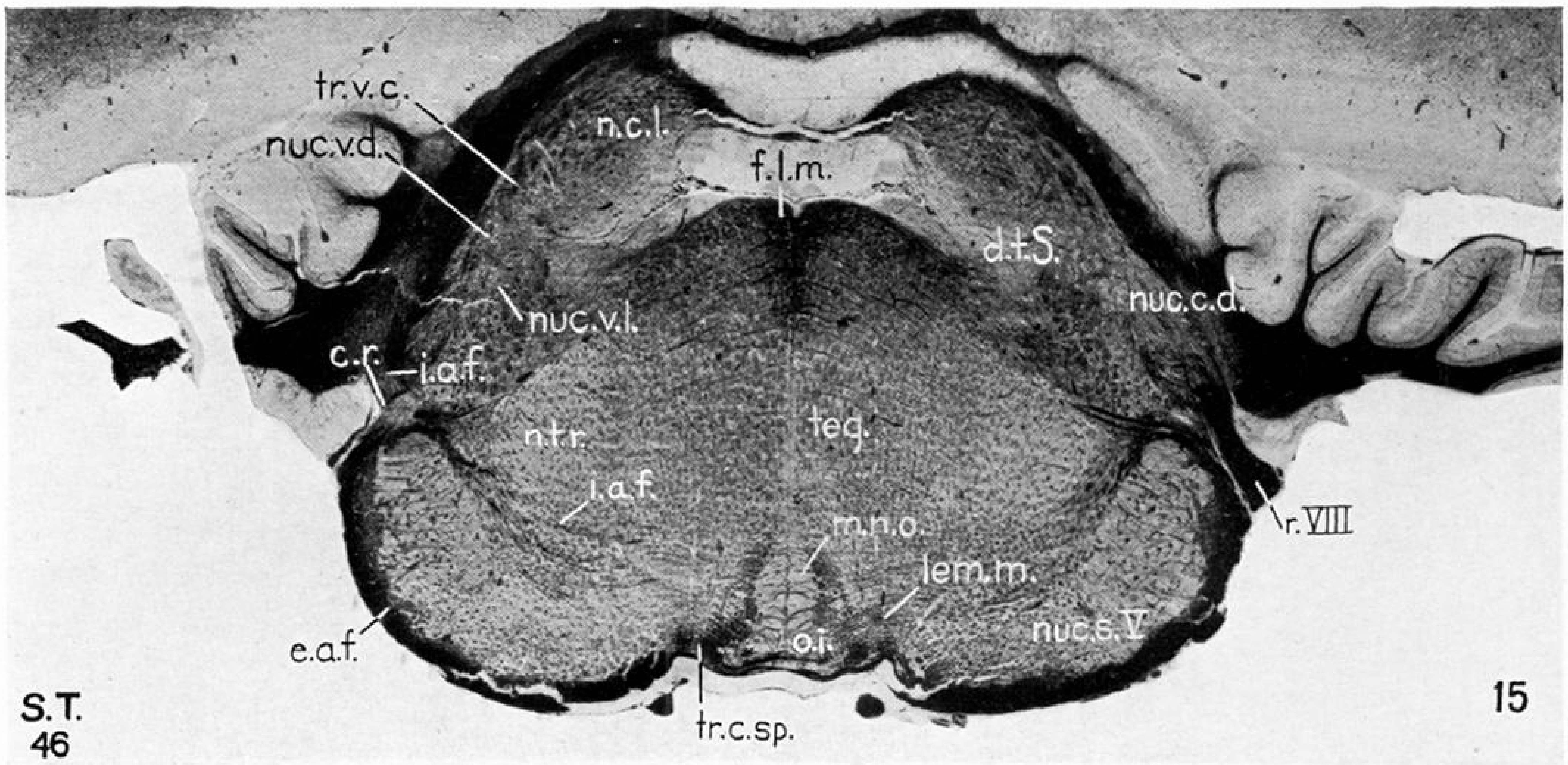

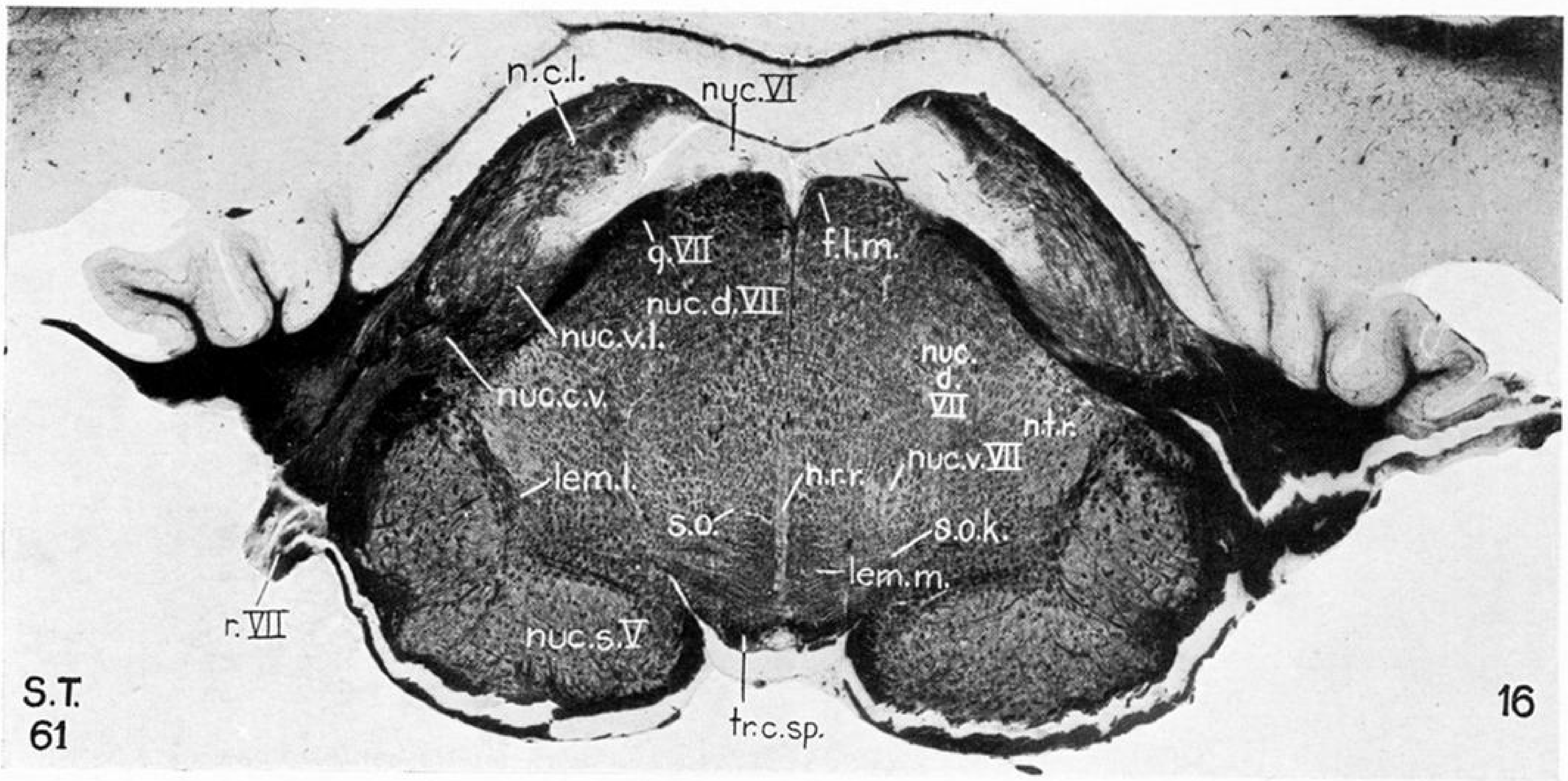

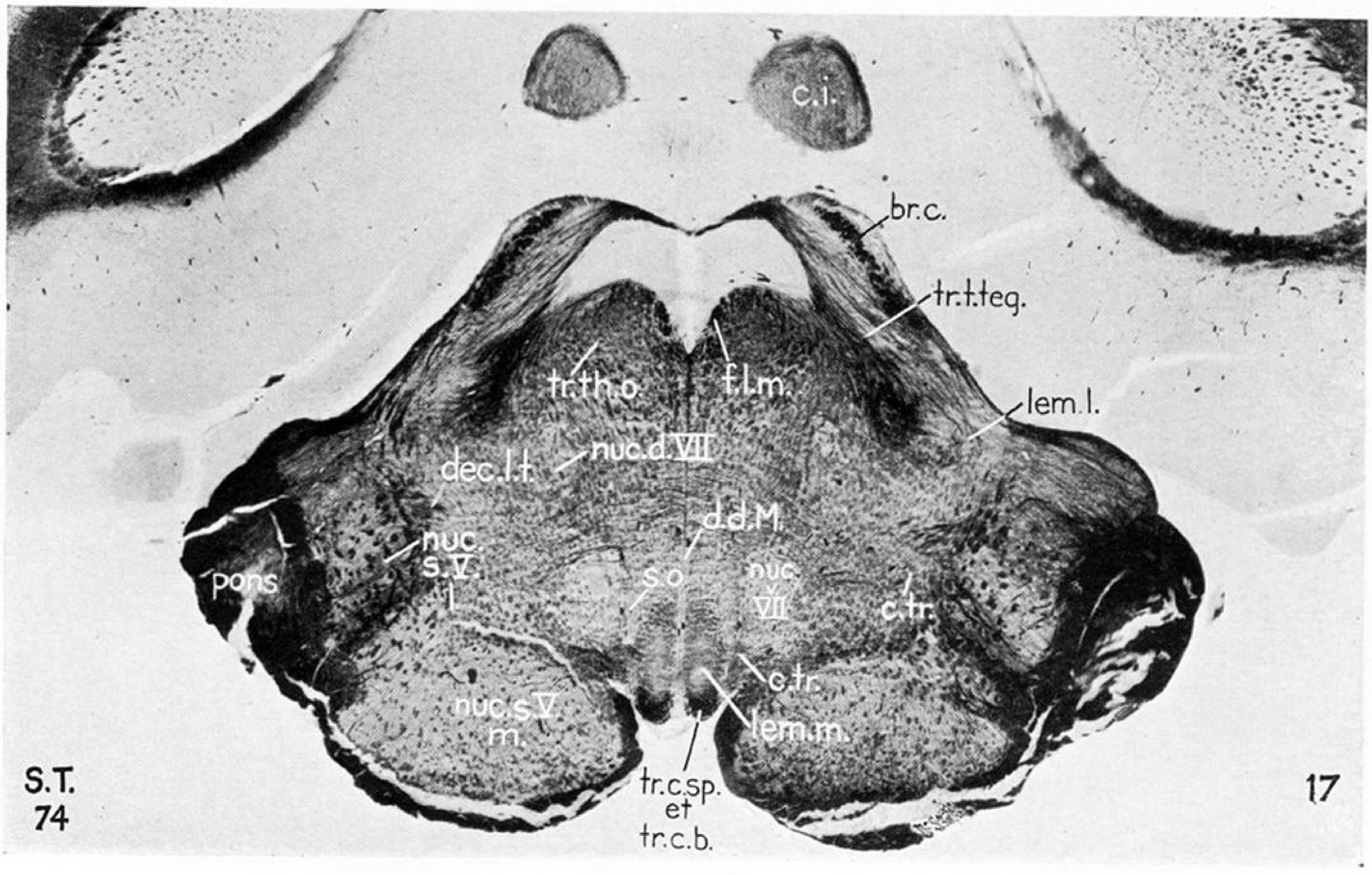

PLATE 46.

FIG. 15.—Through the dorsal motor nucleus of the tenth, the nucleus of the fasciculus solitarius, the lateral and medial cerebellar nuclei and the nucleus cuneatus.

FIG. 16.—This level is slightly cephalward of the preceding figure showing the dorsal motor nucleus of the vagus, the spinal nucleus of the vestibular group and many internal arcuate fibres.

FIG. 17.—Through the level of the superior olive, the trapezoid body, the sensory nucleus of the trigeminus, the brachium conjunctivum and the inferior colliculus.

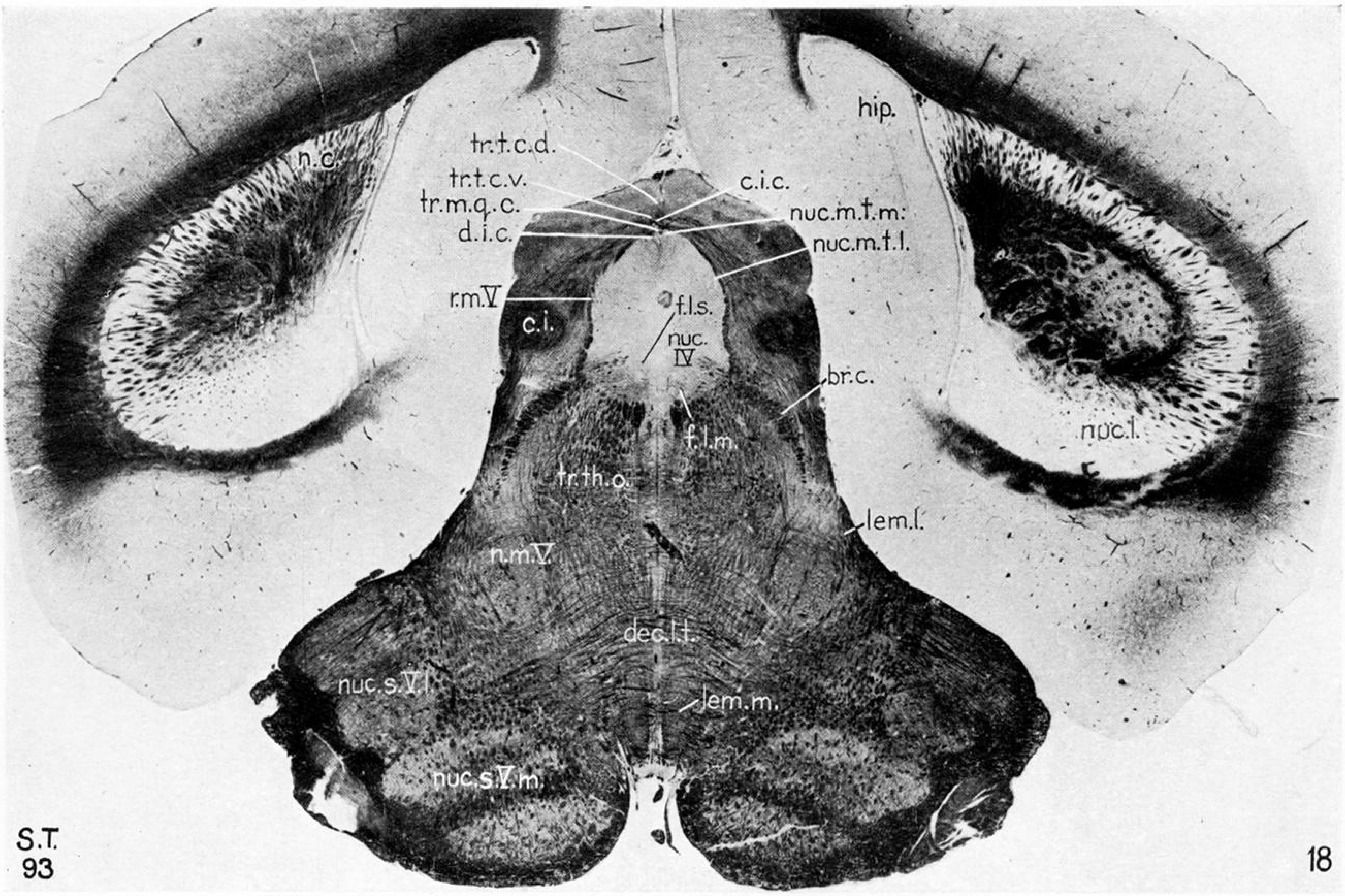

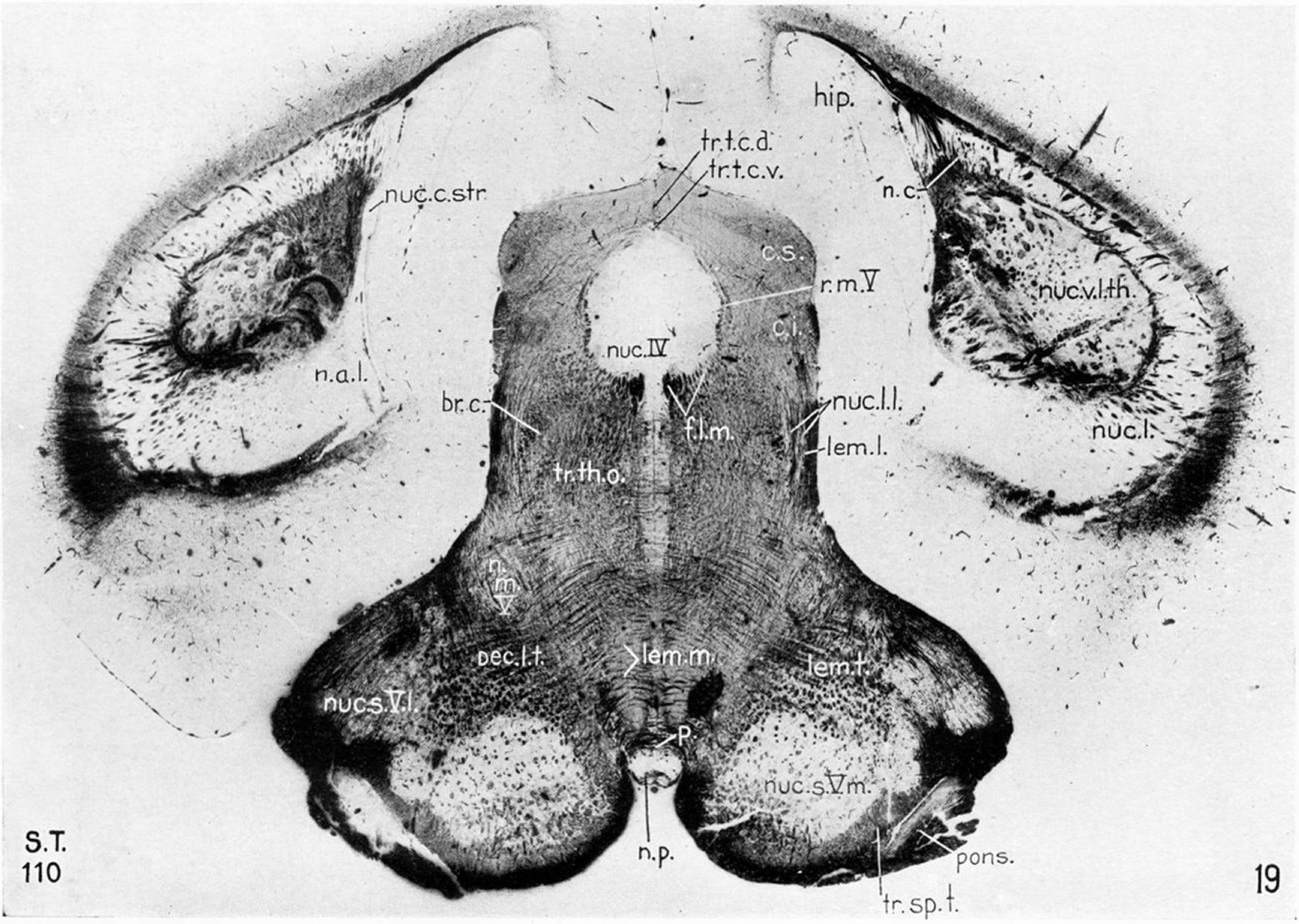

PLATE 47.

FIG. 18.—Through both colliculi, the motor nucleus of the fifth nerve and the pons, showing the basal amygdaloid nucleus and the hippocampus.

FIG. 19.—This section passes through the caudal portion of both colliculi and the largest part of the sensory fifth nucleus. It shows also the nucleus of the stria terminalis, the hippocampus, the nucleus amygdalæ basalis, the lemnisci medialis, lateralis, et trigeminus and the brachium conjunctivum.

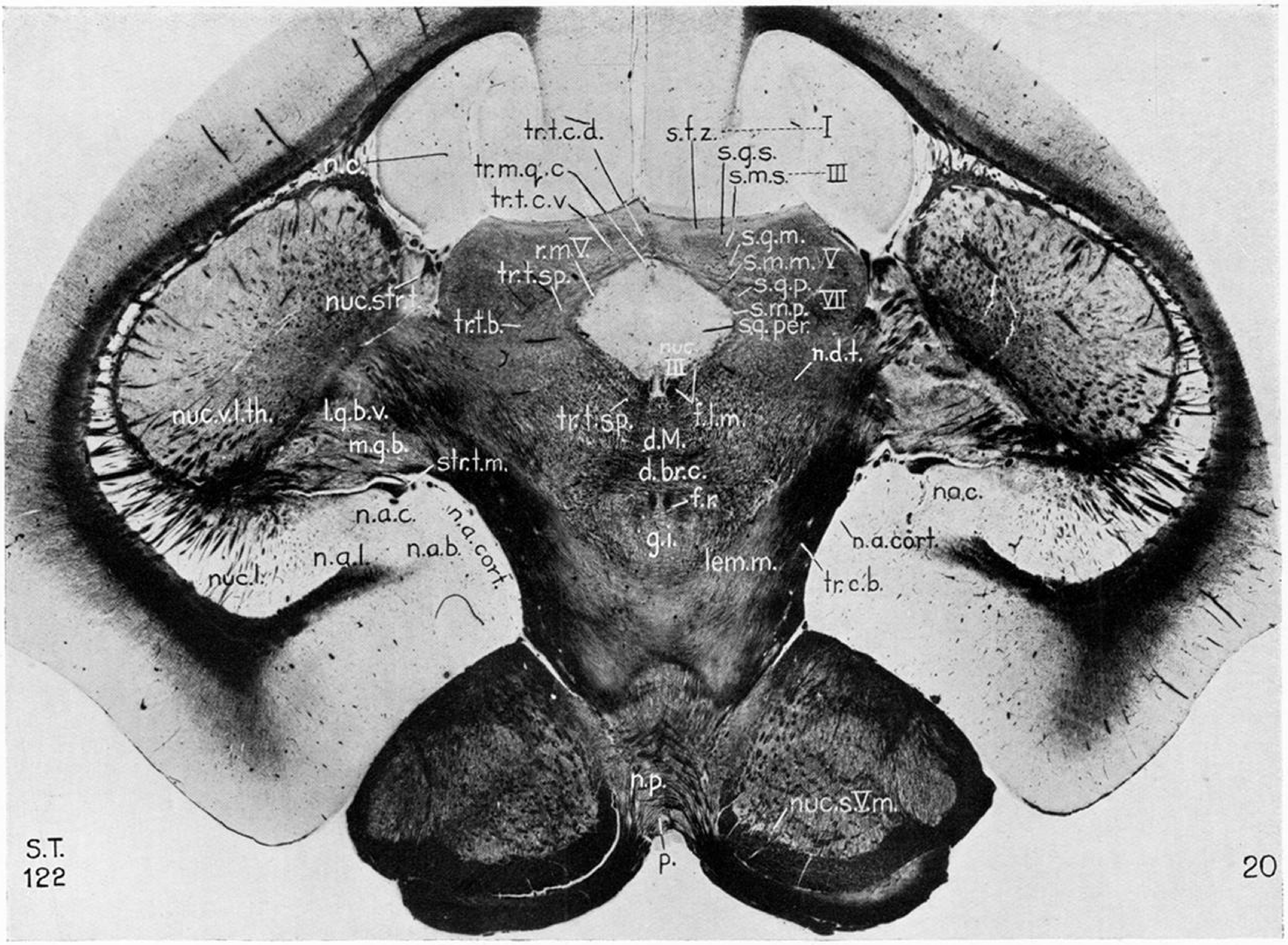

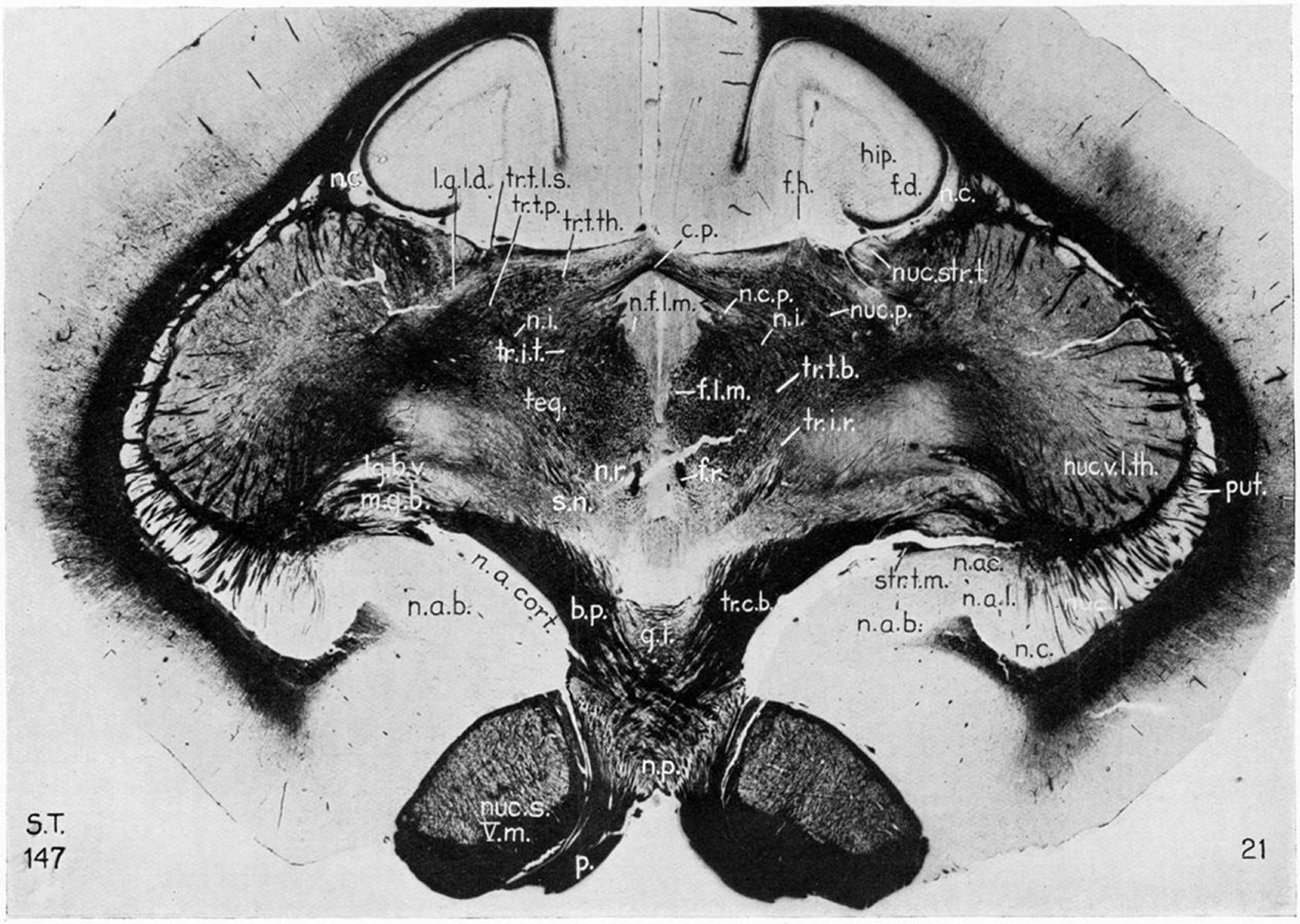

PLATE 48.

FIG. 20.—Through the superior colliculus, the ganglion interpedunculare, the nuclei of the pons and the pes pedunculi. It shows the stria terminalis cut in two places, the lateral geniculate body and the nuclei of the stria terminalis.

FIG. 21.—Through the caudal part of the superior colliculus and the sensory nucleus of the trigeminus, cutting the lateral geniculate body, the lateral nucleus of the thalamus, the lateral and medial nuclei of the amygdaloid complex.

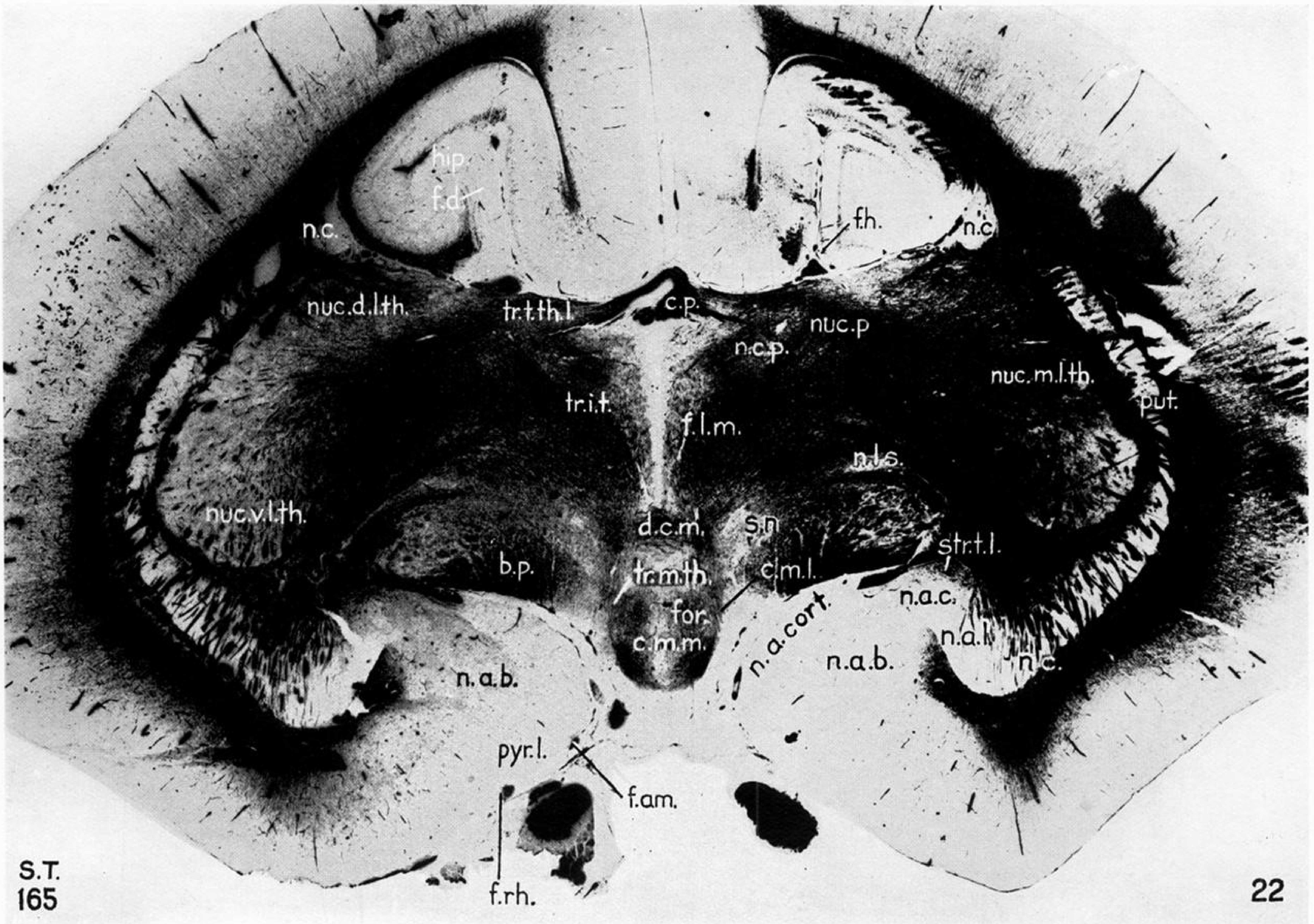

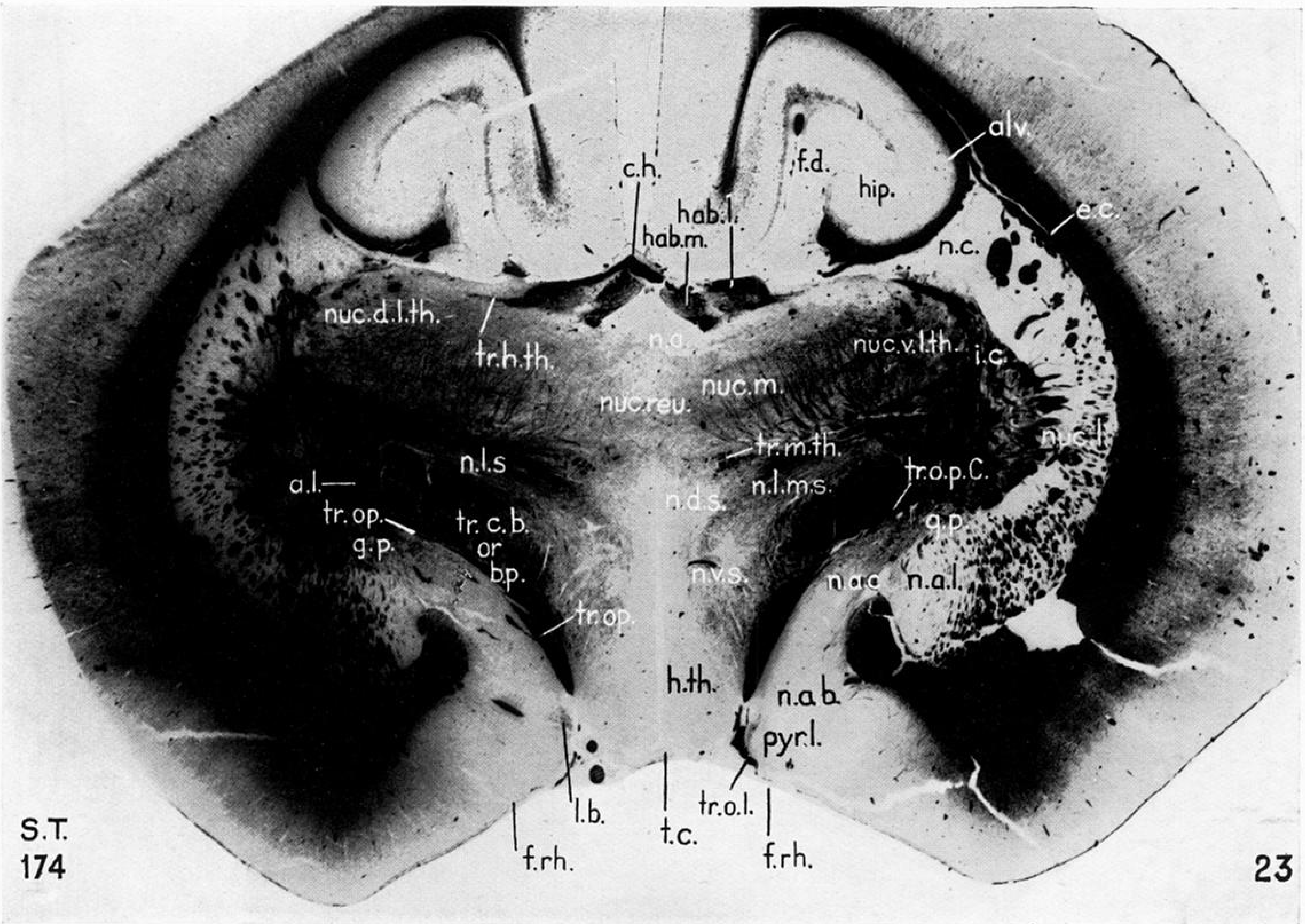

PLATE 49.

FIG. 22.—This section is taken at the level of the commissure superior, the great lateral nucleus of the thalamus, the corpus mamillare and the basal amygdaloid nucleus.

FIG. 23.—Through the level of the habenula, and the hypothalamus showing the optic tract, the nucleus opticus thalami, the medial nucleus, the most anterior portion of the nucleus lateralis, the lateral and anterior nuclei of the amygdaloid complex and the corpus striatum.

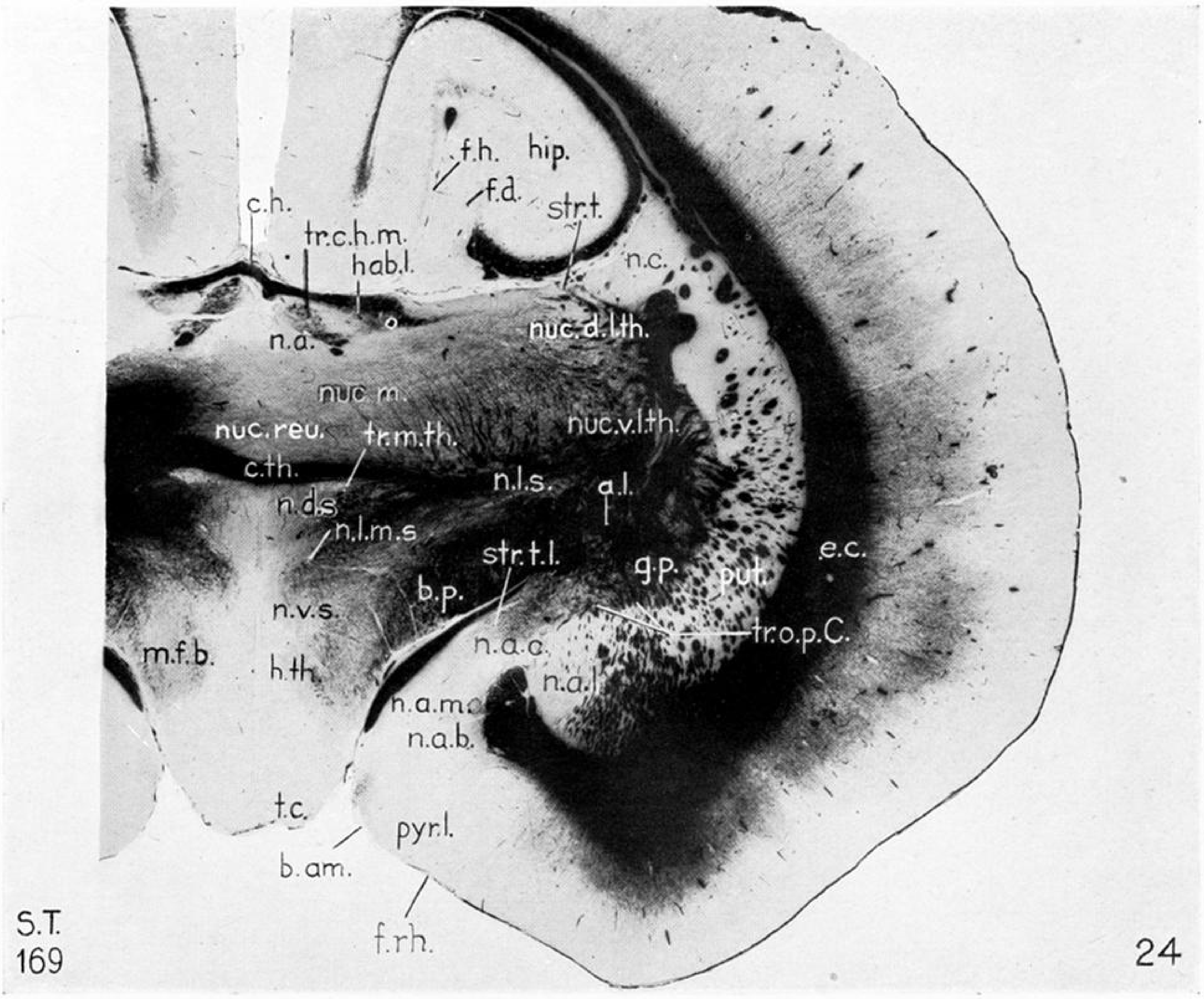

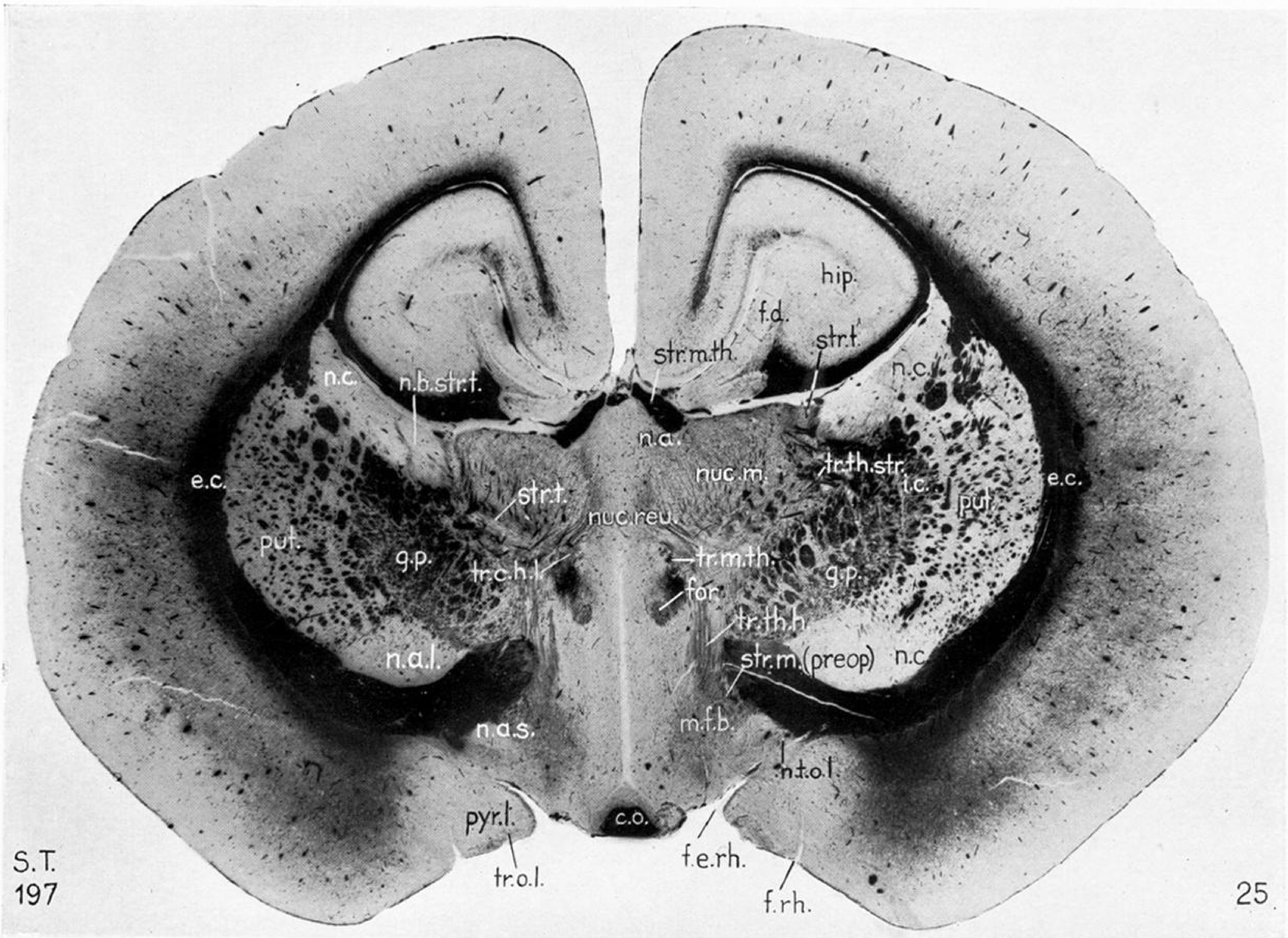

PLATE 50.

FIG. 24.—Through the main body of the thalamic commissure cutting the nuclei anterior and lateral of the amygdala, the nucleus reuniens and the nucleus medialis.

FIG. 25.—Through the stria medullaris thalami, the anterior and medial thalami nuclei, the medial fore-brain bundle, the fornix, the optic chiasma and the major part of the internal capsule fibres.

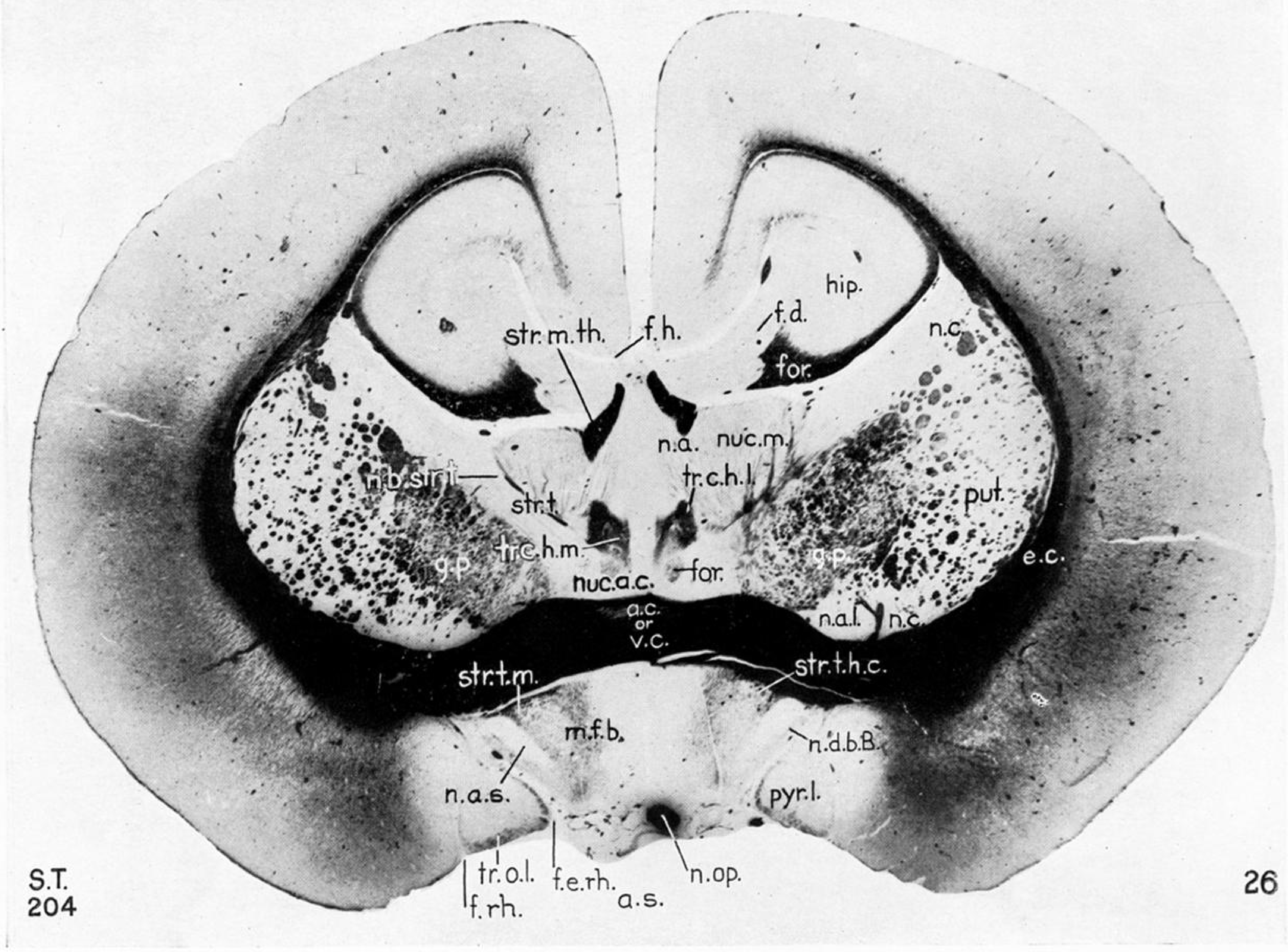

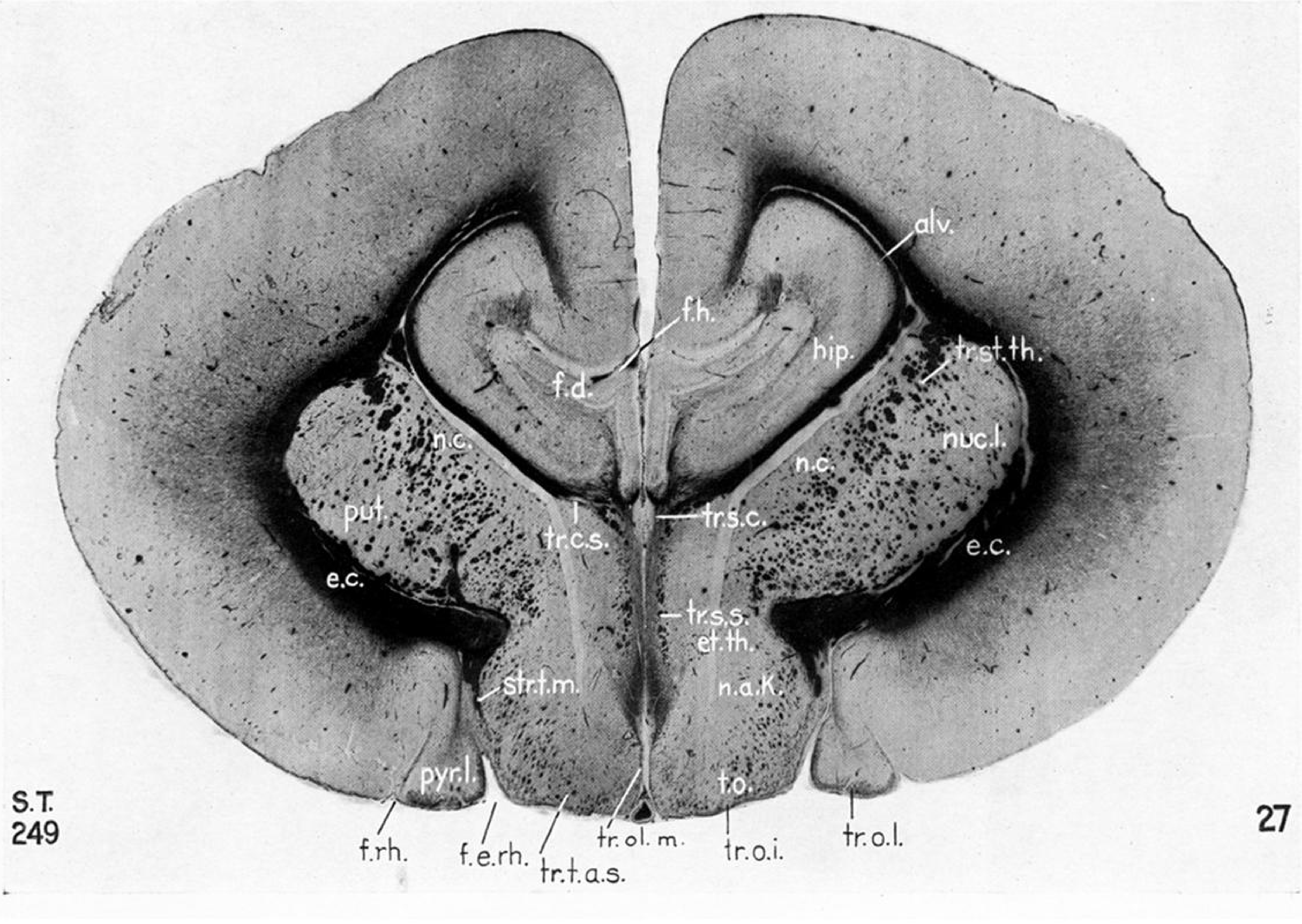

PLATE 51.

FIG. 26.—Section is taken at the level of the main body of the anterior commissure, showing the stria terminalis, the caudate-lentiform complex, the lateral olfactory nucleus and the pyriform lobe.

FIG. 27.—Through the region of the septum cephalward to the anterior commissure. The rhinal fissure, the lateral olfactory tract, the hippocampus with the fascia dentata and the anterior part of the corpus striatum are plainly visible.

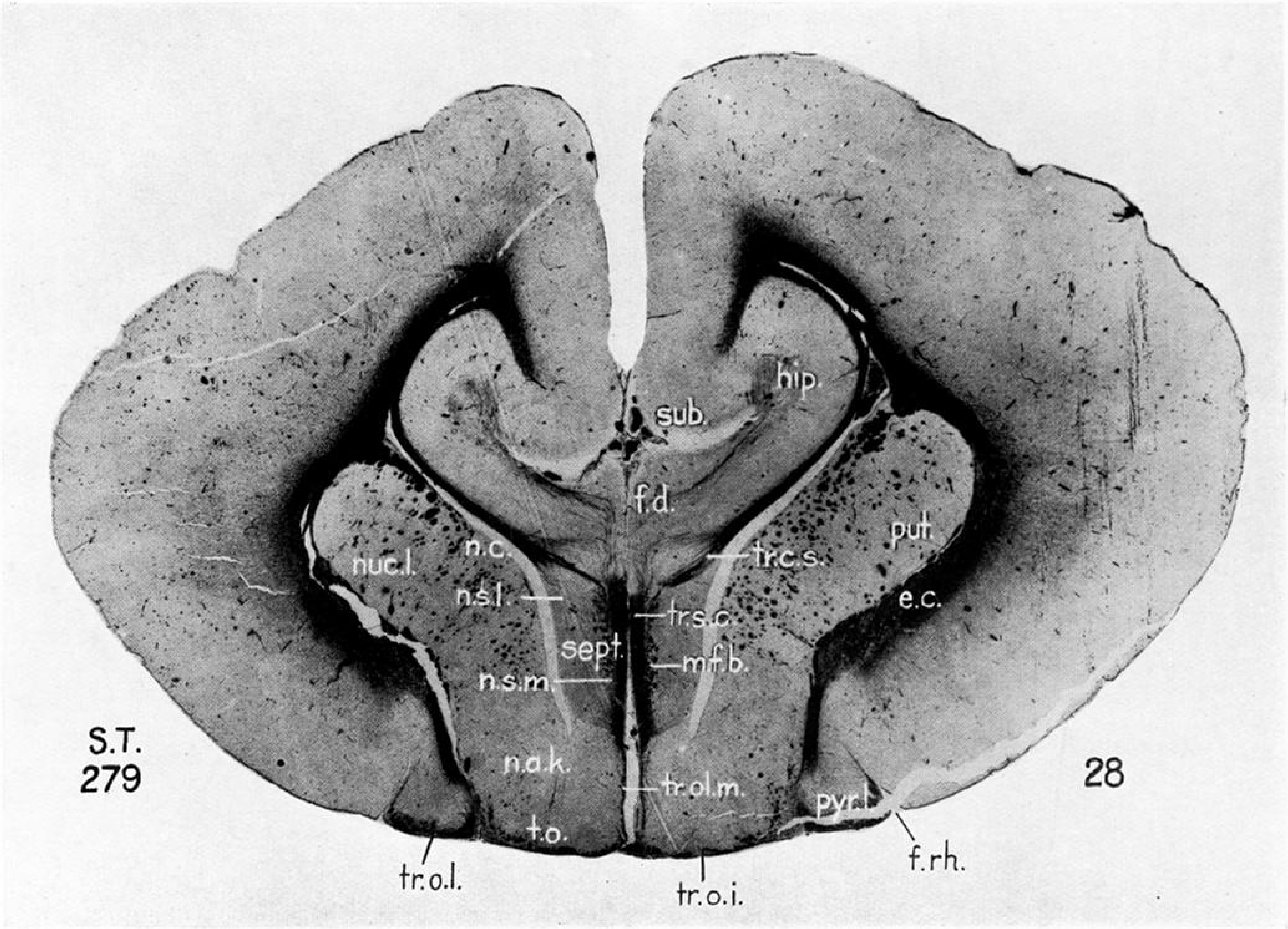

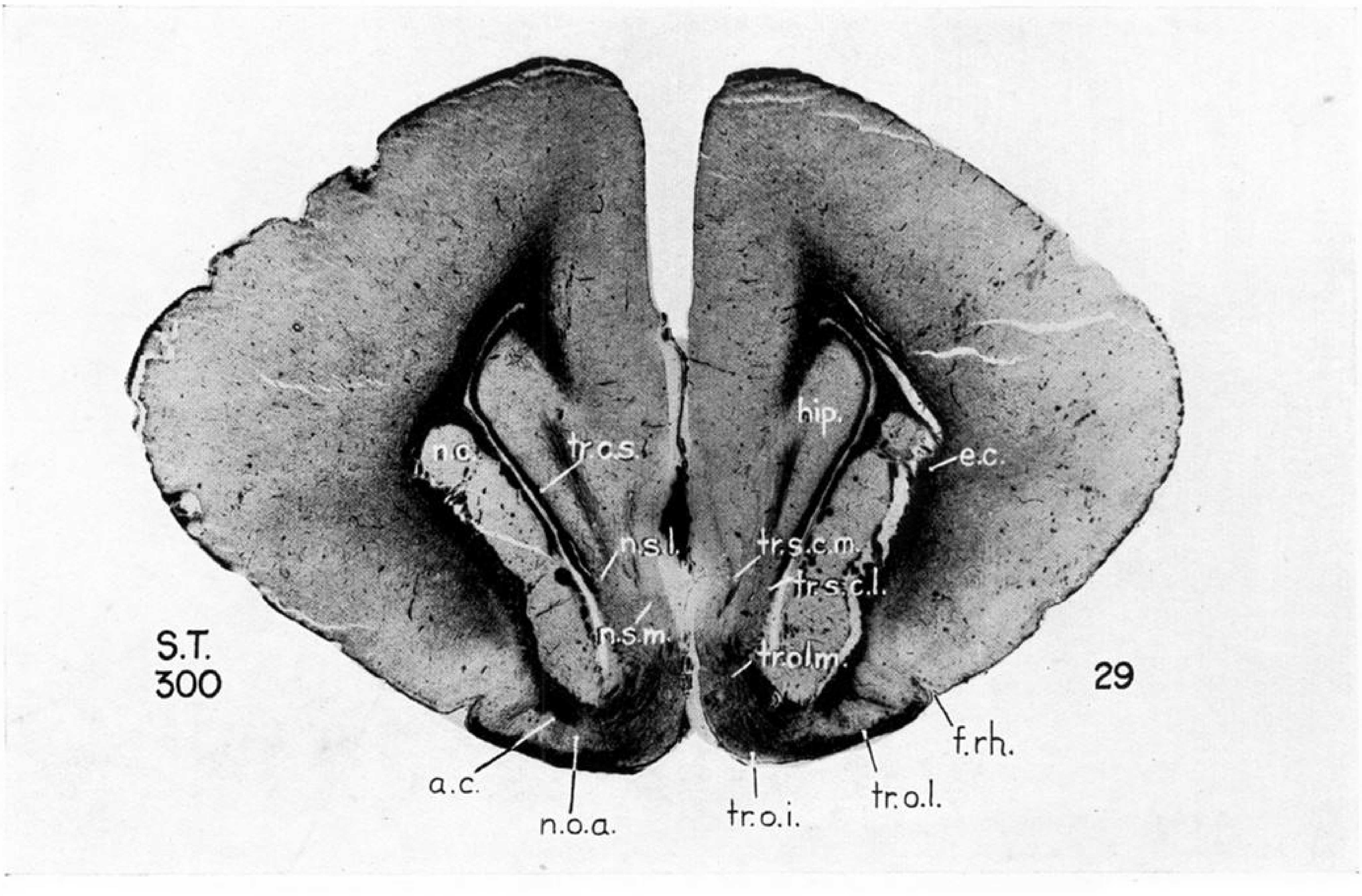

Plate 52.

Fig. 28.—Through the tuberculum olfactorium, the pyriform lobe, the hippocampus, the fascia dentata and the septum.

Fig. 29.—Just anterior to the tuberculum olfactorium through the cephalad part of the corpus striatum.

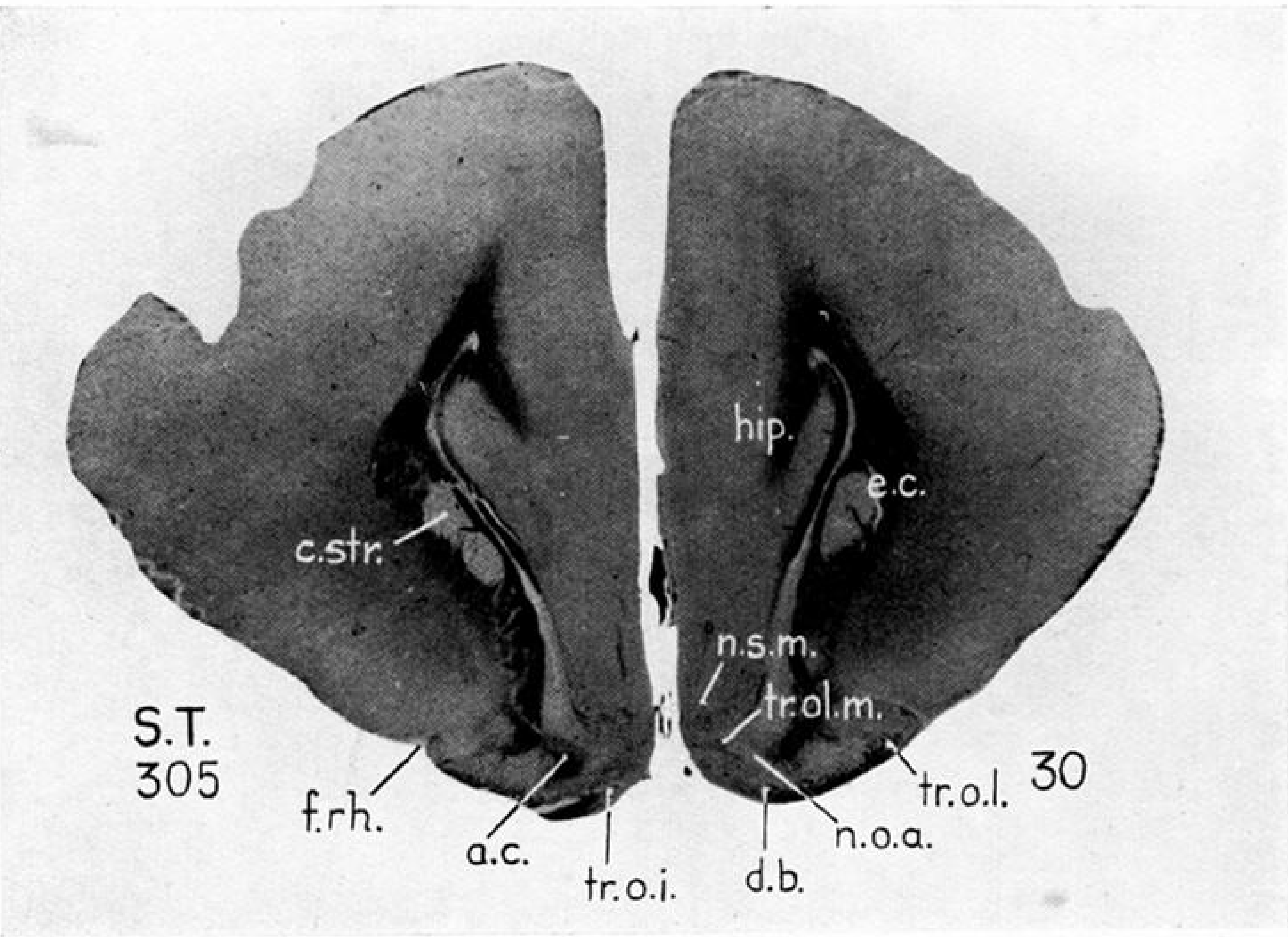

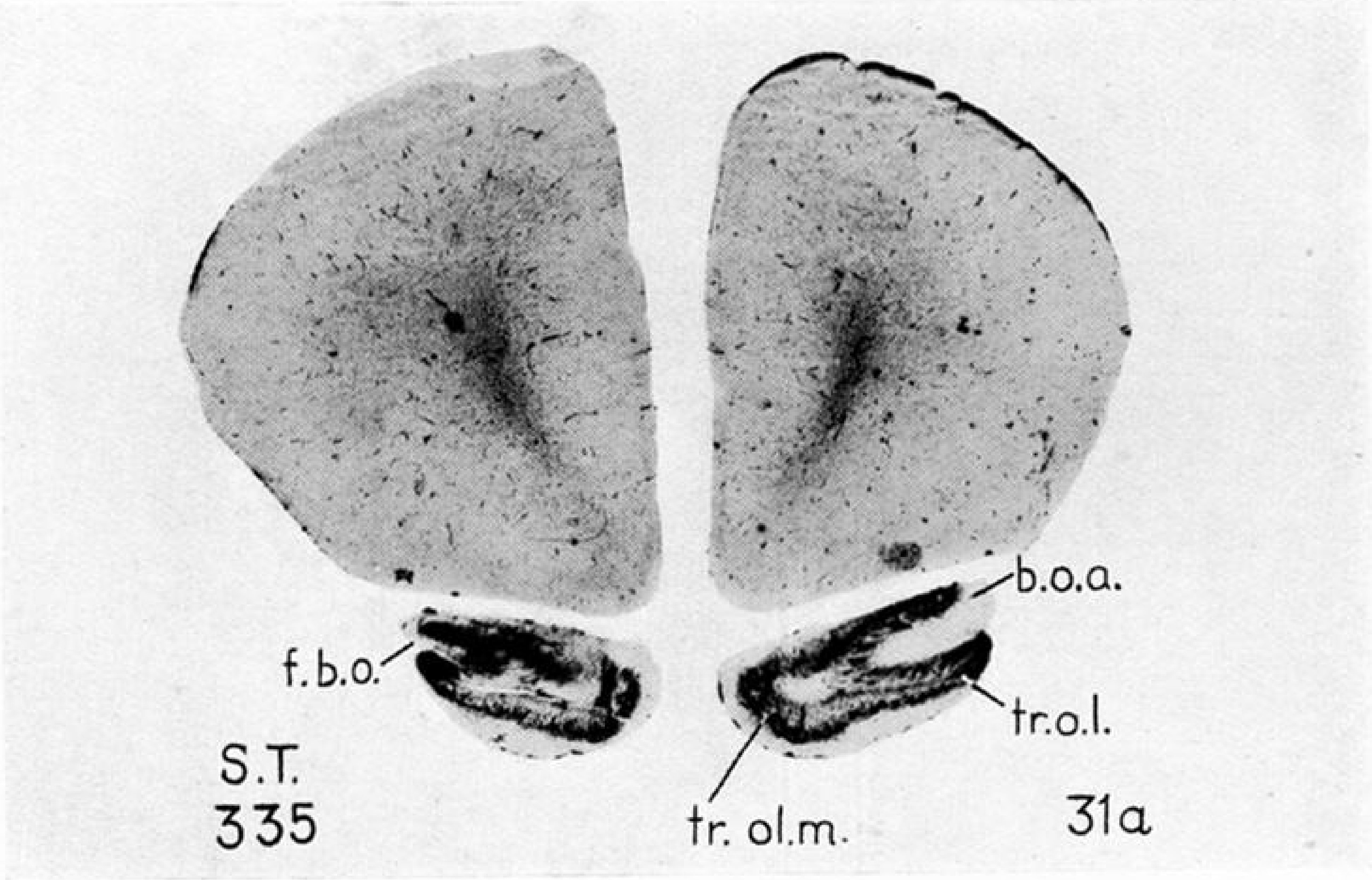

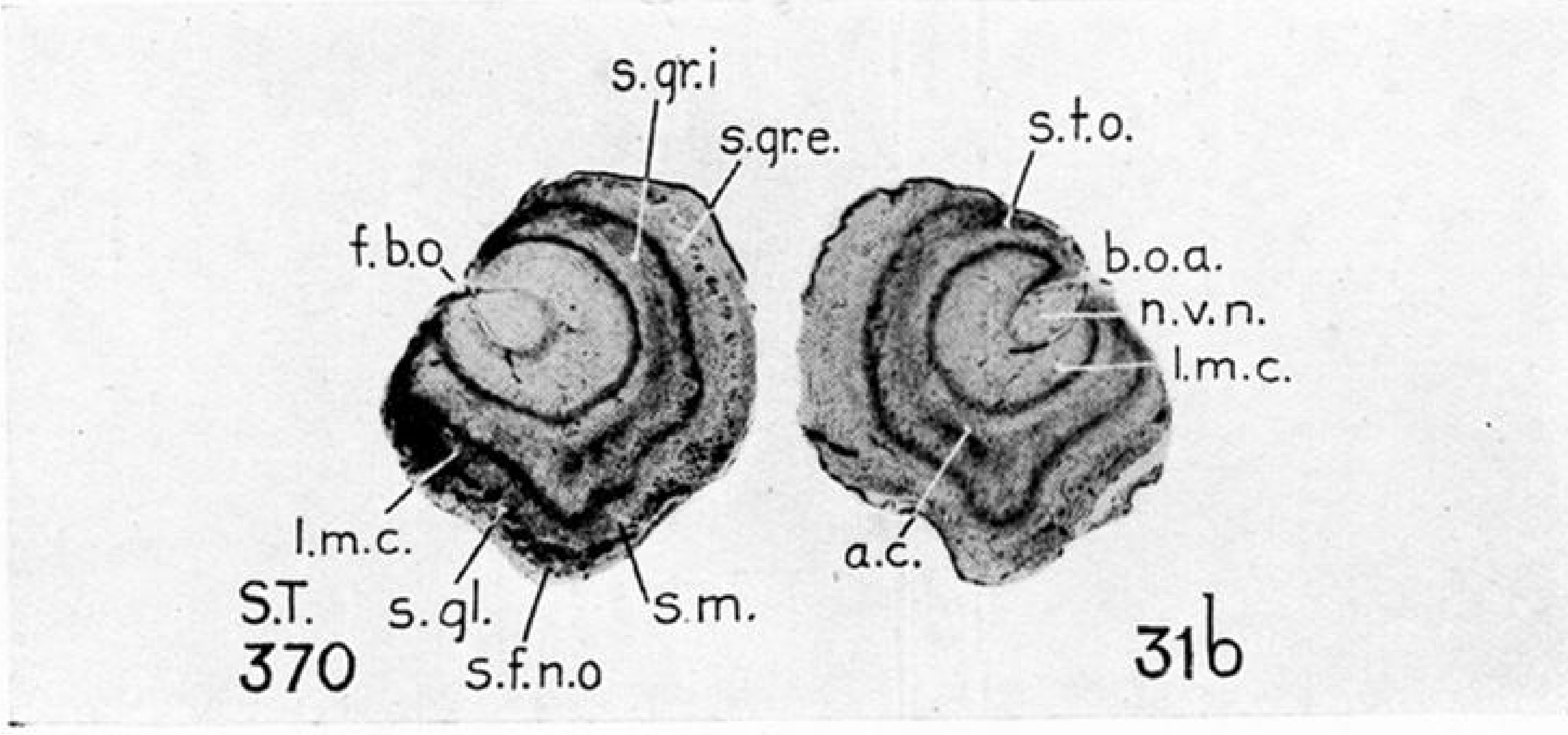

PLATE 53.

FIG. 30.—Through the root of the olfactory bulb, and the nucleus olfactorius anterior.

FIG. 31 (*a*).—Through the posterior part of the bulbus olfactorius. (*b*) Through the middle part of the bulbus olfactorius.

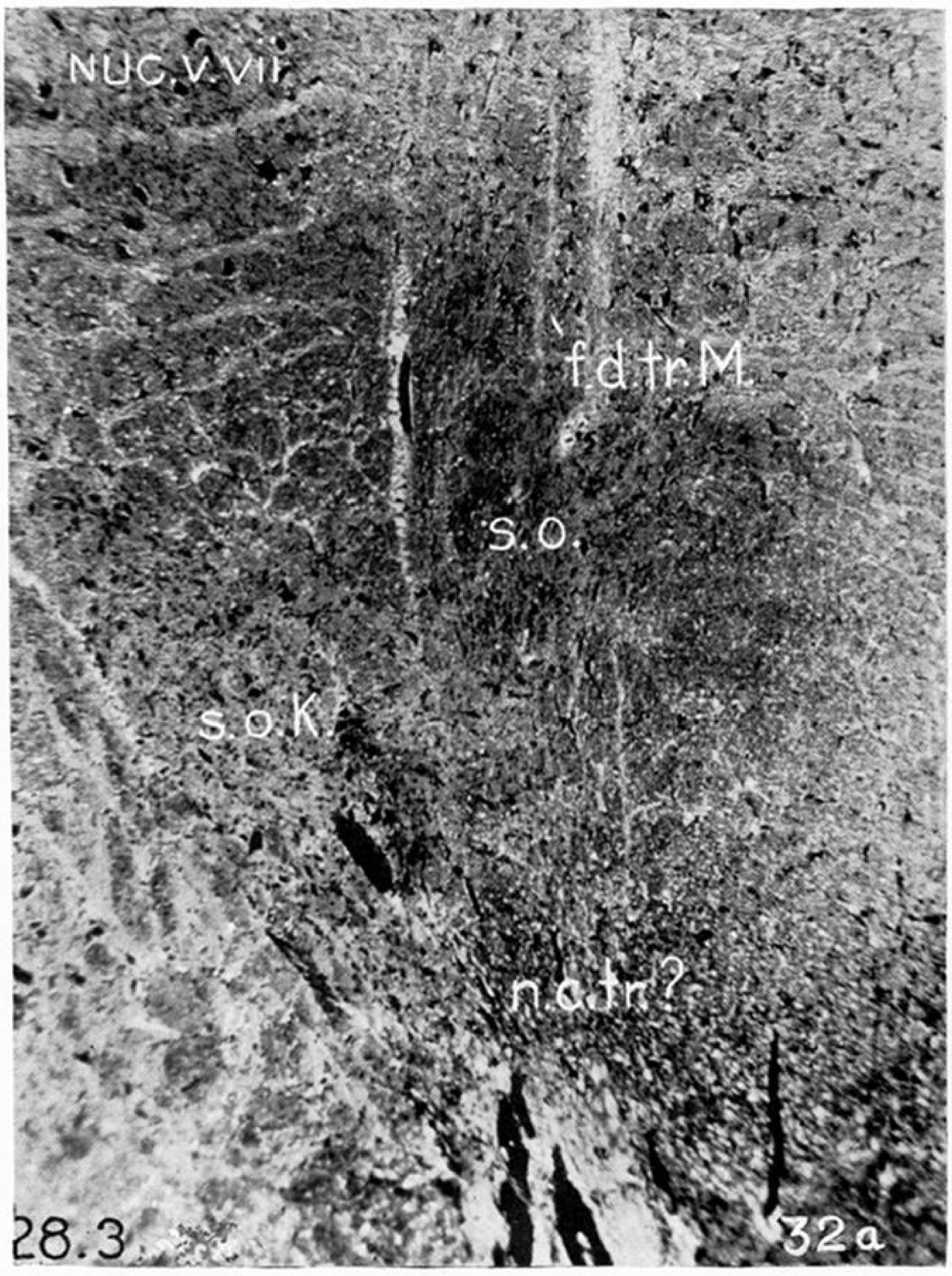

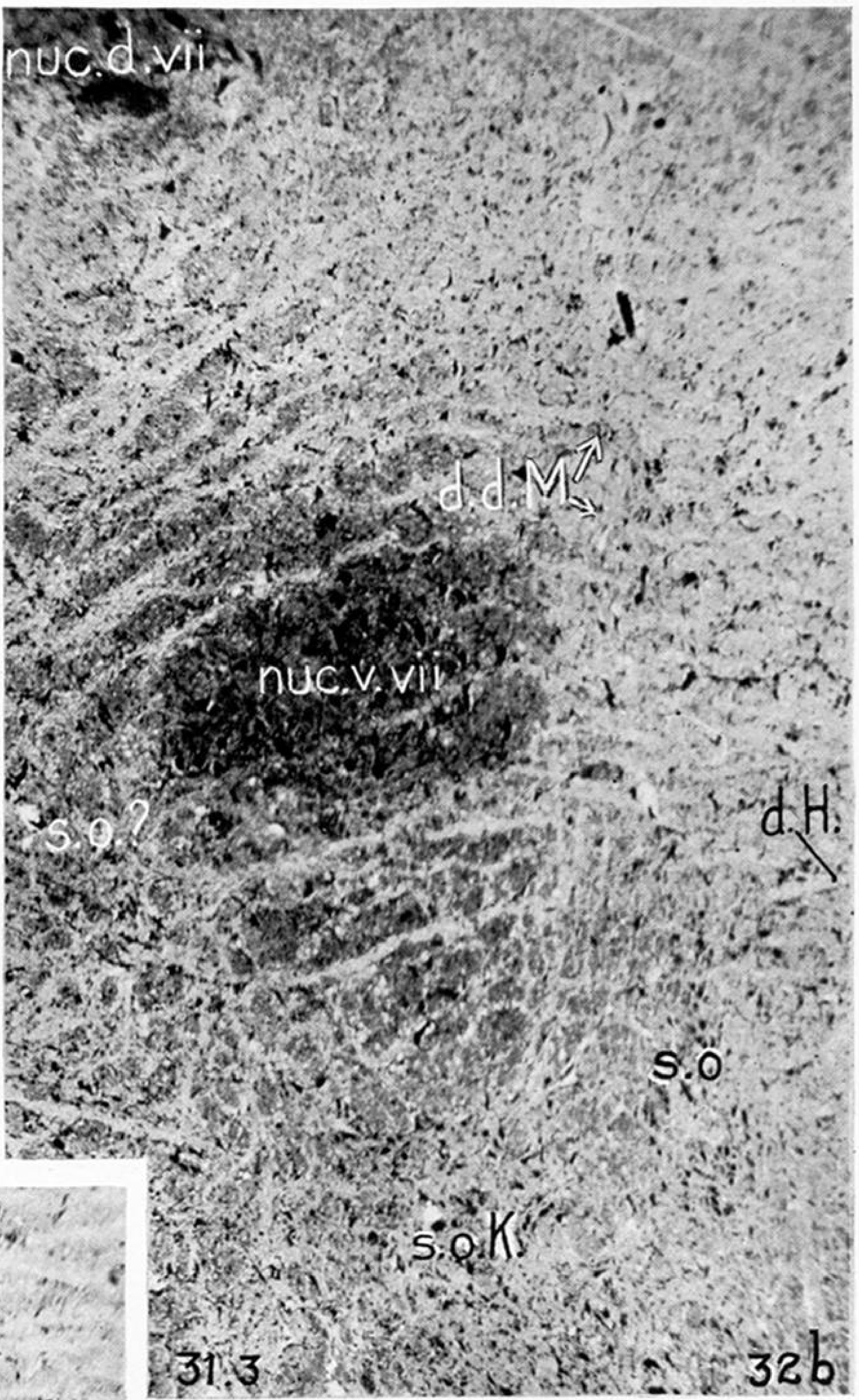

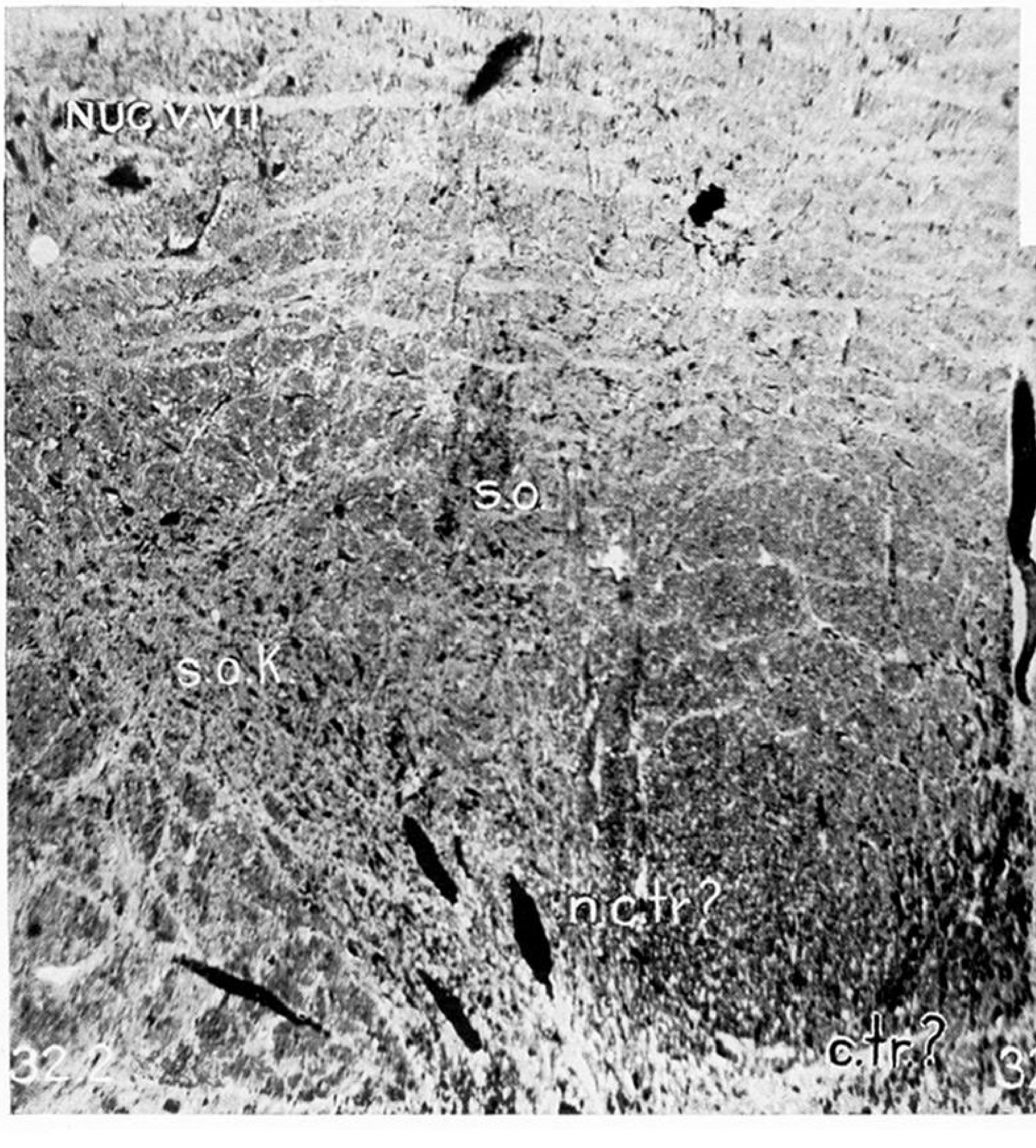

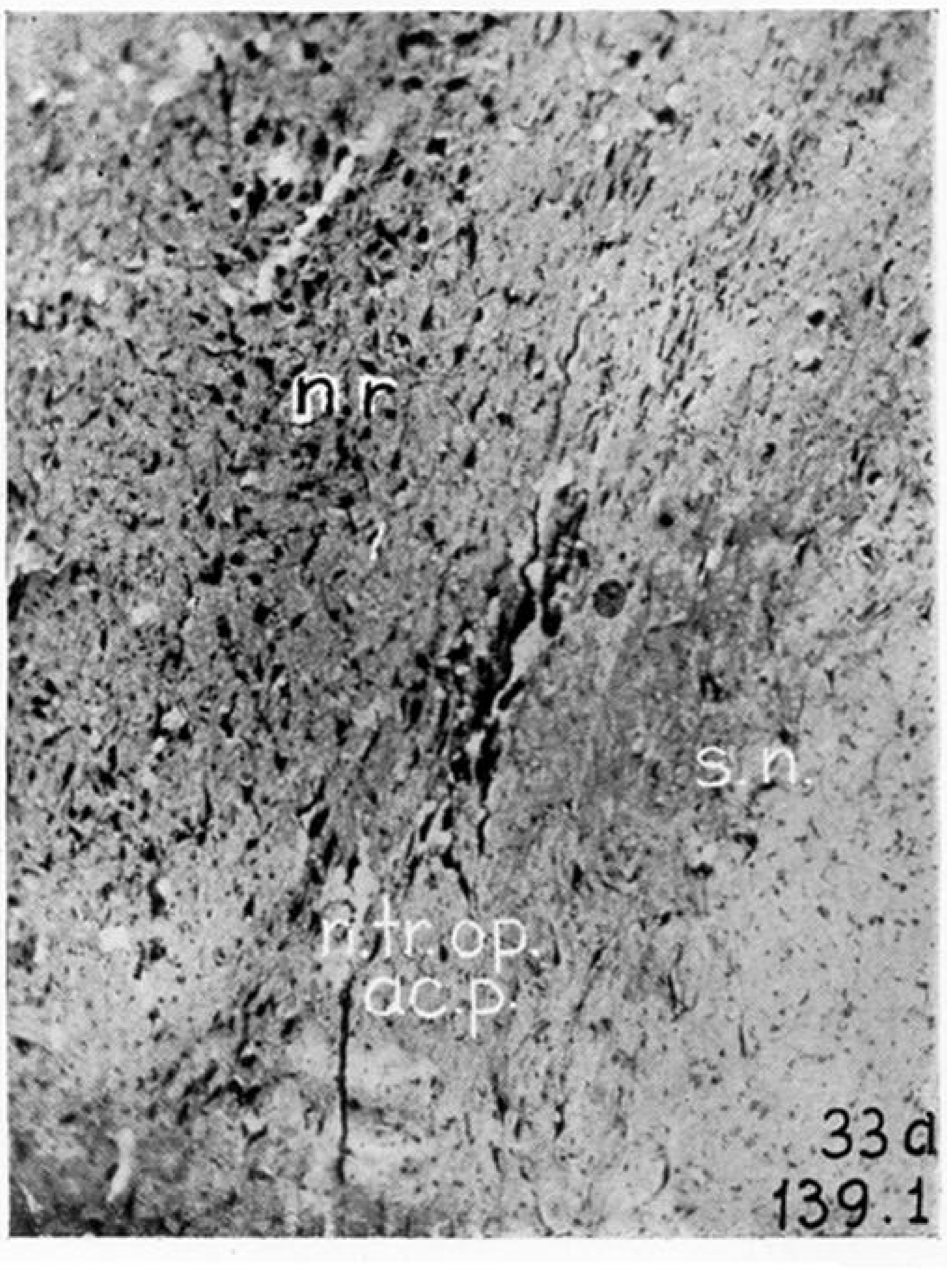

PLATE 54.

FIG. 32 (*a*).—Photomicrograph taken through the ventral nucleus of the facial nerve, showing what the writer thinks to be the superior olive, as well as the direct fibres of the secondary acoustic tract of von Monakow. Bielschowsky series. 28.3. × 46.

FIG. 32 (*b*).—Through the more ventral of the dorsal seventh nuclei, showing the ventral facial nucleus, three possible divisions of the superior olive, and the dorsal (von Monakow) and the intermediate (Held) decussations of the lateral lemniscus. W. T. B. 31.3. × 46.

FIG. 32 (*c*).—Through the ventral nucleus of the seventh nerve, showing two parts of the superior olive, a possible nucleus of the trapezoid body and the trapezoid body. W. T. B. 32.2. × 46.

FIG. 33 (*a*).—Photomicrograph taken through the nucleus ruber and the substantia nigra in the level of the corpus mamillare, showing a possible caudal nucleus of the tractus opticus accessorius posterior. W. T. B. 139.1. × 120.

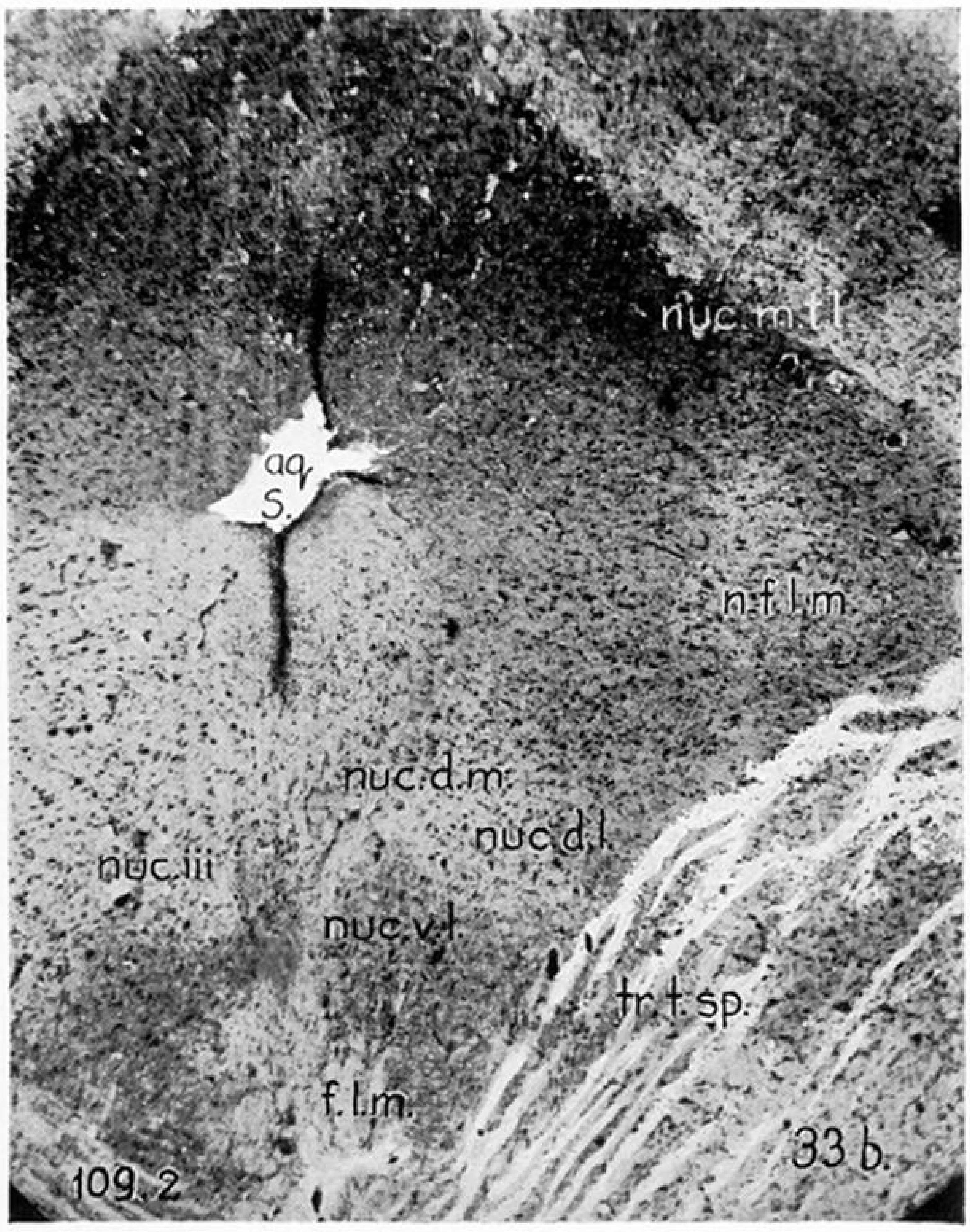

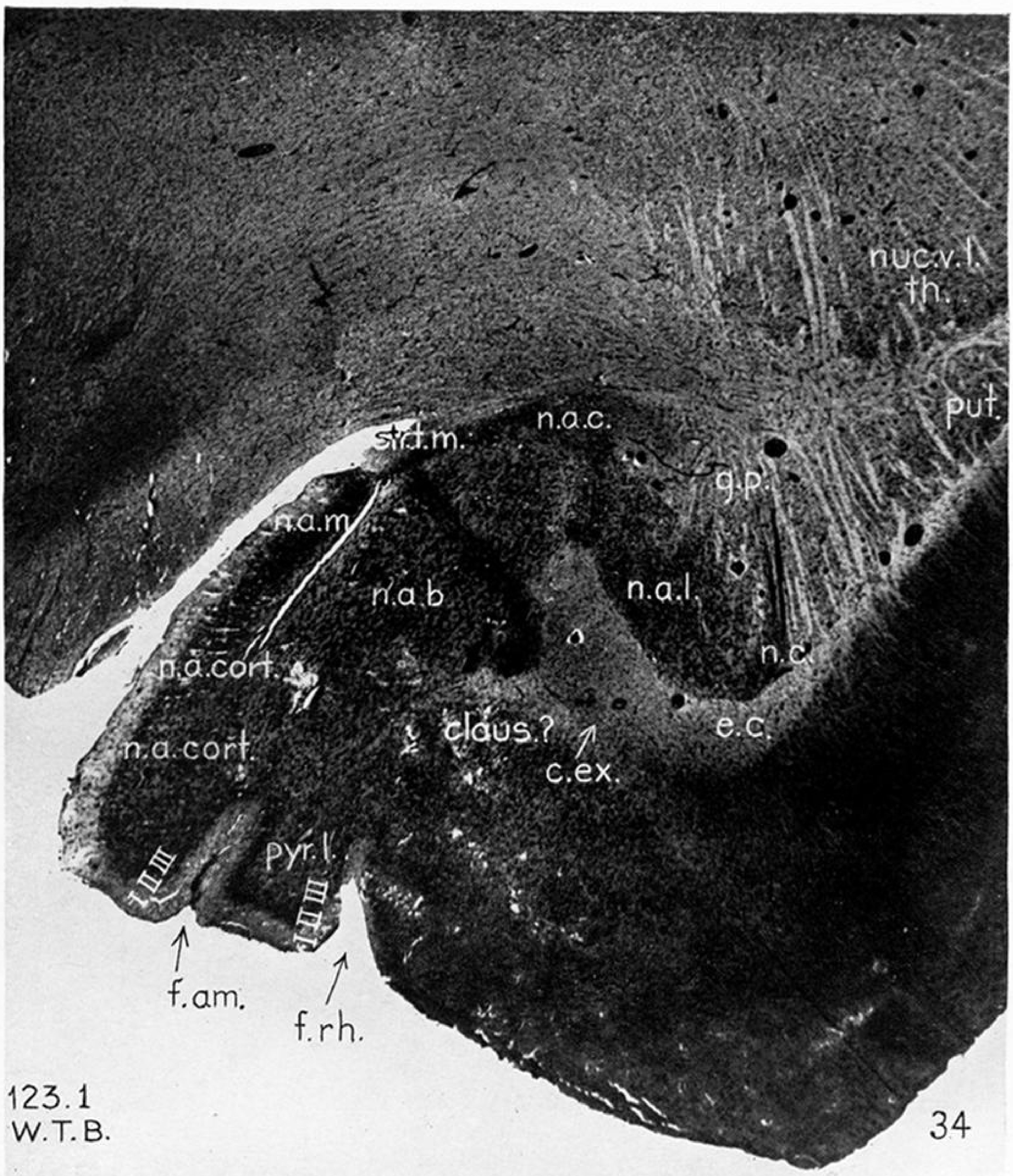

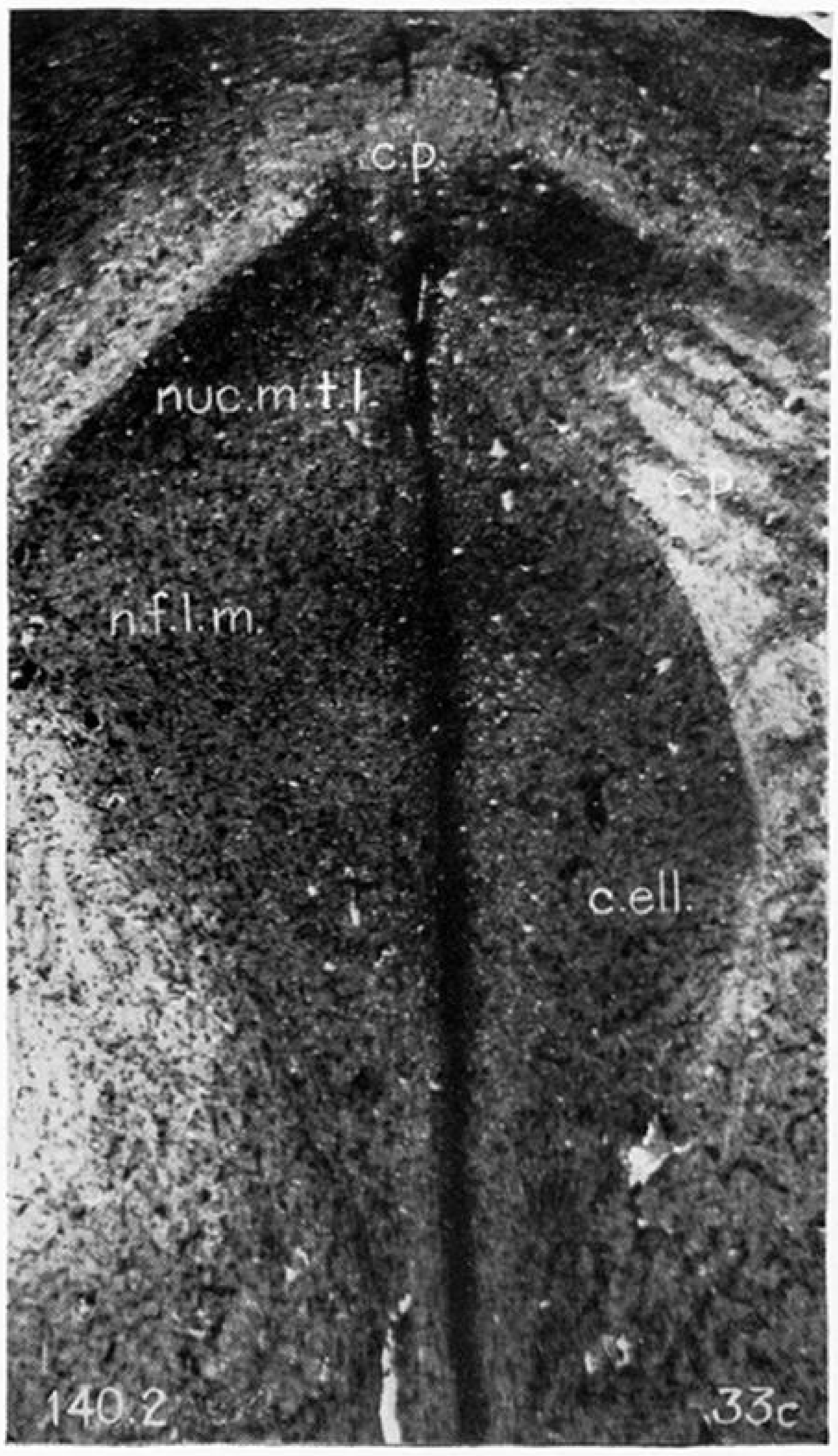

PLATE 55.

FIG. 33 (*b*).—Photomicrograph taken through the midbrain, showing three nuclei of the oculomotor nerve the fasciculus longitudinalis medialis and its nucleus, together with the richly cellular central gray. W. T. B. 109.2. × 32.

FIG. 33 (*c*).—Through the midbrain, showing the more caudal level of the nucleus fasciculus longitudinalis medialis, the two divisions of the commissura posterior, and the corpus ellipticum. W. T. B. 140.2. × 32.

FIG. 33 (*d*).—Through the midbrain, showing the commissura posterior and the corpus ellipticum. W. T. B. 146.3. × 32.

FIG. 34.—Photograph of a section from Prof. WILSON'S Bielschowsky series showing the pyriform lobe and the amygdaloid complex. 123.1. × 12.

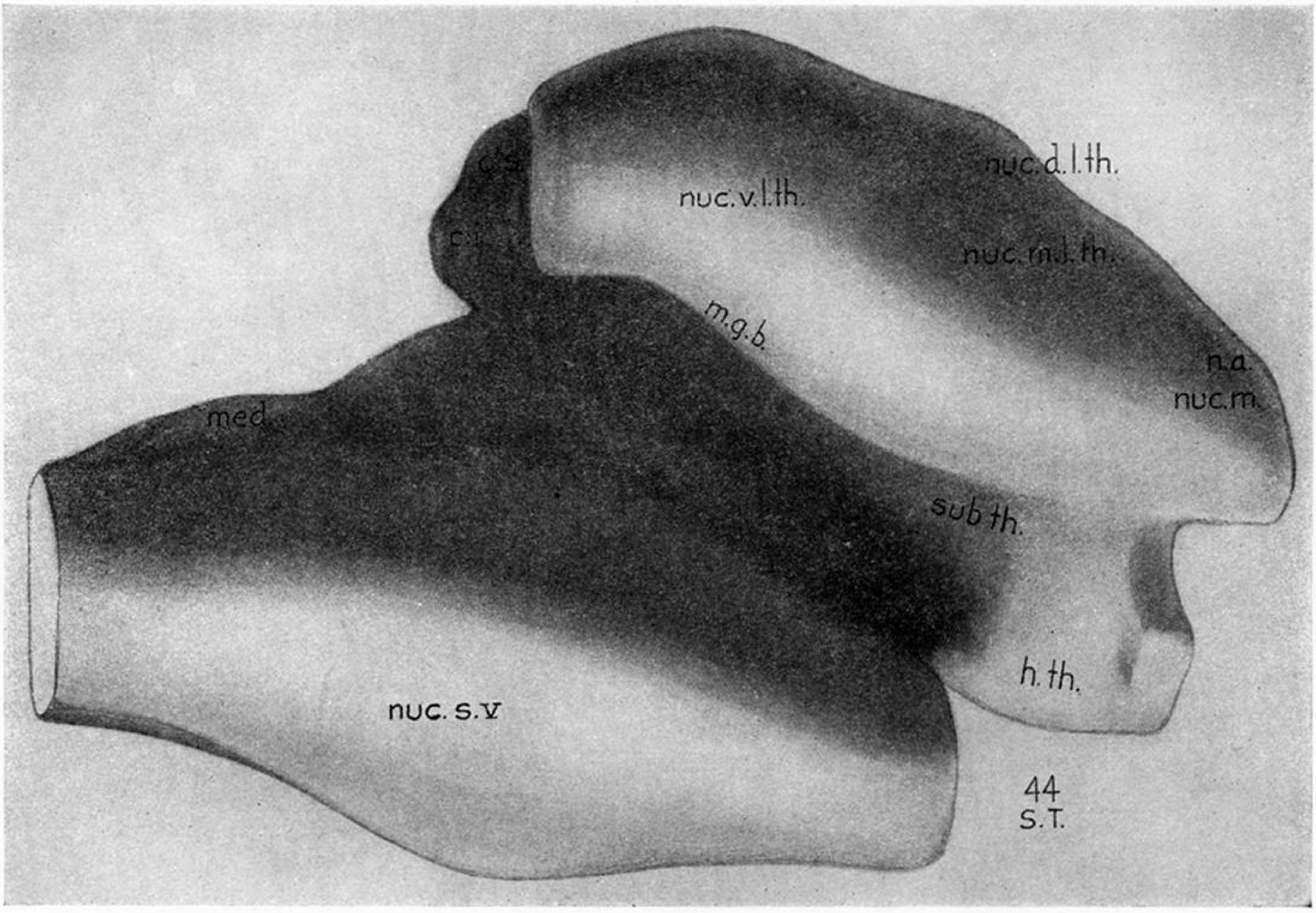

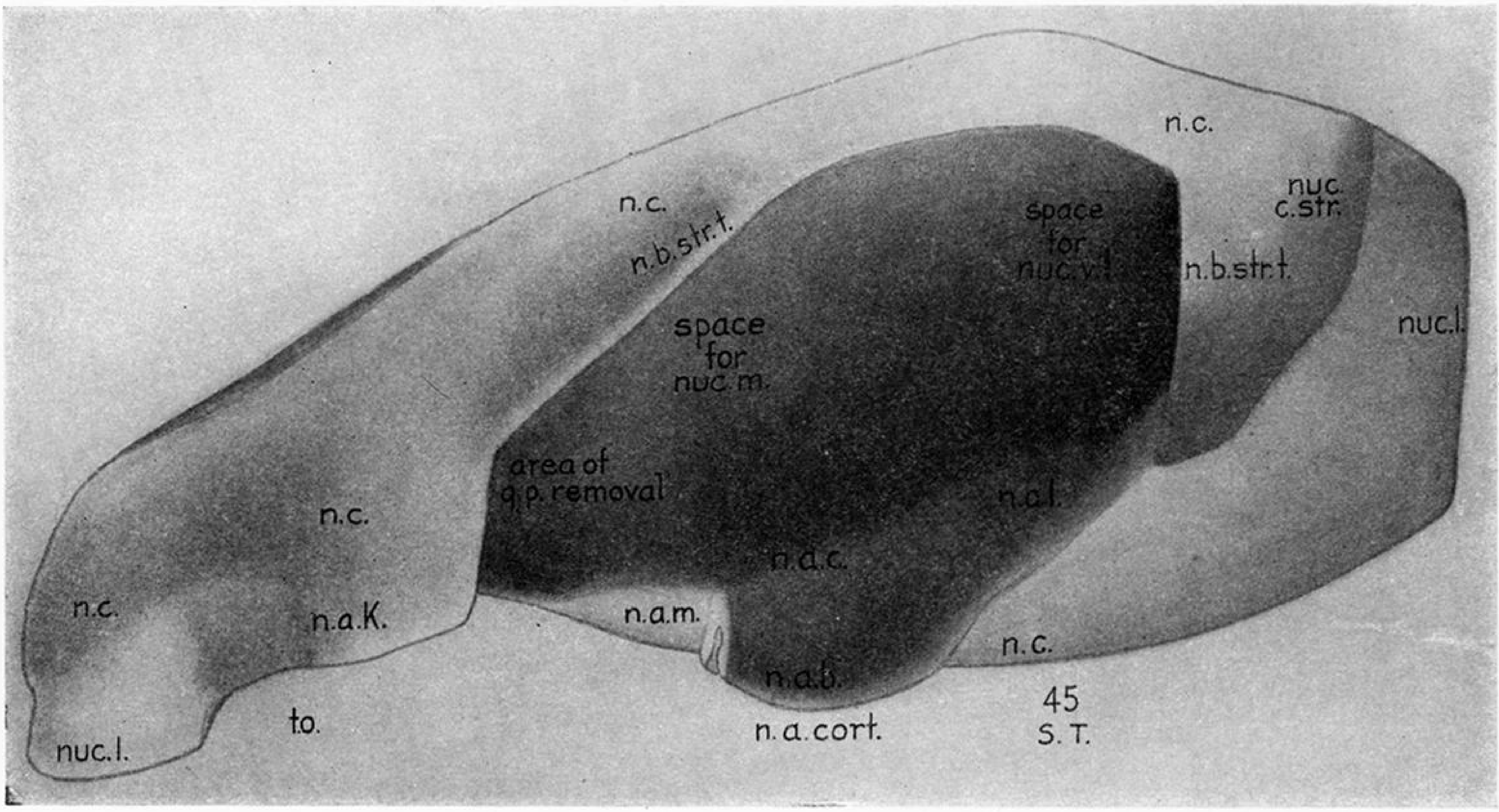

PLATE 59.

FIG. 44.—Wash drawing of the lateral surface of a wax model of the medulla: midbrain and thalamus, after removal of the cerebellum, the corpus striatum and the telencephalon. × 6.

FIG. 45.—Wash drawing of the medial surface of a wax model of the corpus striatum, made by dissecting away the surrounding parts of the model of the whole brain, including the globus pallidus. Made from Prof. ELLIOT SMITH's transverse Weigert series. × 6.